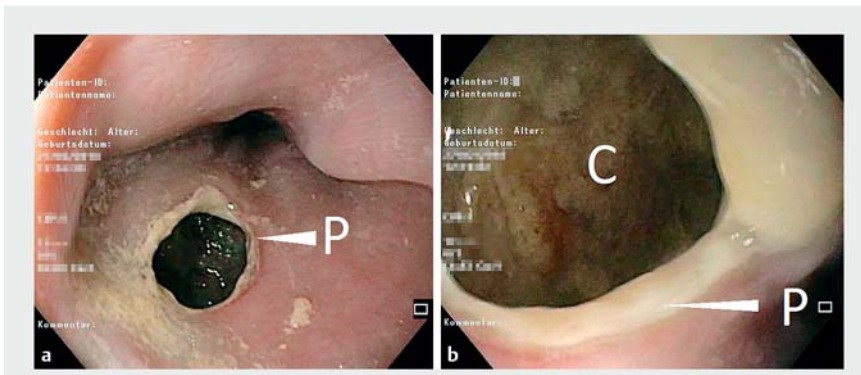


Iatrogenic esophageal perforation during fundoplication: treatment with endoscopic negative pressure therapy

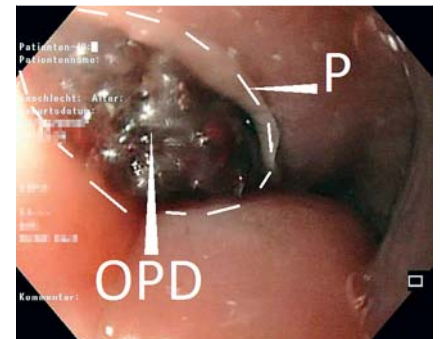
Iatrogenic esophageal perforation caused by insertion of a gastric tube during a fundoplication operation is a severe and rare intraoperative complication. A 64-year-old woman underwent laparoscopic Nissen fundoplication. Intraoperatively, a large-bore gastric tube was inserted as a placeholder for the esophageal lumen. At 5 days after the procedure, increasing inflammation parameters and thoracic pain led to endoscopic examination.

At 5 cm from the oral side of the gastroesophageal junction, we found a transmural defect of 1.5 cm in diameter (► **Fig. 1 a**). The perforation opened into an extraluminal cavity filled with saliva and food (► **Fig. 1 b**), which was removed endoscopically. For intracavitary endoscopic negative pressure therapy (ENPT) [1–3], open-pore polyurethane foam drainage (OPD; Endo-SPONGE; B. Braun Melsungen AG, Melsungen, Germany), 1.5 cm in diameter and 4 cm in length

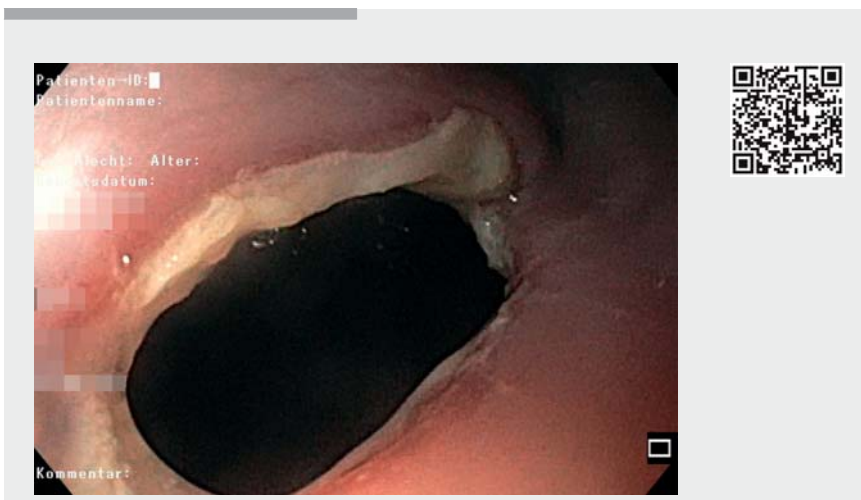
was fixed with a suture to the tip of a gastric tube (Ventrol, 12 Ch × 120 cm; Covidien Argyle, Dublin, Ireland). The foam was inserted using endoscopic forceps and pushed into the cavity through the defect. The tube was led out nasally, and negative pressure was applied using an electronic pump (KCI Activac; –125 mmHg, continuous, highest intensity). Suction resulted in drainage and collapse of the cavity and closure of the defect (► **Fig. 2**, ► **Video 1**).



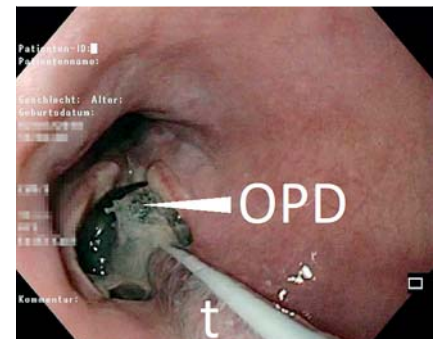
► **Fig. 1** Endoscopic view of the esophageal perforation (P). **a** The perforation in the distal esophagus. **b** The perforation and the extraluminal cavity (C) filled with saliva and food.



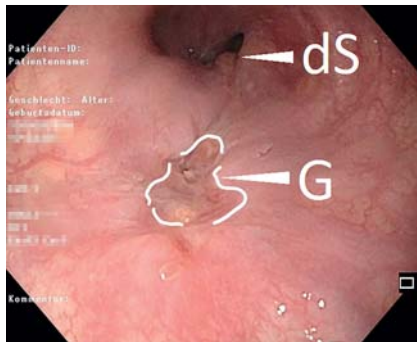
► **Fig. 2** Application of negative pressure resulted in the perforation (P) being sucked onto the open-pore polyurethane foam drainage sponge (OPD) and closure of the defect.



► **Video 1** Endoscopic negative pressure therapy for iatrogenic esophageal perforation, resulting in complete healing of the perforation defect.



► **Fig. 3** Day 3 of endoscopic negative pressure therapy before exchange of open-pore polyurethane foam drainage (OPD). The device was without suction function. The pores of the OPD were blocked with secretions and the drainage device needed to be changed. The OPD tube (t) was led out nasally and connected externally to the electronic vacuum device.



► **Fig. 4** Endoscopic image 8 days after the end of endoscopic negative pressure therapy. Treatment resulted in closure of the perforation defect, which is filled with granulation tissue (G). dS, distal esophageal sphincter.

ENPT was continued for 12 days in total. Drainage was renewed four times, in an interval of 1–3 days. At the first exchange after 3 days, we found that the foam was blocked with mucous secretions (► **Fig. 3**). We subsequently reduced the exchange interval. After 10 days of intracavitary ENPT, the shrunken cavity was filled with granulation tissue (► **Fig. 4**).

The final period of ENPT was done within the esophageal lumen (intraluminal ENPT) using a double-lumen open-pore film drainage (OFD) [4, 5]. OFD was built with a Trilumina tube (Freka Trilumina, CH/Fr 16/9, 150 cm; Fresenius Kabi AG, Bad Homburg, Germany) and a thin, double-layered, open-pore film (Suprasorb CNP, Drainage Film; Lohmann & Rauscher International, Rengsdorf Germany) [5]. After the end of ENPT, enteral nutrition was started with a soft diet. At follow-up endoscopy 64 days after the end of ENPT, we observed complete healing and a small scar.

Endoscopy_UCTN_Code_TTT_1AQ_2AI

Acknowledgments

We would like to thank the nursing staff of the interdisciplinary endoscopy unit of Marienkrankenhaus Hamburg for their excellent technical assistance. We also wish to thank our colleagues from the intermediate care unit for their good cooperation.

Competing interests

Dr. Loske is a consultant for Lohmann & Rauscher GmbH & Co.KG.

The authors

Gunnar Loske¹, Tobias Schorsch¹, Wolfgang Schulze¹, Norbert Rolf², Christian T. Mueller¹

- 1 Department for General, Abdominal, Thoracic and Vascular Surgery, Katholisches Marienkrankenhaus Hamburg gGmbH, Hamburg, Germany
- 2 Clinic for Anaesthesiology, Pain Therapy and Intensive Care, Katholisches Marienkrankenhaus Hamburg gGmbH, Hamburg, Germany

Corresponding author

Gunnar Loske, MD

Department for General, Abdominal, Thoracic and Vascular Surgery, Katholisches Marienkrankenhaus Hamburg gGmbH, Alfredstrasse 9, 22087 Hamburg, Germany
 Fax: +49-40-25461400
 loske.chir@marienkrankenhaus.org

References

- [1] Loske G, Schorsch T, Müller C. Intraluminal and intracavitary vacuum therapy for esophageal leakage: a new endoscopic minimally invasive approach. *Endoscopy* 2011; 43: 540–544
- [2] Loske G. Endoscopic negative pressure therapy of the upper gastrointestinal tract. *Chirurg* 2019; 90 (Suppl. 01): 1–6
- [3] Loske G, Müller CT. Tips and tricks for endoscopic negative pressure therapy. *Chirurg* 2019; 90 (Suppl. 01): 7–14
- [4] Loske G, Schorsch T, Rucktaeschel F et al. Open-pore film drainage (OFD): a new multipurpose tool for endoscopic negative pressure therapy (ENPT). *Endosc Int Open* 2018; 6: E865–E871
- [5] Loske G, Schorsch T, Müller CT. Prevention of reflux after esophagectomy with endoscopic negative pressure therapy using a new double-lumen open-pore film drainage with an intestinal feeding tube. *Endoscopy* 2017; 49: E294–E295

Bibliography

DOI <https://doi.org/10.1055/a-0896-2627>

Published online: 9.5.2019

Endoscopy 2019; 51: E267–E268

© Georg Thieme Verlag KG

Stuttgart · New York

ISSN 0013-726X

ENDOSCOPY E-VIDEOS

<https://eref.thieme.de/e-videos>



Endoscopy E-Videos is a free access online section, reporting on interesting cases and new

techniques in gastroenterological endoscopy. All papers include a high quality video and all contributions are freely accessible online.

This section has its own submission website at

<https://mc.manuscriptcentral.com/e-videos>