

Fracture of 19G needle during transrectal endoscopic ultrasound-guided drainage of perirectal collection: an unusual complication

A 54-year-old woman was referred to our hospital for general sepsis. Computed tomography (CT) scan highlighted a collection of size 7 cm in the pouch of Douglas. The patient had a medical history of previous salpingo-oophorectomy coupled with appendectomy for pelvic inflammatory disease.

Endoscopic ultrasound (EUS)-guided drainage of the collection was attempted. The perirectal collection was identified by transrectal EUS and was easily punctured with a 19G needle (Cook Medical). A guidewire was inserted into the collection under fluoroscopic control. Cautery of the entry site was performed with a 10-Fr cystotome, a 10-Fr double-pigtail plastic stent was delivered, and successful drainage of the cavity with outflow of purulent fluid into the rectum was obtained. At the end of the procedure re-evaluation of fluoroscopic images (after scope withdrawal) highlighted a metallic foreign body, 4 cm long, close to the stent (► **Fig. 1**).

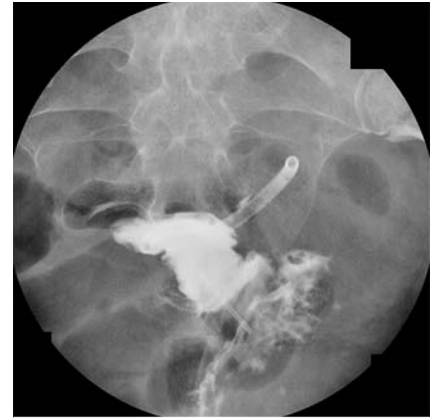When the needle was advanced outside the external sheath, our suspicion of needle fracture was confirmed.

Lower endoscopy visualized the ruptured needle almost fixed against the rectal wall. The needle was retrieved using a foreign body forceps with attention paid to avoid injury to the rectum and the anal canal (► **Video 1**).

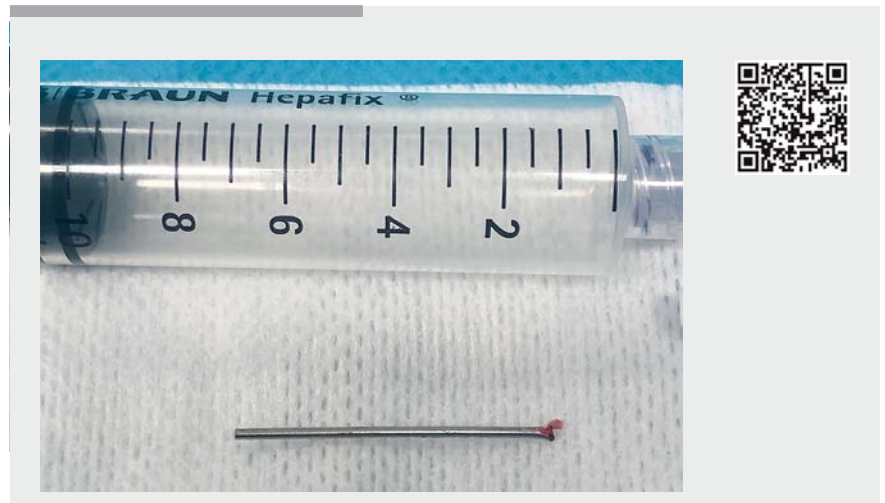
Needle fracture has been reported as a rare complication after EUS-fine needle aspiration (EUS-FNA) of pancreatic and endobronchial masses [1,2]. In addition an incidental finding of intravascular migration of a fractured needle 6 months after the index EUS-FNA has been reported [3].

Risk factors have been supposed to be stiffness of the target lesion, bent position of the scope, or excessive elevator movement. Needle fracture can easily go unnoticed, since the integrity of the needle after EUS puncture is seldom checked. Whenever therapeutic EUS procedures are performed, concomitant use of fluoroscopy is advisable not only to guide the different procedural steps but also to detect early complications. Although needle fracture is very rare, its early detection is of extreme importance in order to avoid long-term sequelae and re-interventions.

Endoscopy_UCTN_Code_CPL_1AL_2AZ



► **Fig. 1** Fluoroscopic image showing a double-pigtail plastic stent draining a perirectal collection, and a metallic foreign body 4 cm in length close to the stent.



► **Video 1** Fracture of a 19G needle during endoscopic ultrasound (EUS)-guided drainage of a perirectal collection. Early detection allowed endoscopic removal of the fractured part without complications.

Competing interests

None

The authors

Gianfranco Donatelli¹, Fabrizio Cereatti²

- 1 Unité d'Endoscopie Interventionnelle, Hôpital Privé des Peupliers, Ramsay Générale de Santé, Paris, France
- 2 Gastroenterologia ed Endoscopia Digestiva ASST Cremona, Cremona, Italy

Corresponding author

Gianfranco Donatelli, MD

Unité d'Endoscopie Interventionnelle, Ramsay Générale de Santé, Hôpital Privé des Peupliers, 8 Place de l'Abbé G. Hénocque, 75013, Paris, France
Fax: +33-1-44165615
donatelligianfranco@gmail.com

References

- [1] Rimbaş M, Attili F, Andrade Zurita S et al. Fractured needle during endoscopic ultrasound-guided fine-needle aspiration of a pancreatic head mass. *Endoscopy* 2015; 47 (Suppl. 01): E432
- [2] Vial MR, O'Connell JO, Grosu HB et al. Needle fracture during endobronchial ultrasound-guided transbronchial needle aspiration. *Am J Respir Crit Care Med* 2016; 193: 213–214
- [3] Lake E, Puleston J, Farquharson F. Intra-arterial migration of a fractured endoscopic needle. *Endoscopy* 2017; 49: E70–E72

Bibliography

DOI <https://doi.org/10.1055/a-0896-2336>

Published online: 9.5.2019

Endoscopy 2019; 51: E263–E264

© Georg Thieme Verlag KG

Stuttgart · New York

ISSN 0013-726X

ENDOSCOPY E-VIDEOS

<https://eref.thieme.de/e-videos>



Endoscopy E-Videos is a free access online section, reporting on interesting cases and new techniques in gastroenterological endoscopy. All papers include a high quality video and all contributions are freely accessible online.

This section has its own submission website at <https://mc.manuscriptcentral.com/e-videos>