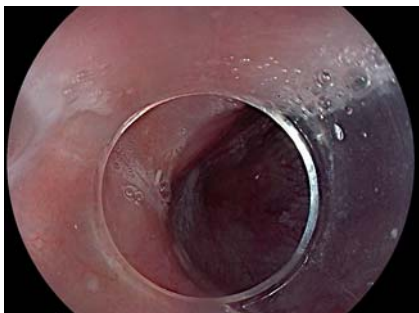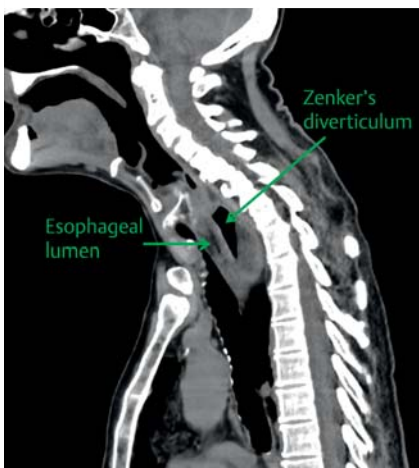


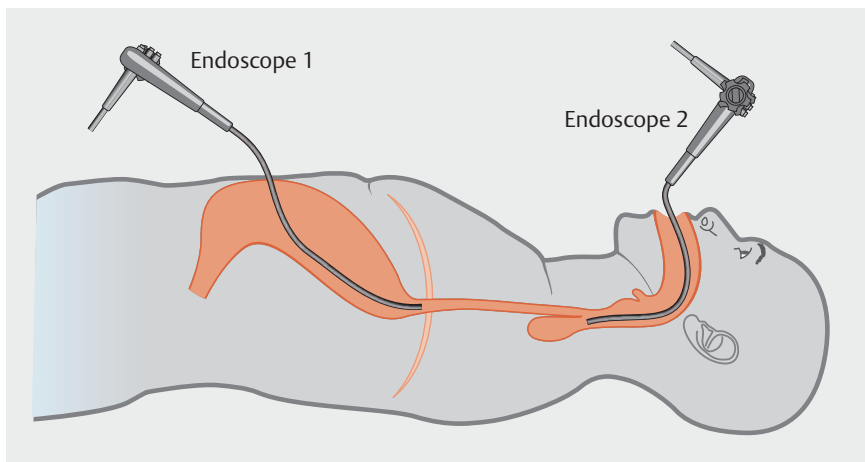
Dual flexible endoscopic rendezvous approach for management of a Zenker's diverticulum with complete esophageal obstruction



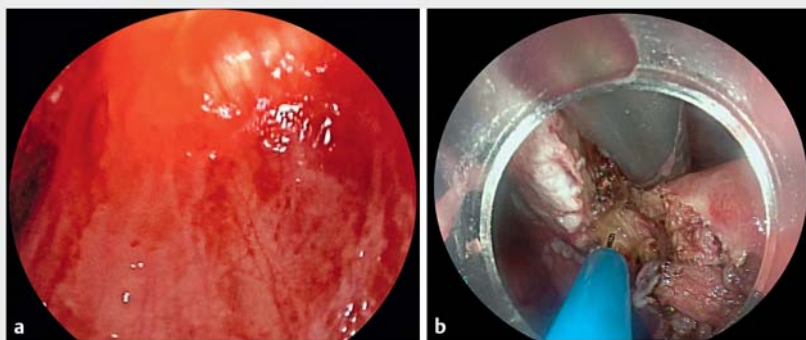
► **Fig. 1** View during esophagogastroduodenoscopy showing a large Zenker's diverticulum with complete esophageal obstruction at the level of the cricopharyngeal muscle.



► **Fig. 2** Computed tomography scan showing a large diverticulum impinging on the proximal esophagus.



► **Fig. 3** Schematic showing the dual endoscopic retrograde-antegrade approach using the established gastrostomy tract and the peroral route that was planned in order to reopen the completely obstructed esophageal lumen and safely perform a flexible endoscopic cricopharyngeal myotomy.

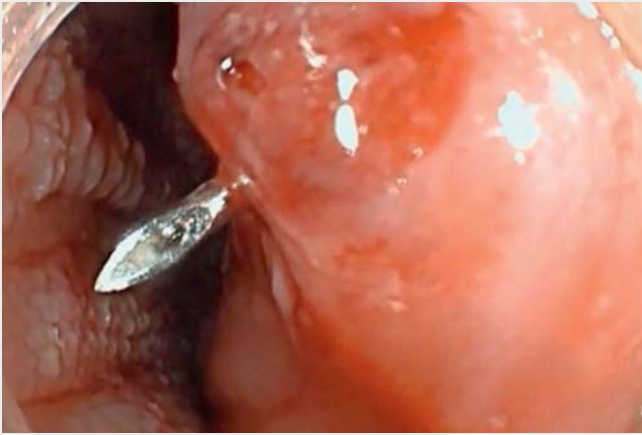

► **Fig. 4** Endoscopic views showing: **a** the two endoscopes being aligned by endoscopic transillumination; **b** flexible endoscopic cricopharyngeal myotomy being performed under direct visualization using a hook knife.

Therapy for symptomatic Zenker's diverticulum has evolved from an open surgical approach to transoral endoscopic techniques using rigid instruments or flexible endoscopes. A recent meta-analysis confirmed that flexible endoscopic myotomy for Zenker's diverticulum is effective and safe [1]. Complete esophageal obstruction is a rare complication that is caused by fusion of the proximal esophageal lumen with the septum of the Zenker's diverticulum [2, 3].

We present a case of a 59-year-old man who presented with aphagia with a 7-year history of progressive dysphagia due to a Zenker's diverticulum. A surgical gastrostomy had been created 1 year previously and the patient had been maintained exclusively on enteral nutrition. Esophagogastroduodenoscopy (EGD) and a computed tomography (CT) scan demonstrated a large Zenker's diverticulum with complete esophageal

obstruction at the level of the cricopharyngeal muscle suggesting fusion of the esophageal lumen (► **Fig. 1** and ► **Fig. 2**). A dual endoscopic retrograde-antegrade approach was planned (► **Fig. 3**). An ultraslim endoscope (5.9-mm diameter; endoscope 1) was introduced through the percutaneous gastrostomy site. A tight distal esophageal stricture was encountered as a consequence of the defunctionalized esophagus, there-



▶ Video 1 A dual endoscopic retrograde–antegrade approach for management of a Zenker's diverticulum (ZD) with complete esophageal obstruction.

fore a pneumatic dilation up to 10 mm was performed (▶ **Video 1**). Subsequently, the endoscope was further advanced in a retrograde fashion up to the proximal esophagus, where a complete esophageal obstruction was confirmed. A peroral endoscope (9.9-mm diameter; endoscope 2) was advanced into the hypopharynx and both endoscopes were aligned by transillumination (▶ **Fig. 4a**). Subsequently, retrograde puncture with an injection needle was performed, followed by insertion of a guidewire into the hypopharynx. After capture of the guidewire, a mechanical dilation was performed and a nasogastric tube placed. A flexible endoscopic septotomy was performed 1 week later using a hook knife (▶ **Fig. 4b**).

After 6 weeks, the patient had gained weight and was eating a regular diet. A barium esophagram and an EGD showed the diverticular pouch was in complete connection with the esophageal lumen. To our knowledge, this is the first reported case of flexible endoscopic septotomy

for the management of a Zenker's diverticulum after recanalization of complete esophageal obstruction using a dual endoscopic retrograde–antegrade approach. This technique appears to be a promising alternative to surgery in such a complex condition.

Endoscopy_UCTN_Code_TTT_1AO_2AN

Competing interests

None

The authors

Alessandro Fugazza¹, Annalisa Cappello¹, Roberta Maselli¹, Paul Belletrutti², Alessia Galtieri¹, Gaia Pellegatta¹, Alessandro Repici^{1,2}

- 1 Digestive Endoscopy Unit, Division of Gastroenterology, Humanitas Research Hospital, Rozzano, Milan, Italy
- 2 Humanitas University, Rozzano, Milan, Italy

Corresponding author

Alessandro Fugazza, MD

Digestive Endoscopy Unit, Division of Gastroenterology, Humanitas Research Hospital, Via Manzoni 56, 20089 Rozzano (Milano), Italy
alessandro.fugazza@humanitas.it

References

- [1] Ishaq S, Hassan C, Antonello A et al. Flexible endoscopic treatment for Zenker's diverticulum: a systematic review and meta-analysis. *Gastrointest Endosc* 2016; 83: 1076–1089
- [2] Shah AT, Wein RO. Management of a post-radiation esophageal web in the setting of a coexisting Zenker's diverticulum. *Ann Otol Rhinol Laryngol* 2013; 122: 775–778
- [3] Van Twisk JJ, Brummer RJ, Manni JJ. Retrograde approach to pharyngo-esophageal obstruction. *Gastrointest Endosc* 1998; 48: 296–299

Bibliography

DOI <https://doi.org/10.1055/a-0894-4324>
Published online: 9.5.2019
Endoscopy 2019; 51: E259–E260
© Georg Thieme Verlag KG
Stuttgart · New York
ISSN 0013-726X

ENDOSCOPY E-VIDEOS

<https://eref.thieme.de/e-videos>



Endoscopy E-Videos is a free access online section, reporting on interesting cases and new

techniques in gastroenterological endoscopy. All papers include a high quality video and all contributions are freely accessible online.

This section has its own submission website at <https://mc.manuscriptcentral.com/e-videos>