

## The “bubble sign”: a novel way to detect a perforation after cold snare polypectomy

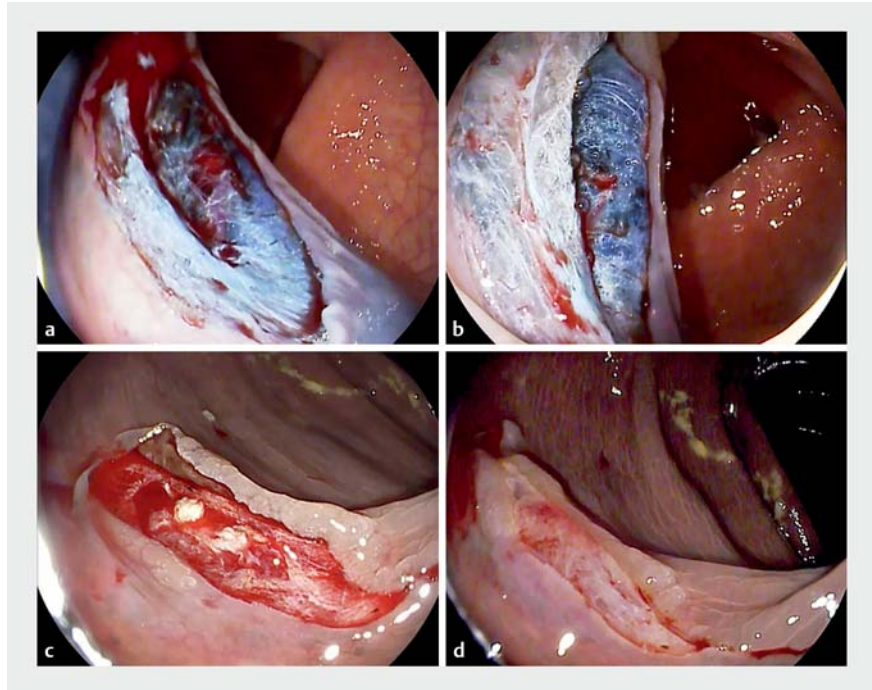
To date, there have been no reported perforations with cold snare polypectomy (CSP). Therefore, possible signs of damage in the muscular layer remain unknown. We report the first cases of perforation using cold snare polypectomy, when two polyps <20 mm in size were removed. Thus we are able to describe a new sign, the “bubble sign,” for checking the integrity of the submucosal and muscular layer, that can help to detect potential injury in the colonic wall when cold snare polypectomy is performed.

CSP is now a highly recommended procedure for treatment of sessile adenomas up to 10 mm in size [1]. Indeed, a recent comparative study shows better results for CSP compared with hot snare polypectomy in terms of safety [2], with no perforations related to CSP described to date.

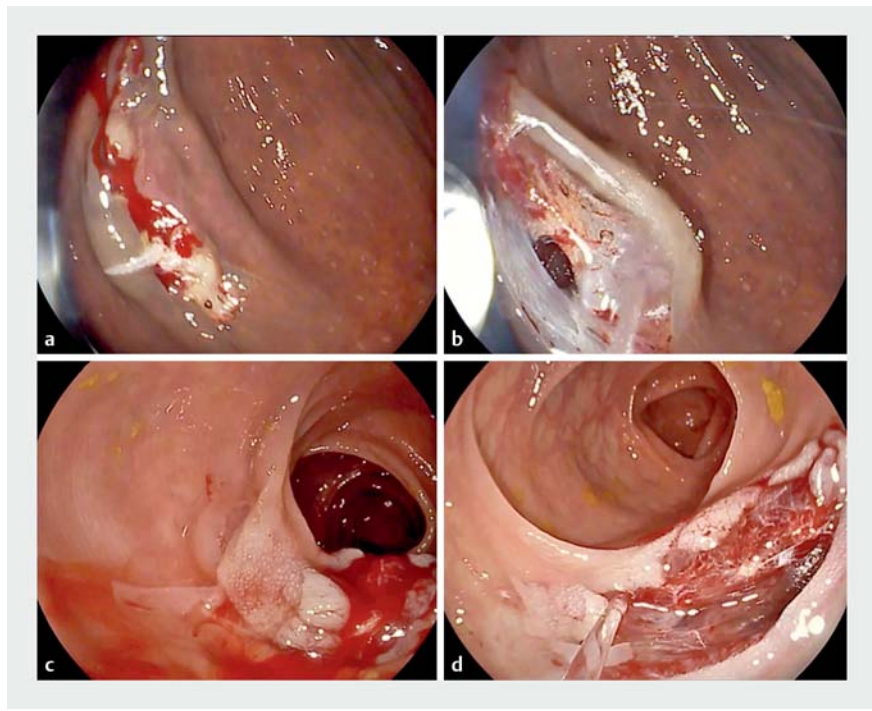
After CSP, the post-polypectomy site is irrigated with a waterjet. Because the submucosal layer has been preserved, the creation of a cushion is observed. We have called this the “bubble sign” (► Fig. 1). However when the submucosal and muscular layer have been disrupted this cushion is missing.

We present two cases of perforation with CSP (10-mm 0-IIs and 15-mm 0-IIb polyps) where a snare was used that was not specifically designed for CSP (13-mm hexagonal Captivator; Boston Scientific). In both cases no bubble sign was noticed (► Fig. 2). Fortunately both cases were successfully managed by endoscopic clipping (Resolution Clips; Boston Scientific). The patients were admitted for observation and discharged 24 hours later without any adverse event.

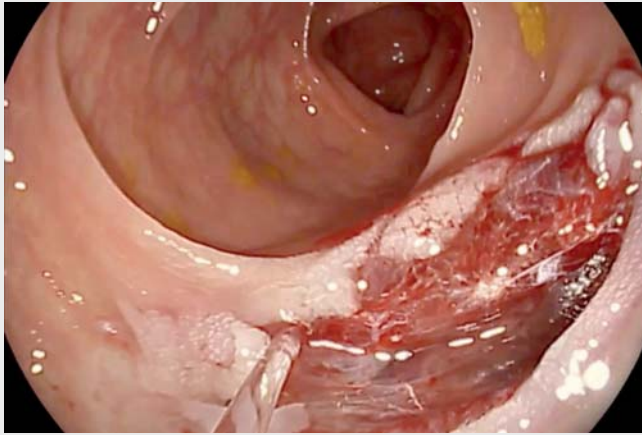
To date these are the first reported cases of perforation related to CSP. In fact, in two recent published meta-analyses, which included more than 1000 CSP cases, no perforations were noted [3,4]. However, these events have allowed us to point out the usefulness of the bubble sign in assessing potential injury in the muscular layer.



► Fig. 1 Cold snare polypectomy (CSP) with no perforation. a, c Colonic sites after CSP. b, d “Bubble sign” after irrigation by waterjet.



► Fig. 2 Cold snare polypectomy (CSP) with perforation. a, c Colonic sites after CSP. b, d No “bubble sign” is seen after irrigation by waterjet.



**Video 1** The “bubble sign” and perforation at cold snare polypectomy (CSP).

Regarding the mechanism that led to the perforations, we consider two main factors: first the tension in the colon wall when the snare was closed might not have been appropriate (because of insufficient colonic distension), and secondly, a snare not specifically designed for CSP was used for both procedures. Although CSP is an extremely safe procedure, these findings lead us to keep in mind that there is an urgent need to standardize the technique, as well as the recommendation to use snares specifically designed to perform it.

Endoscopy\_UCTN\_Code\_CPL\_1AJ\_2AC

### Competing interests

None

### The authors

**Joaquín Rodríguez Sánchez<sup>1</sup>, Mónica Sánchez Alonso<sup>1</sup>, María Pellisé Urquiza<sup>2</sup>**

- 1 Gastrointestinal Endoscopy Unit, Hospital General Universitario de Ciudad Real, Ciudad Real, Spain
- 2 Gastroenterology Department, Hospital Clinic de Barcelona, Barcelona, Spain

### Corresponding author

**Joaquín Rodríguez Sánchez, MD, PhD**  
Gastrointestinal Endoscopy Unit, Hospital General Universitario de Ciudad Real, C/Obispo Rafael Torija s/n, Ciudad Real 13005, Spain  
Fax: +34-926-278000  
joakinrodriguez@gmail.com

### References

- [1] Ferlitsch M, Moss A, Hassan C et al. Colorectal polypectomy and endoscopic mucosal resection (EMR): European Society of Gastrointestinal Endoscopy (ESGE) Clinical Guideline. *Endoscopy* 2017; 49: 270–297
- [2] Takayanagi D, Nemoto D, Isohata N et al. Histological comparison of cold versus hot snare resections of the colorectal mucosa. *Dis Colon Rectum* 2018; 61: 964–970
- [3] Shinozaki S, Kobayashi Y, Hayashi Y et al. Efficacy and safety of cold versus hot snare polypectomy for resecting small colorectal polyps: Systematic review and meta-analysis. *Dig Endosc* 2018; 30: 592–599
- [4] Qu J, Jian H, Li L et al. Effectiveness and safety of cold versus hot snare polypectomy: A meta-analysis. *J Gastroenterol Hepatol* 2019; 34: 49–58

### Bibliography

DOI <https://doi.org/10.1055/a-0881-2856>  
Published online: 9.5.2019  
*Endoscopy* 2019; 51: 796–797  
© Georg Thieme Verlag KG  
Stuttgart · New York  
ISSN 0013-726X

### ENDOSCOPY E-VIDEOS

<https://eref.thieme.de/e-videos>



*Endoscopy E-Videos* is a free access online section, reporting on interesting cases and new techniques in gastroenterological endoscopy. All papers include a high quality video and all contributions are freely accessible online.

This section has its own submission website at <https://mc.manuscriptcentral.com/e-videos>