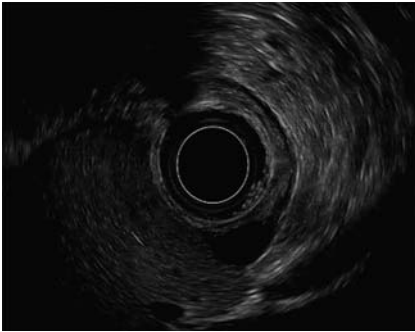
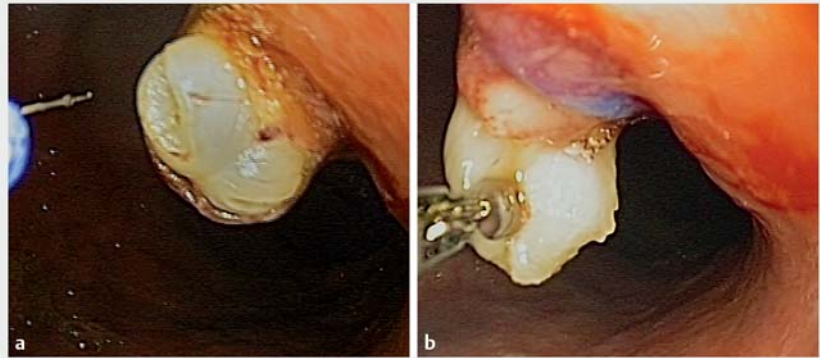


Endoscopic band ligation plus single-incision needle knife biopsy for small subepithelial deep-layer tumor: easy and effective



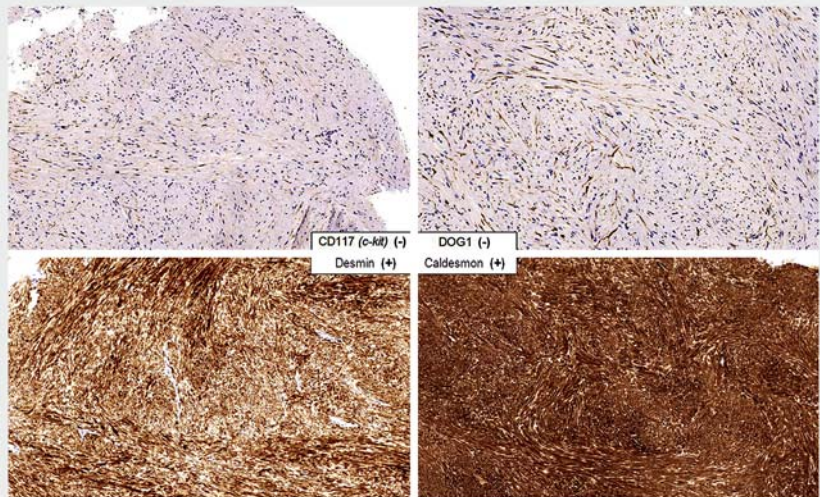
► **Fig. 1** Endoscopic ultrasound view of a small gastric subepithelial tumor, seen fortuitously during a diagnostic process for iron-deficiency anemia.



► **Fig. 2** **a** Subepithelial tumor: endoscopic view of single-incision needle knife (SINK) biopsy. **b** Use of biopsy forceps to obtain samples for anatomopathological study.

A 61-year-old man was referred for an iron-deficiency anemia diagnostic process. Upper gastrointestinal endoscopy was performed and fortuitously revealed a small gastric subepithelial lesion. Endoscopic ultrasound (EUS) characterization revealed a solid lesion, with fusiform morphology, well-defined by smooth edges and an hypoechoic homogeneous internal pattern, measuring 12.3 × 5.8 mm, and originating in the muscularis propria layer, which confirmed a subepithelial tumor (► **Fig. 1**). With the aim of avoiding EUS surveillance of the subepithelial tumor, a minimally invasive removal technique was planned [1–3].

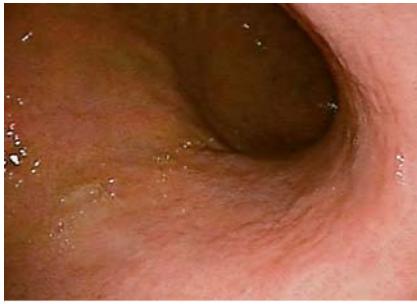
Endoscopic band ligation of the subepithelial tumor was done using a Captivator endoscopic mucosal resection standard gastroscope device (Boston Scientific, Quincy, Massachusetts, USA) combined with a single-incision needle knife (SINK) biopsy (XL Triple-lumen needle knife; Boston Scientific; and pure-cut 90-W, Beamer CE600; ConMed, Utica, New York, USA). A standard videogastroscope was used, and four biopsy samples were obtained (Radial Jaw large capacity biopsy forceps; Boston Scientific) (► **Fig. 2**). The patient remained in hospital for 24 hours and was called at



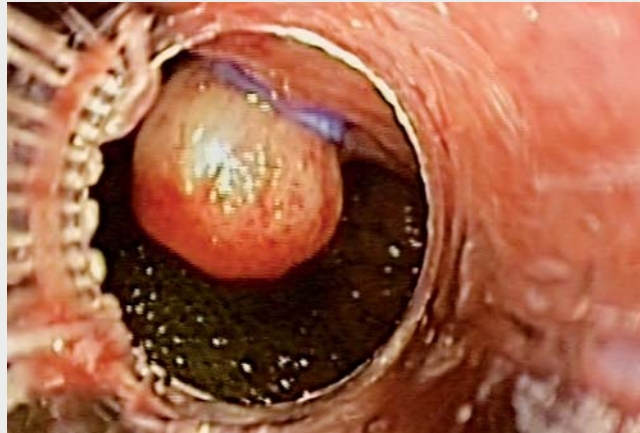► **Fig. 3** Immunohistochemistry markers confirming a leiomyoma.

48 hours and 7 days after the procedure, with no incidents or adverse events being reported (► **Video 1**). Pathological and immunohistochemistry examination revealed a fascicular proliferation of fusiform eosinophilic cells, negative for CD117 (c-kit) and DOG1, and positive for desmin and caldesmon, corresponding to the diagnosis of a leiomyoma (► **Fig. 3**).

The first EUS control, at 5 weeks after the procedure, revealed a complete disappearance of the subepithelial tumor features, showing a discreet eschar (simple biopsy with 4 samples, showing normal gastric mucosa). Long-term EUS control at 1 year showed that the subepithelial tumor had vanished, confirming the successful result and allowing discontinuation of endoscopic surveillance (► **Fig. 4**).



► **Fig. 4** Endoscopic view of gastric wall 1 year after the procedure, showing no sign of the subepithelial tumor.



► **Video 1** Endoscopic band ligation without resection, plus single-incision needle knife biopsy, for a gastric subepithelial tumor.

Endoscopic band ligation combined with SINK biopsy seems to be an effective minimally invasive technique that is safer than endoscopic resection for treating a gastric subepithelial tumor originating in the muscularis propria [4, 5].

Endoscopy_UCTN_Code_TTT_1AO_2AG

Competing interests

None

The authors

Francesc Bas-Cutrina¹, Claudia F. Consiglieri¹, Jan Bosch-Schips², Joan B. Gornals^{1,3}

- 1 Endoscopy Unit, Department of Digestive Diseases, Hospital Universitari de Bellvitge-IDIBELL, University of Barcelona, Catalonia, Spain.
- 2 Department of Pathological Anatomy, Hospital Universitari de Bellvitge-IDIBELL, University of Barcelona, Catalonia, Spain.
- 3 Faculty of Health Sciences, Universitat Oberta de Catalunya, Barcelona, Catalonia, Spain

Corresponding author

Joan B. Gornals, MD, PhD

Endoscopy Unit, Department of Digestive Diseases, Hospital Universitari de Bellvitge-IDIBELL (Bellvitge Biomedical Research Institute), Feixa Llargà s/n, 08907 L'Hospitalet de Llobregat, Barcelona, Catalonia, Spain
 Fax: +34-93-2607681
 jgornals@bellvitgehospital.cat

References

- [1] Faulx AL, Kothari S, Acosta RD et al. The role of endoscopy in subepithelial lesions of the GI tract. *Gastrointest Endosc* 2017; 85: 1117–1132
- [2] Arezzo A, Verra M, Miegge A et al. Loop-and-let-go technique for a bleeding, large sessile gastric gastrointestinal stromal tumor (GIST). *Endoscopy* 2011; 43: E18–19
- [3] Binmoeller KF, Shah JN, Bhat YM et al. Suck-ligate-unroof-biopsy by using a detachable 20-mm loop for the diagnosis and therapy of small subepithelial tumors (with video). *Gastrointest Endosc* 2014; 79: 750–755
- [4] Hwang JH, Konda V, Abu Dayyeh BK et al. Endoscopic mucosal resection. *Gastrointest Endosc* 2015; 82: 215–226
- [5] Zang D, Lin Q, Shi R et al. Ligation-assisted endoscopic submucosal resection with apical mucosal incision to treat gastric subepithelial tumors originating from the muscularis propria. *Endoscopy* 2018; 50: 1180–1185

Bibliography

DOI <https://doi.org/10.1055/a-0875-3958>
 Published online: 12.4.2019
 Endoscopy 2019; 51: E191–E192
 © Georg Thieme Verlag KG
 Stuttgart · New York
 ISSN 0013-726X

ENDOSCOPY E-VIDEOS
<https://eref.thieme.de/e-videos>



Endoscopy E-Videos is a free access online section, reporting on interesting cases and new techniques in gastroenterological endoscopy. All papers include a high quality video and all contributions are freely accessible online.

This section has its own submission website at
<https://mc.manuscriptcentral.com/e-videos>