

## Successful endoscopic submucosal dissection of a large cavernous hemangioma in the colon

Endoscopic submucosal dissection (ESD) is regarded as a common treatment for complete resection of early gastrointestinal neoplasms [1]. However, few cases have been reported on ESD for resection of cavernous hemangioma in the digestive tract. Here we present a patient with a globular, pedunculated, cavernous hemangioma in the descending colon that was removed successfully en bloc by ESD without any bleeding (▶ **Video 1**).

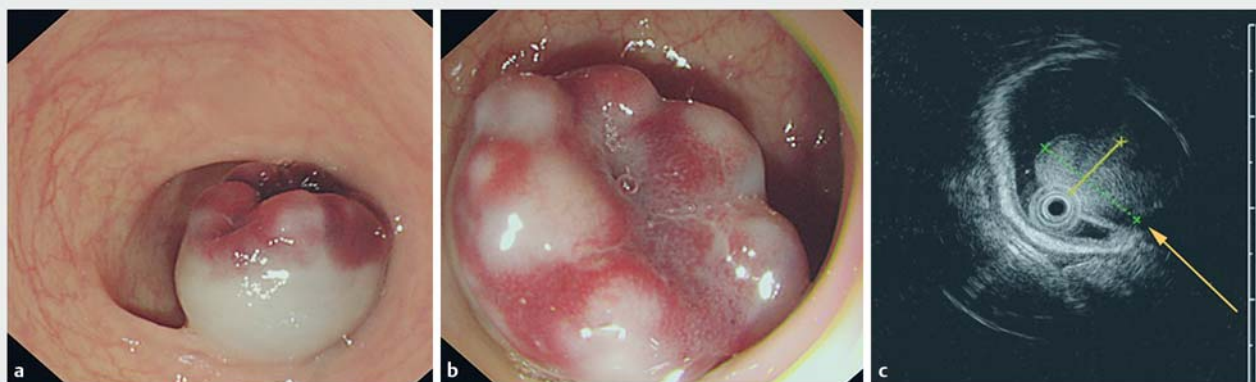
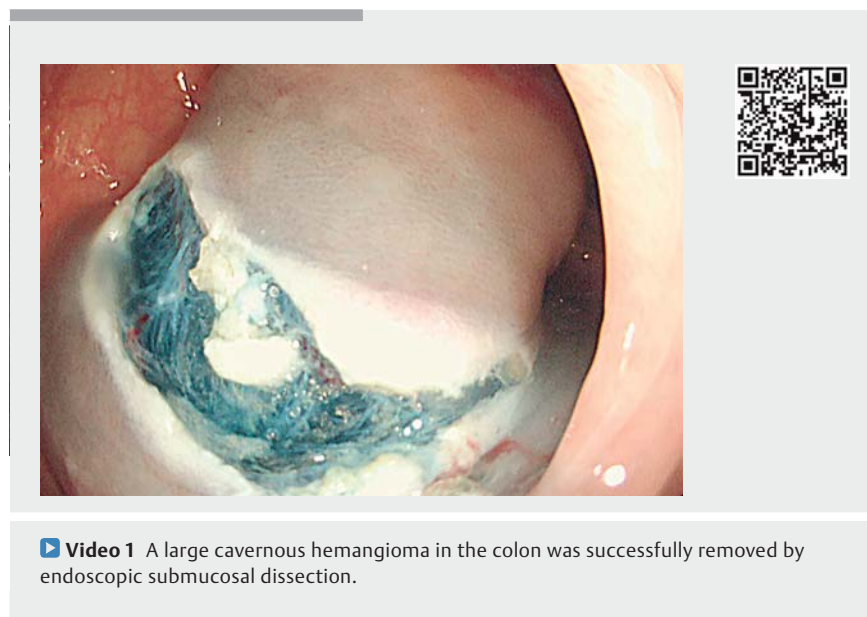
A 50-year-old woman was referred to our hospital for melena. Initial colonoscopy examination revealed a submucosal tumor approximately 20 mm in diameter in the descending colon, mainly characterized by a soft, globular, pedunculated submucosal lesion with a red-purple nodular surface (▶ **Fig. 1 a, b**). Further endoscopic ultrasonography indicated that the lesion originated from the submucosa. The lesion showed high echogenicity, mixed with a small anechogenic area on the inside, and with a decreased blood flow signal (▶ **Fig. 1 c**).

For treatment, we first performed endoscopic incision of the colonic mucosa using a Hybrid knife (Erbe, Tübingen, Germany) after submucosal injection (▶ **Fig. 2 a**). The submucosal dissection was very

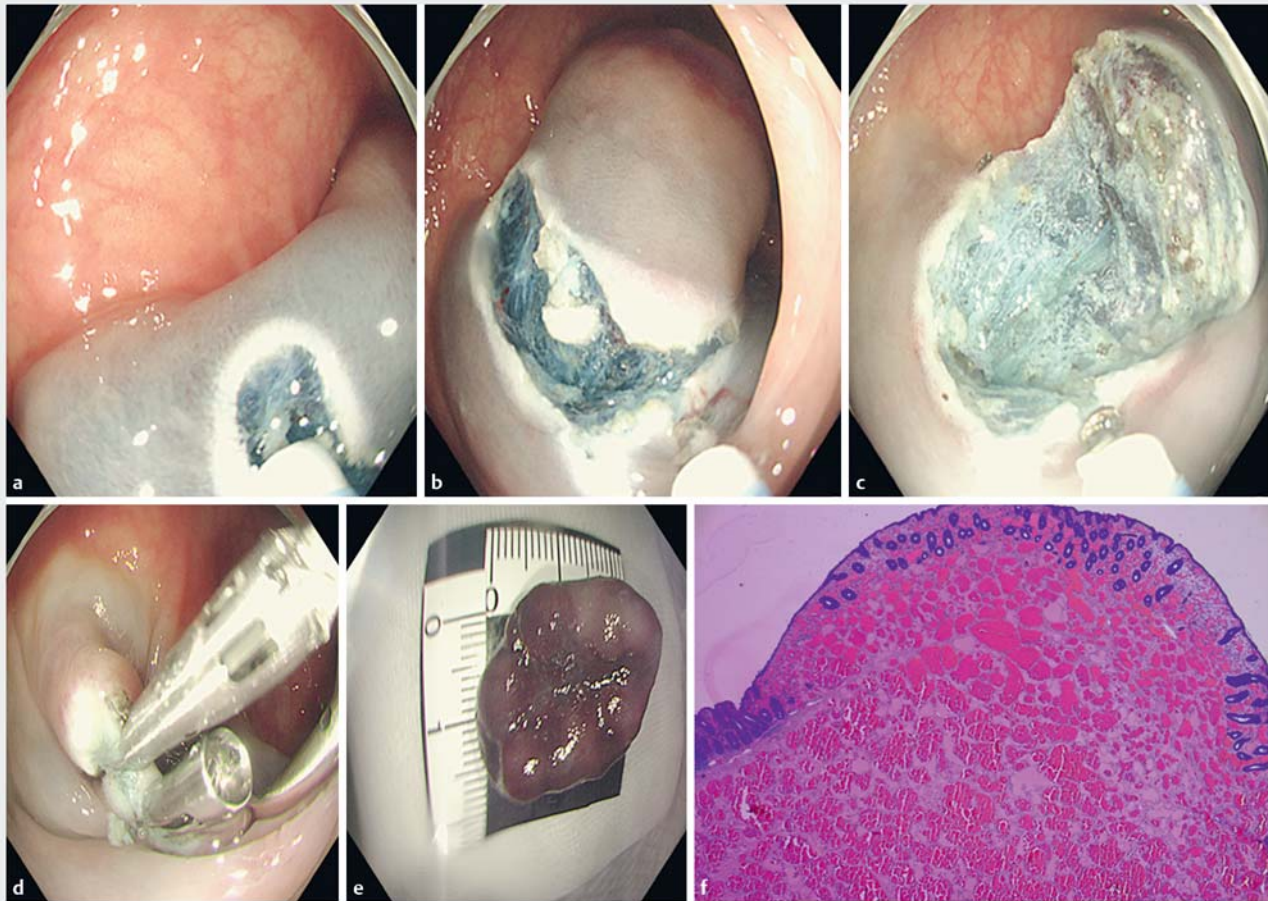
carefully performed to avoid damage to the body of the cavernous hemangioma and a clear field was maintained. The lesion was then successfully removed from the colon wall by ESD, as described previously (▶ **Fig. 2 b, c, e**). We used three clips (two from Anrei Medical, Hangzhou, China and one from Micro-Tech, Nanjing, China) for closure of the mucosal defect (▶ **Fig. 2 d**). Finally, histological examina-

tion of the resected specimen confirmed cavernous hemangioma (▶ **Fig. 2 f**). The patient was discharged with no further symptoms after 2 days of intravenous antibiotic treatment.

In summary, we believe that this is the first published report of a colonic cavernous hemangioma that has been completely removed by ESD.



▶ **Fig. 1** Colonoscopy and endoscopic ultrasonography examination of the submucosal lesion. **a, b** A submucosal tumor approximately 20 mm in diameter characterized by a soft, globular, pedunculated submucosal lesion with a red-purple nodular surface. **c** Endoscopic ultrasonography indicated that the lesion originated from the submucosa and showed high echogenicity, mixed with a small anechogenic area on the inside, and with decreased blood flow signal (yellow arrow).



► **Fig. 2** Colonic cavernous hemangioma was completely removed by endoscopic submucosal dissection (ESD). **a** An endoscopic incision of the mucosa was performed after submucosal injection. **b, c, e** The lesion was successfully removed from the colon wall by ESD. **d** Closure of the mucosal defect. **f** Histological examination of the resected specimen.

Endoscopy\_UCTN\_Code\_CCL\_1AD\_2AF

### Competing interests

None

### The authors

Kan Chen<sup>1,\*</sup>, Min Yan<sup>2,\*</sup>, Feng Liu<sup>1</sup>

- 1 Department of Gastroenterology, Shanghai Tenth People's Hospital, Tongji University School of Medicine, Shanghai, China
- 2 Department of Pathology, Shanghai Tenth People's Hospital, Tongji University School of Medicine, Shanghai, China

\* These authors contributed equally to this work.

### Corresponding author

Feng Liu, MD

Department of Gastroenterology, Shanghai Tenth People's Hospital, Tongji University School of Medicine, Middle Yanchang Road No. 301, Jingan District, Shanghai 200072, China  
 Fax: +86-21-66300588  
 drliuffeng@hotmail.com

### Reference

- [1] Mavrogenis G, Hochberger J, Deprez P et al. Technological review on endoscopic submucosal dissection: available equipment, recent developments and emerging techniques. *Scand J Gastroenterol* 2017; 52: 486–498

### Bibliography

DOI <https://doi.org/10.1055/a-0875-3519>  
 Published online: 12.4.2019  
 Endoscopy 2019; 51: E195–E196  
 © Georg Thieme Verlag KG  
 Stuttgart · New York  
 ISSN 0013-726X