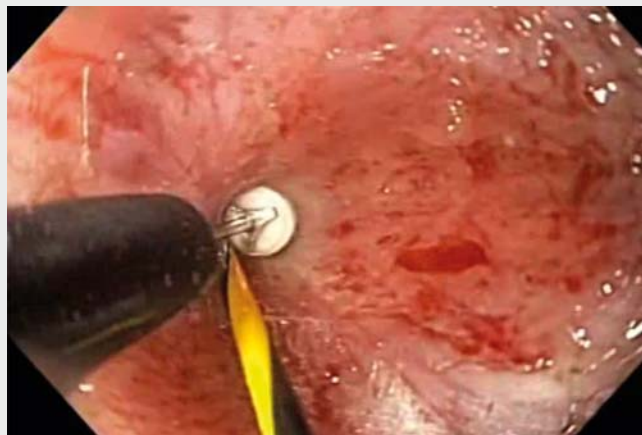

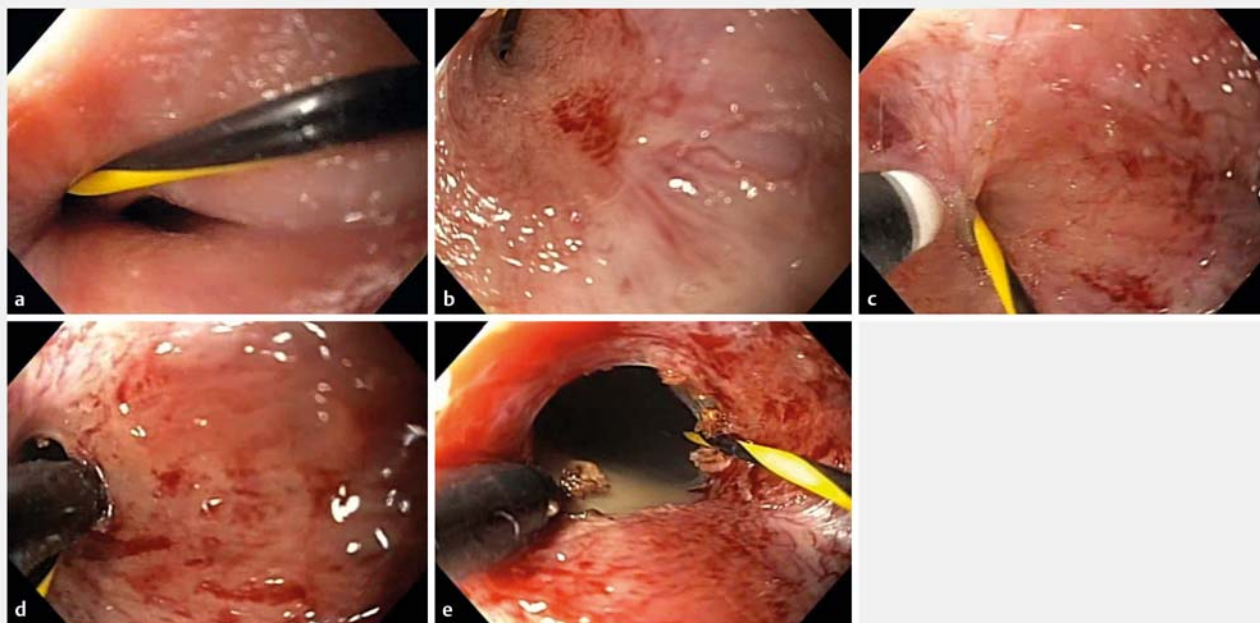
## Wire-guided stricturotomy for sealed ileal pouch

A 31-year-old woman with a 10-year history of ulcerative colitis was seen at our outpatient clinic with complaint of abdominal pain and increased output from her ileostomy. She had previously undergone a subtotal colectomy with an end ileostomy for medically refractory ulcerative colitis in 2008. She then underwent elective complete proctectomy with ileal pouch-anal anastomosis and diverting loop ileostomy 6 months later. We decided to perform pouchoscopy to rule out pouch-related complications (▶ **Video 1**).

Illeoscopy was performed via the stoma. The terminal ileum appeared normal to 25 cm from stoma. The patient was found to have a diverted pouch outlet stricture. The sealed outlet was detected by a Jag-



▶ **Video 1** Wire-guided stricturotomy for sealed ileal pouch.



▶ **Fig. 1** Wire-guided stricturotomy of sealed ileal pouch. **a** Sealed pouch outlet was detected by a Jagwire (Boston Scientific, Marlborough, Massachusetts, USA). **b** Diverted pouch outlet stricture was noted. **c** Knife stricturotomy was performed over the guidewire. **d** Knife stricturotomy was performed in a radial fashion. **e** Sealed ileal pouch was effectively treated with wire-guided stricturotomy.

wire (Boston Scientific, Marlborough, Massachusetts, USA) (► **Fig. 1 a, b**). We then performed knife stricturotomy over the guidewire (► **Fig. 1 c, d**). Moderate diversion pouchitis with exudates was noted. We were able to pass the scope without difficulty (► **Fig. 1 e**).

The patient tolerated the procedure well without any immediate complications. She reported improvement in her symptoms at the 1-month follow-up visit.

Sealed ileal pouch can be safely and effectively treated with wire-guided endoscopic stricturotomy.

Endoscopy\_UCTN\_Code\_TTT\_1AQ\_2AF

### Competing interests

None

### The authors

#### Freeha Khan, Bo Shen

Center for Inflammatory Bowel Disease, Digestive Disease and Surgical Institute, Cleveland Clinic, Cleveland, Ohio, United States

### Corresponding author

#### Bo Shen, MD

Center for Inflammatory Bowel Disease, Digestive Disease and Surgery Institute-A31, Cleveland Clinic, 9500 Euclid Ave., Cleveland, OH 44195, United States  
Fax: +1-216-444-6305  
shenb@ccf.org

### Bibliography

DOI <https://doi.org/10.1055/a-0840-3262>

Published online: 12.2.2019

Endoscopy 2019; 51: 493–494

© Georg Thieme Verlag KG

Stuttgart · New York

ISSN 0013-726X

### ENDOSCOPY E-VIDEOS

<https://eref.thieme.de/e-videos>



*Endoscopy E-Videos* is a free access online section, reporting on interesting cases and new

techniques in gastroenterological endoscopy. All papers include a high quality video and all contributions are freely accessible online.

This section has its own submission website at

<https://mc.manuscriptcentral.com/e-videos>