

## Blue rubber bleb nevus syndrome: endoscopic treatment with sclerotherapy during double-balloon enteroscopy in a 9-year-old boy

Blue rubber bleb nevus syndrome (BRBNS), also called Bean syndrome, is a rare disease associated with multiple venous malformations essentially in the skin and the gastrointestinal (GI) tract [1, 2]. It commonly presents with anemia and patients respond to supportive measures, but severe symptoms may be treated by surgical resection, endoscopic sclerotherapy, and laser photocoagulation [3, 4].

We report here a case of BRBNS presenting with GI bleeding in a 9-year-old boy who was first diagnosed at the age of 1, with a venous angioma in the knee. The onset of melena led to a complete exploration of the upper and lower GI tract, and capsule endoscopy, which revealed several typical blue lesions in the stomach (► Fig. 1 a, b), small bowel (► Fig. 2), and colon (► Fig. 1 c).

Gastric and colonic lesions were first treated with argon plasma coagulation (► Fig. 3) in the pediatric hospital. The patient was then referred to our unit for double-balloon enteroscopy (EN-580T; Fujifilm, Tokyo, Japan), through which we could identify five pedunculated lesions and four flat friable ones. The progression of the endoscope was difficult owing to the small size of the intestinal loops; however, successful sclerotherapy of the lesions was achieved by injecting

aetoxisclerol (► Video 1). Apart from these angiomas, no further lesions required treatment, according to capsule endoscopy. The patient did not experience any new bleeding after this treatment.

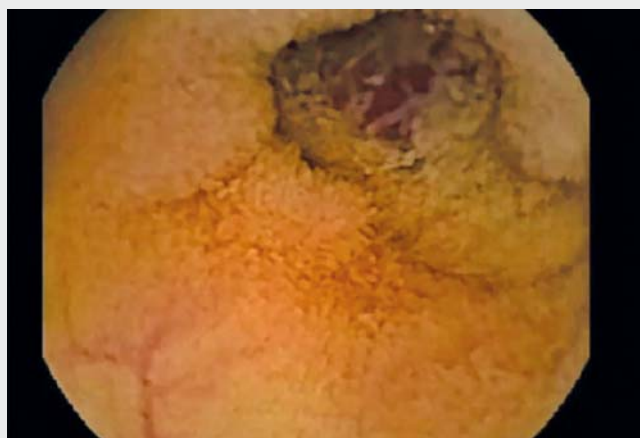
In conclusion, BRBNS is rare but the diagnosis has to be considered when typical lesions are seen in different areas. Double-balloon enteroscopy using an adult enteroscope appears to be feasible in children, but progression is probably

more difficult in a small-diameter bowel. As previously demonstrated, aetoxisclerol seems to be effective for the treatment of lesions with low risk of perforation.

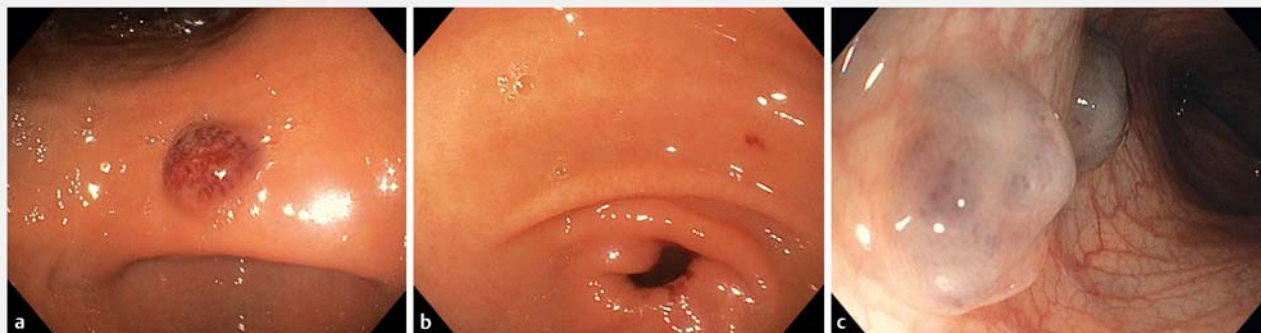Endoscopy\_UCTN\_Code\_TTT\_1AP\_2AD

### Competing interests

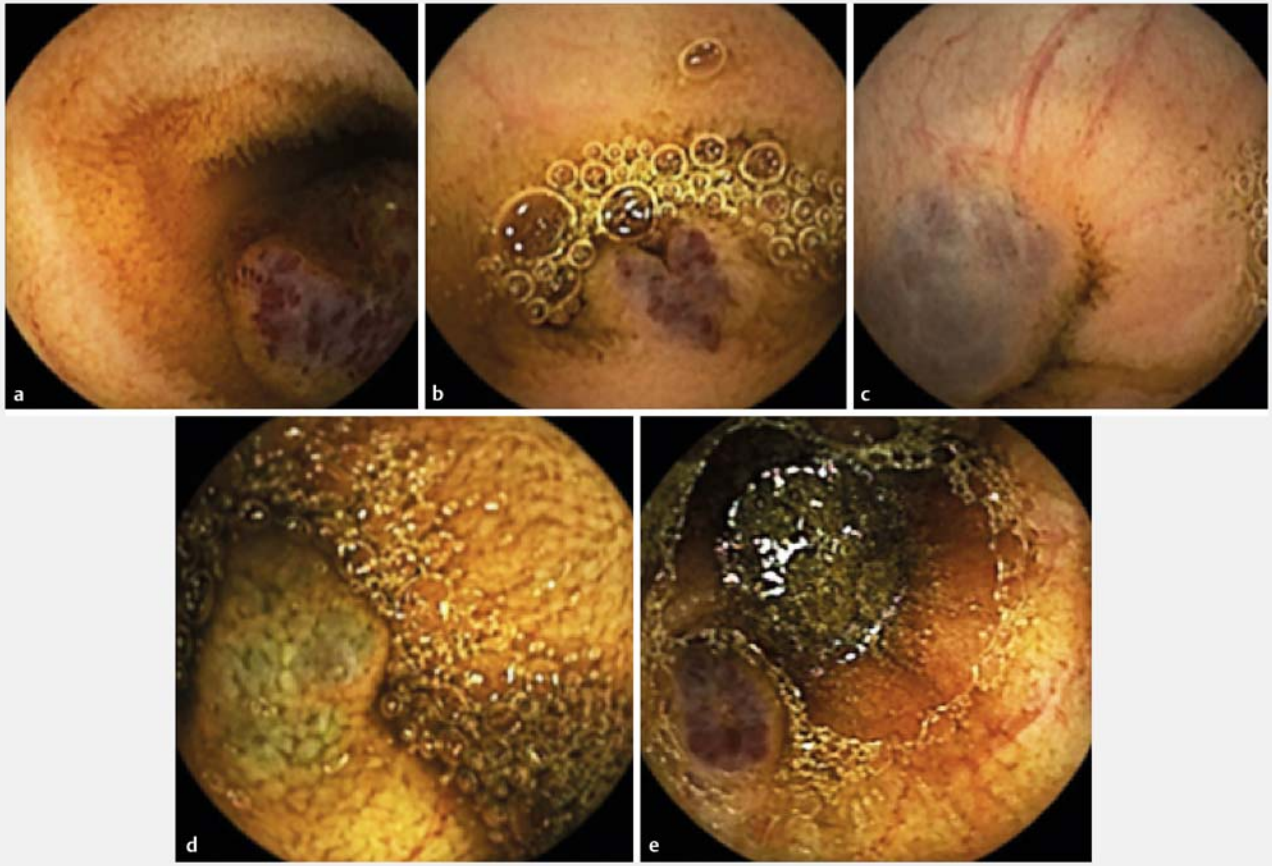
None



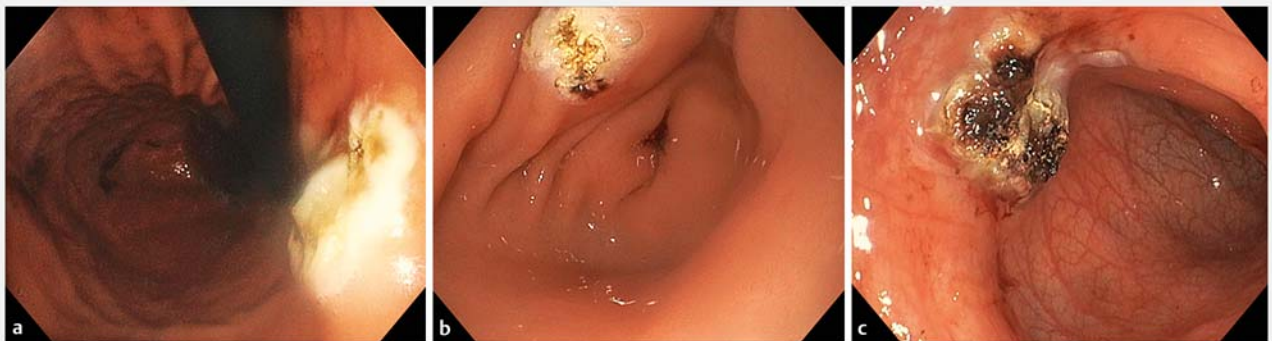► Video 1 Video capsule endoscopy diagnosis and double-balloon endoscopic sclerotherapy of gastrointestinal angiomas.



► Fig. 1 Endoscopic view of the angiomas. a Gastric antral lesion. b Gastric pre-pyloric lesion. c Colonic lesion.



► **Fig. 2** Capsule endoscopic views of angiomas in the small bowel.



► **Fig. 3** The lesions after treatment with argon plasma coagulation. **a** Gastric antral lesion. **b** Gastric pre-pyloric lesion. **c** Colonic lesion.

## The authors

**Maria Carolina Malafaia<sup>1</sup>, Sophie Heissat<sup>2</sup>, Philippe Jacob<sup>2</sup>, Catherine Le Gall<sup>2</sup>, Mathias Ruiz<sup>2</sup>, Jean-Christophe Saurin<sup>3</sup>, Mathieu Pioche<sup>3,4</sup>**

- 1 Department of General and Digestive Surgery, Professor Alberto Antunes University Hospital, Maceió, Alagoas, Brazil
- 2 Department of pediatric gastroenterology, Hospital Femme Mere Enfant, Lyon
- 3 Department of Endoscopy and Gastroenterology, Pavillon L, Edouard Herriot Hospital, Lyon, France
- 4 Inserm U1032 LabTau, Lyon, France

## Corresponding author

### Mathieu Pioche, MD

Endoscopy Unit – Digestive Disease Department, Pavillon L – Edouard Herriot Hospital, 69437 Lyon Cedex, France  
 Fax: +33-4-72110147  
 mathieu.pioche@chu-lyon.fr

## References

- [1] El Bakkaly A, Ettayebi F, Oubeja H et al. Bean's syndrome in children: about two cases. Article in French. *Pan Afr Med J* 2017; 28: 102
- [2] Arena M, Virdis M, Morandi E et al. Blue rubber bleb nevus syndrome: combined surgical and endoscopic treatment. *Endoscopy* 2015; 47 (Suppl. 01): E372 – E373
- [3] Jin XL, Wang ZH, Xiao XB et al. Blue rubber bleb nevus syndrome: a case report and literature review. *World J Gastroenterol* 2014; 20: 17254 – 17259
- [4] Tang X, Gao J, Yang X et al. A 10-year delayed diagnosis of blue rubber bleb nevus syndrome characterized by refractory iron-deficiency anemia: a case report and literature review. *Medicine (Baltimore)* 2018; 97: e10873

## Bibliography

**DOI** <https://doi.org/10.1055/a-0840-3214>  
 Published online: 12.2.2019  
*Endoscopy* 2019; 51: E98–E100  
 © Georg Thieme Verlag KG  
 Stuttgart · New York  
 ISSN 0013-726X

## ENDOSCOPY E-VIDEOS

<https://eref.thieme.de/e-videos>



*Endoscopy E-Videos* is a free access online section, reporting on interesting cases and new

techniques in gastroenterological endoscopy. All papers include a high quality video and all contributions are freely accessible online.

This section has its own submission website at

<https://mc.manuscriptcentral.com/e-videos>