

New Aspects in the Diagnosis and Therapy of Fetal Hypoplastic Left Heart Syndrome

Neue Aspekte in der Diagnostik und Therapie von Feten mit hypoplastischem Linksherzsyndrom



Authors

Oliver Graupner¹, Christian Enzensberger², Roland Axt-Fliedner²

Affiliations

- 1 Department of Obstetrics and Gynecology, University Hospital rechts der Isar, Technical University of Munich, Munich, Germany
- 2 Department of Obstetrics and Gynecology, Division of Prenatal Medicine, University Hospital UKGM, Justus-Liebig University, Giessen, Germany

Key words

fetal hypoplastic left heart syndrome, fetal cardiac function, fetal cardiac interventions

Schlüsselwörter

fetales hypoplastisches Linksherzsyndrom, fetale Herzfunktion, therapeutische Eingriffe am fetalen Herzen

received 29. 11. 2018

revised 29. 12. 2018

accepted 30. 12. 2018

Bibliography

DOI <https://doi.org/10.1055/a-0828-7968>
Geburtsh Frauenheilk 2019; 79: 863–872 © Georg Thieme Verlag KG Stuttgart · New York | ISSN 0016-5751

Correspondence

Prof. Roland Axt-Fliedner
Department of Obstetrics and Gynecology, Division of Prenatal Medicine & Fetal Therapy, University Hospital UKGM, Justus-Liebig University
Klinikstraße 33, 35385 Giessen, Germany
roland.axt-fliedner@gyn.med.uni-giessen.de

ABSTRACT

Fetal hypoplastic left heart syndrome (HLHS) is a severe congenital heart disease with a lethal prognosis without postnatal therapeutic intervention or surgery. The aim of this article is to give a brief overview of new findings in the field of prenatal

diagnosis and the therapy of HLHS. As cardiac output in HLHS children depends on the right ventricle (RV), prenatal assessment of fetal RV function is of interest to predict poor functional RV status before the RV becomes the systemic ventricle. Prenatal cardiac interventions such as fetal aortic valvuloplasty and non-invasive procedures such as maternal hyperoxygenation seem to be promising treatment options but will need to be evaluated with regard to long-term outcomes. Novel approaches such as stem cell therapy or neuroprotection provide important clues about the complexity of the disease. New aspects in diagnostics and therapy of HLHS show the potential of a targeted prenatal treatment planning. This could be used to optimize parental counseling as well as pre- and postnatal management of affected children.

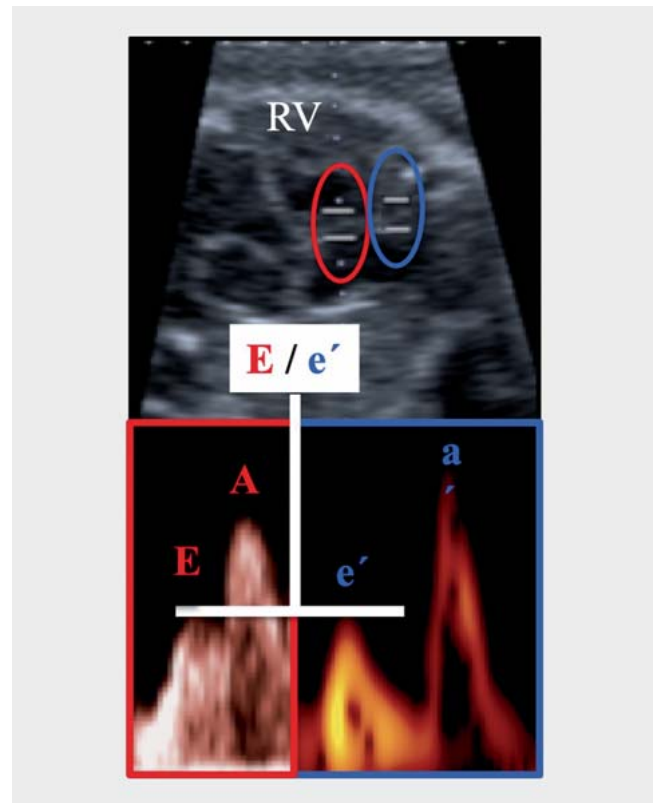
ZUSAMMENFASSUNG

Das hypoplastische Linksherzsyndrom (HLHS) ist eine schwerwiegende angeborene Herzerkrankung. Ohne postnatale therapeutische Intervention oder chirurgischen Eingriff ist die Prognose fatal. Dieser Artikel gibt einen kurzen Überblick über neue Erkenntnisse für die pränatale Diagnostik und Therapie von Feten mit HLHS. Da die Herzleistung bei Kindern mit HLHS von der rechten Herzkammer (RV) abhängt, liefert die vorgeburtliche Evaluierung der fetalen RV-Funktion wichtige Informationen zur Prognose einer RV-Dysfunktion, bevor der RV zum Systemventrikel wird. Pränatale Eingriffe am Herzen, wie z. B. die fetale Aorten-Valvuloplastie, sowie nicht-invasive Eingriffe, wie die mütterliche Hyperoxygenierung, sind vielversprechende Behandlungsoptionen. Allerdings müssen diese Ansätze im Hinblick auf die Langzeitergebnisse noch weiter evaluiert werden. Neue Ansätze wie die Stammzelltherapie oder Neuroprotektion liefern wichtige Hinweise für die Komplexität der Erkrankung. Neue Aspekte bei der Diagnostik und Therapie von HLHS weisen auf das Potenzial einer zielgerichteten Planung der vor- und nachgeburtlichen Behandlung hin. Dies könnte zur Optimierung der Elternberatung und des prä- und postnatalen Managements betroffener Kinder führen.

Introduction

Hypoplastic left heart syndrome (HLHS) is one of the most severe forms of congenital heart disease (CHD) diagnosed during pregnancy [1,2]. The incidence of HLHS is estimated to be 0.16 to 0.36 per 1000 live births and accounts for approximately 4.8–9% of all CHD [3–5]. HLHS involves cardiac anomalies with stenosis or atresia of the mitral and/or aortic valve leading to hypoplasia of the left ventricle and the ascending aorta [6,7]. Endocardial fibroelastosis (EFE) may be present, especially in cases with aortic valve stenosis. Without adequate postnatal treatment the prognosis is always lethal [7]. Postnatal therapeutic options include three staged surgical palliative procedures culminating in a Fontan procedure, hybrid management (a combination of surgery and cardiac catheterization), or heart transplantation. Although rare in this day and age, conservative compassionate care is still offered in extreme cases with a low probability of surviving interventions [8–12]. Other therapeutic approaches aim to address the causes of HLHS prenatally. One such approach is intrauterine balloon dilation of the aortic stenosis to promote left ventricular blood flow and prevent degeneration of the left ventricle [13]. Another, more recent, non-invasive prenatal approach is maternal hyperoxygenation (MH). Maternal inhalation of oxygen seems to increase the return of blood flow from fetal lungs towards the left atrium and consequently the left ventricle. In some cases, MH could have the potential to promote the growth of the underdeveloped left heart structures in fetuses with borderline left heart dimensions insufficient to support systemic circulation after birth [14]. However, the therapeutic benefits of MH in HLHS need to be validated in prospective studies.

Recent studies have shown changes in intrauterine cerebral perfusion, the intrauterine development of the central nervous system, and the psychomotor development of HLHS fetuses post partum, all of which affect the long-term neurological outcome [15–19]. The overall increase in the detection rates of CHD generally leads to an earlier diagnosis, with the possibility of planning targeted prenatal treatment. Advances in fetal echocardiography have contributed to a better understanding of the underlying pathophysiology. In addition to sonomorphology and blood flow assessment, interest has increasingly begun to focus on the study of cardiac function, in particular of the right ventricle, in HLHS fetuses [20–25]. Prenatal changes in right ventricular function may be crucial for the future functioning of the single ventricle, as postnatal right ventricular dysfunction is an important risk factor which affects the survival of HLHS children during multi-stage surgery [26,27]. Advances in perioperative care and the development of novel surgical techniques have led to a reduction in HLHS mortality, improving the prognosis of affected children [28–31]. The purpose of this brief review is to present an overview of the existing literature, especially with regard to novel prenatal diagnostic methods which offer better estimates of prognosis and new pre- and postnatal therapeutic approaches.



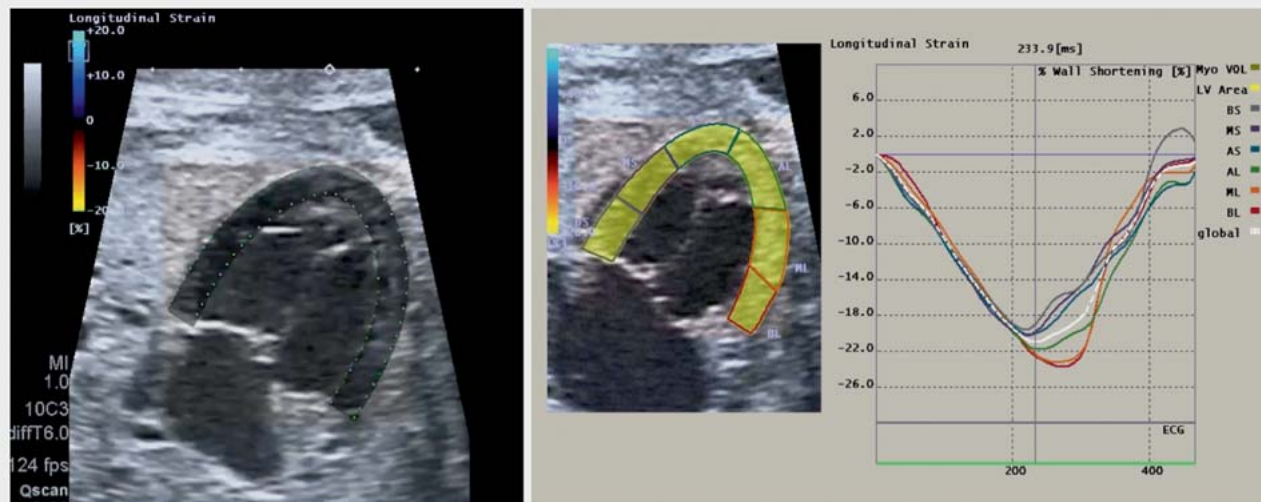► **Fig. 1** Schematic illustration of the right ventricular (RV) E/e' ratio in a healthy fetus. E and A (red): blood flow Doppler (PW = pulsed wave)-derived peak velocity during early (E) and late (A) diastole. The sample volume is shown over the tricuspid valve (in red). e' and a' (blue): tissue Doppler (PW-TDI = pulsed wave tissue Doppler imaging)-derived peak velocity during early (e') and late (a') diastole. The sample volume is shown in the tricuspid annulus (in blue).

Review

Novel aspects in the diagnosis of HLHS

In HLHS children, cardiac output depends on the right ventricle (RV). Postnatally, single ventricle circulation using the RV can be achieved by different surgical procedures. Intrauterine changes in RV function may have a decisive effect on diastolic and systolic function of the future single ventricle. Postnatal RV dysfunction is consequently an important risk factor affecting the survival of HLHS children [32]. The prenatal examination of RV function in HLHS is therefore a focus of scientific interest.

In a retrospective study of 48 HLHS fetuses, Brooks et al. examined RV function in these fetuses compared to normal control fetuses, using speckle tracking echocardiography. Brooks and colleagues reported a decrease in longitudinal deformation in relation to the deformation of the circumferential axis of the RV in HLHS fetuses. As the diameter increased, the RV also increased and its shape became spherical, indicating that in fetal HLHS, RV remodeling already occurs prenatally [21].



► **Fig. 2** Apical four chamber view of a hypoplastic left heart syndrome (HLHS) fetus (mitral atresia/aortic atresia) at 26 + 5 weeks of gestation. Left: Traced myocardial wall of the right ventricle (RV) and interventricular septum for myocardial deformation analysis (strain) using 2D speckle tracking echocardiography. Right: Curves for RV and septal longitudinal peak systolic strain (%) of six segments of the myocardial wall and global strain (%) for one fetal heart cycle. BL: basal lateral, ML: middle lateral, AL: apical lateral, AS: apical septal, MS: middle septal, BS: basal septal. High values for RV global strain can be interpreted as a sign of RV remodeling leading to an adaptation of myocardial function to left ventricular conditions.

In a retrospective study of 84 HLHS fetuses using blood flow and tissue Doppler techniques, Natarajan et al. observed significantly elevated values with regard to the RV Tei index or myocardial performance index (MPI), a parameter of global ventricular function [33], with the values pointing to RV dysfunction in HLHS fetuses [20]. Moreover, the E/e' ratio used in adult echocardiography to record ventricular filling pressures showed elevated values in the HLHS group compared to healthy control fetuses [20]. This ratio is the ratio of blood flow velocity during early diastolic passive filling of the RV (E) and early diastolic myocardial relaxation rate in the region of the RV ventricular wall (e'). The higher the E/e' ratio (► **Fig. 1**), the greater the blood flow velocity in relation to myocardial movement, which in turn indicates an increased atrial pressure gradient and reduced relaxation capacity or compliance of the fetal myocardium [34].

Our own work which analyzed RV function in HLHS fetuses revealed that HLHS fetuses show detectable changes, particularly with regard to RV diastolic function [23, 24]. In line with the results of Natarajan et al., increased values were observed for the E/e' ratio of the HLHS group, indicating reduced compliance of the RV myocardium [23]. Subgroup analysis additionally revealed that HLHS fetuses with additional left ventricular EFE (which indicates endocardial thickening due to increased incorporation of collagen and elastin fibers) showed signs of both systolic and diastolic dysfunction [25]. The use of 2D speckle tracking echocardiography to analyze RV myocardial deformation revealed significantly higher mean values for global longitudinal peak systolic strain in HLHS fetuses compared to fetuses with normal-sized left ventricles (-16.22% vs. -12.31%) (► **Fig. 2**) [35]. This can be understood as a sign of RV remodeling in HLHS which leads to an adaptation of myocardial function to left ventricular conditions.

Postnatally, the RV function of HLHS infants was examined before and after surgery. Petko et al. used speckle tracking techniques to record RV deformation data obtained before and after a Norwood procedure performed in HLHS children. They reported a significant decrease in strain and strain rates after surgery [36]. Altmann et al. aimed to determine the mortality rate of HLHS children based on RV function. They demonstrated that RV function measured before surgery had no effect on the survival rate after a Norwood procedure. However, a follow-up of survivors after stage I revealed that infants with RV dysfunction before stage II had a significantly higher mortality rate. Survival at 18 months after Norwood surgery was 93% for patients with initially normal RV function compared to 47% for those with abnormal RV function. The relative risk of later mortality was approximately 11 times higher in patients with initial RV dysfunction [27]. In contrast, a recently published work showed a significant association between RV function before and after stage I of the Norwood operation. Zaidi et al. observed a significant reduction in echocardiographic functional parameters after surgery as well as a correlation with the length of hospital stay, the need for extracorporeal membrane oxygenation, and the mortality rate of HLHS children [37, 38].

Prenatal cardiac interventions and maternal hyperoxygenation in HLHS

As fetal aortic stenosis may progress to hypoplastic left heart syndrome before birth and require univentricular palliation post partum, fetal valvuloplasty has been proposed to improve left ventricular (LV) hemodynamics, possibly maintaining biventricular circulation [39–41]. In a retrospective multicenter study, Kovacevic et al. compared 67 fetuses with aortic stenosis who underwent fetal valvuloplasty between 2005 and 2012 with cases sharing similar characteristics at presentation but who did not under-

go prenatal cardiac intervention. They reported a procedure-related mortality of 10%. Inverse probability of treatment weighting demonstrated an improved survival of liveborn infants following prenatal cardiac intervention (HR: 0.38; 95% CI, 0.23–0.64; $p = 0.0001$) after adjusting for circulation and the postnatal surgical center. However, the figures for biventricular circulation were similar (36% in the fetal valvuloplasty group and 38% in the group without intervention), and survival was similar for final circulations. Cases of successful fetal valvuloplasty showed an improved hemodynamic response with better preservation of LV growth compared to fetuses without prenatal cardiac intervention [42]. The International Fetal Cardiac Intervention Registry (IFCIR) analyzed data on fetal valvuloplasty from 18 participating institutions. In 86 fetuses operated on between 2001 and 2014, 70 aortic valvuloplasty procedures (81%) were technically successful, and of those, 24 (32%) had a biventricular circulation [41].

The impact of fetal valvuloplasty on fetal cardiac function and postnatal outcome has also been studied [43,44]. Ishii et al. evaluated LV strain rates after aortic valvuloplasty in fetuses with aortic stenosis and incipient HLHS. Tissue deformation rates were analyzed both before and after the procedure, and postnatal outcomes were investigated with regard to whether valvuloplasty could induce biventricular circulation of the heart post partum. Out of a total of 57 treated fetuses, 23 fetuses had biventricular and 34 fetuses had univentricular circulation. Fetuses with a biventricular outcome showed higher values of LV strain rate compared to fetuses with a univentricular outcome [44].

Between 6–11% of cases diagnosed prenatally with HLHS have a severely restricted foramen ovale or an intact interatrial septum (IAS) [45,46]. In these cases, HLHS is already often established and there is no potential for biventricular circulation [47]. Detecting IAS is very important for the postnatal survival of HLHS infants. Among other findings, the postnatal survival of HLHS infants relies on unimpeded pulmonary vein flow across the atrial septum [45,48–50]. Fetal atrial septoplasty, sometimes combined with stenting of the atrial septum, is considered to offer multiple benefits [47]. The IFCIR reported on septoplasty in 37 HLHS fetuses with IAS. In 24 cases (65%), septoplasty was technically successful. However, no differences with regard to overall survival or hospital discharge were observed between the intervention group and fetuses who did not have fetal cardiac intervention [41]. Marshall et al. described the outcome of 21 HLHS fetuses with IAS who underwent atrial septoplasty in a single-center study. 19/21 interventions resulted in successful atrial communication; in the group of successful interventions, an atrial communication ≥ 3 mm was found to be correlated with higher postnatal oxygen saturation and lower rates of emergent atrial septoplasty. Finally, surgical survival rates were better for infants who did not need emergent atrial septoplasty (86 vs. 42%) without statistical significance [51].

Maternal hyperoxygenation (MH) therapy consists of providing supplemental oxygen to the mother during pregnancy to improve the cardiovascular hemodynamics of the fetus. The effect of MH is due to the increase in fetal pulmonary blood flow, which results in increased venous return to the left heart. This effect becomes more apparent with increasing gestational age [49,52]. In a systematic review, Co-Vu et al. analyzed the efficacy, safety, out-

comes, and intrauterine complications following MH therapy in fetuses with congenital heart disease, using nine articles out of a total of 96 which met the inclusion criteria [53]. Fetuses included in the study were predominantly diagnosed with LV structural hypoplasia. There are a number of different MH protocols, and currently only studies or case series with small sample sizes are available. Our group has published a study on the use of MH. At the time of intervention, the fetuses had a gestational age of more than 26 weeks. The study investigated pulmonary vasoreactivity, using vascular Doppler to assess 20 HLHS fetuses. We used 100% oxygen with a flow of 8 L for 10 minutes administered through a non-rebreather face mask, resulting in a fraction of inspired oxygen (FiO_2) of 60%. A pulmonary Doppler examination was also performed, with the mother breathing room air for 10 minutes after MH [54]. In a recent pilot study, Lara et al. reported on the use of MH in 9 fetuses with left heart hypoplasia and a mean gestational age of 29.6 weeks. The daily goal was to administer ≥ 8 h oxygen at 8–9 L/min 100% FiO_2 until delivery. Maternal arterial partial pressure of oxygen (PaO_2) was measured after 1 h of 8 L/min O_2 . If PaO_2 was less than 250 mmHg O_2 , flow was increased to 9 L/min. Mothers were sent home with an oxygen condenser and non-rebreather mask and encouraged to continue with MH therapy as long as possible every day [52]. A growth of hypoplastic left heart structures was observed after MH [14,49,55,56]. MH has been shown to be a useful tool to improve risk stratification in HLHS fetuses with IAS or atrial septal aneurysm [49,57–59]. No significant adverse fetal, maternal and neonatal events have been reported, especially with regard to any preterm constriction of the ductus arteriosus, postnatal pulmonary hypertension or retinopathy [53]. However, to date, there are no data on the long-term outcome of affected HLHS fetuses undergoing MH therapy, particularly with regard to possible detrimental effects on fetal circulation in terms of fetal programming.

Established and novel postnatal therapies for HLHS

Surgical treatment of HLHS consists of three staged palliative procedures, culminating in a Fontan circulation. In addition to a Norwood procedure requiring cardiopulmonary bypass and sometimes deep hypothermic cerebral perfusion, Gibbs et al. introduced a so-called hybrid procedure in 1993 [12,60]. The rationale for the hybrid procedure was to avoid cardiopulmonary bypass in high-risk patients such as infants with low birth weight or prematurity and to thereby reduce the surgical morbidity and mortality rates [60]. Akintuerk et al. and Galantowicz et al. demonstrated the feasibility of the hybrid technique [61,62]. To prevent pulmonary flooding, blood flow into the lungs is restricted by narrowing the pulmonary arteries (bilateral pulmonary artery banding) during the first days of life. In a second step, interventional cardiac catheterization is used to place a stent in the ductus arteriosus to keep it open. In addition to the fact that the procedure is carried out under beating heart conditions, another advantage of this strategy is that complex reconstruction of the aorta is not performed immediately after birth but only at the age of 4–6 months. Single-center studies comparing both procedures demonstrated no significant differences in surgical outcomes between the two techniques [63–66]. Due to the small cohort sizes, Cao et al. carried out a meta-analysis to compare hybrid and Norwood proce-

dures [67]. Fourteen studies comprising 263 hybrid and 426 Norwood patients met the inclusion criteria for statistical analysis. Cao and colleagues reported significantly higher early mortality rates in the hybrid procedure group (21 vs. 18%, RR = 1.54, $p < 0.05$, 95% CI: 1.02–2.34), although interstage mortality of the two groups was comparable (26 vs. 29%, RR = 0.88, $p > 0.05$, 95% CI: 0.46–1.70). The six-month and one-year transplant-free survival rate for the hybrid procedure group was also significantly worse compared to the Norwood procedure group (hybrid: 72 and 64%, RR = 0.89, $p < 0.05$, 95% CI: 0.80–1.00; Norwood: 77 and 70%, RR = 0.88, $p < 0.05$, 95% CI: 0.78–1.00). The rate of reinterventions following initial surgical palliation was higher in the hybrid procedure group (RR = 1.48, $p < 0.05$, 95% CI: 1.09–2.01), although the duration of hospital stay and the length of time spent in the intensive care unit after surgery was comparable between the two groups. The authors concluded that the hybrid procedure had inferior early survival rates compared to the Norwood procedure during the period of initial palliative treatment of infants with HLHS. However, since the hybrid procedure is performed primarily in high-risk patients, the significance of this difference is limited. It is also worth pointing out that several of the 95% CI's include 1, indicating they are probably not truly different. In a retrospective outcome study, Schranz et al. reported on the 15-year experience of a single institution in a cohort of 154 patients with hypoplastic left heart syndrome who underwent a "Giessen hybrid" stage I procedure as initial palliation. The 15-year survival rate for HLHS and variants was 77%, and a birth weight of less than 2.5 kg had no significant impact. This underlines the fact that prematurity and low birth weight are well-known risk factors after Norwood palliation but not after hybrid procedures [30, 68, 69]. Yerebakan et al. reported on the long-term results of patients ($n = 40$) who received biventricular correction (BVC) after an initial Giessen hybrid stage I approach. Patients were treated with direct BVC. Median survival time after BVC was 7.9 years (0.9–14.9). Overall mortality was 10% (4 patients) at 4 weeks, 5 weeks, 6 weeks, and 4 months after BVC, respectively. The authors concluded that BVC after hybrid stage I is feasible with satisfactory long-term survival rates [69]. To evaluate potential differences in RV function and pulmonary artery dimensions after Norwood ($n = 42$) or hybrid ($n = 44$) procedures, Latus et al. used cardiac magnetic resonance imaging in survivors with HLHS. Both techniques had an equivalent preserved global RV pump function ($59 \pm 9\%$ vs. $59 \pm 10\%$, $p = 0.91$), but development of the pulmonary arteries (lower lobe index: 135 ± 74 vs. 161 ± 62 mm²/m², $p = 0.02$) and the reintervention rate were better after the Norwood approach. RV myocardial deformation (strain and strain rate) as a potential marker of early RV dysfunction was observed in the hybrid group with a potential impact on the long-term outcome in this cohort [70].

Even after successful completion of surgical palliation, significant morbidity occurs due to progressive RV dysfunction [71]. HLHS patients with RV dysfunction after a Norwood procedure have an 18-month survival rate of 35% compared with a 70% survival rate for patients with normal RV function [27]. Moreover, one third of HLHS patients die by the age of 25 years from end-stage RV failure [72]. The ultimate solution for heart failure is heart transplantation, but patients must cope with long-term immuno-

suppression and the risk of transplant failure. Novel therapies to manage RV dysfunction in HLHS patients are therefore needed. Stem cell therapy has the potential to be an innovative therapeutic approach. Multiple pathways play an important role in the development of RV dysfunction which can originate from cardiomyocyte hypertrophy, increased angiogenesis with the production of antioxidative enzymes, and a change in fetal gene expression [73, 74]. The RV of HLHS patients has a limited angiogenic response to pressure overload [75]. This reduces the supply of oxygen and nutrients to cardiomyocytes, leading to myocardial dysfunction [76]. Different stem cell types are used in cell therapy, especially in the regenerative therapy of ischemic heart disease [77]. It is believed that stem cells are present in the perivascular regions of various tissue types including the myocardium. Because of their intrinsic properties, they are able to secrete different angiogenic factors [78] which can increase myocardial angiogenesis, replace injured myocardium and improve myocardial function [79]. Clinical trials for stem cell therapy in CHD are mostly carried out in patients with single ventricle circulation, as can occur with HLHS. Published ongoing studies use different stem cell types, evaluate different patient populations, and differ in the route of stem cell administration [71, 80–84]. However, all have the same goal, namely to improve RV performance [71]. Ishigami et al. reported on the first phase I clinical trial (TICAP trial: transcatheter infusion of cardiac progenitor cells in patients with single ventricle physiology, NCT01273857) [80]. The study population included 14 children with HLHS, of whom 7 underwent transcatheter infusion of cardiosphere-derived cells (CDCs) 4 to 5 weeks after stage II or III palliative surgery. The other 7 HLHS children received standard care only and served as the control group. No adverse events from the procedure (including tumor formation) were reported, with a follow-up of 36 months after CDC infusion. Furthermore, the CDC-treated patients demonstrated an improvement in RV function. Echocardiography showed a significantly greater improvement in RV ejection fraction in patients receiving CDCs than in controls at 36 months ($+ 8.0 \pm 4.7\%$ vs. $+ 2.2 \pm 4.3\%$; $p = 0.03$). In addition, improvements in RV function resulted in lower brain natriuretic peptide levels ($p = 0.04$), a lower incidence of unplanned catheter interventions ($p = 0.04$), and a higher weight-for-age z-score ($p = 0.02$) at 36 months relative to controls [81]. This demonstrates the therapeutic potential of stem cell therapy to improve cardiac function in single ventricle patients.

In this context, the results from Boston Children's hospital on the prenatal inhibition of EFE are worth mentioning. Prenatal EFE is known to be a compromising factor for long-term ventricular function in HLHS patients [85, 86]. Xu et al. demonstrated that fibrogenic cells in EFE tissue originate from endocardial endothelial cells via aberrant endothelial-to-mesenchymal transition (EndMT). This aberrant EndMT involving endocardial endothelial cells is caused by dysregulated TGF β /BMP signaling [86]. Supplementation with exogenous recombinant BMP7 (bone morphogenetic protein 7) ameliorated EndMT in an experimental EFE model [85, 86]. BMP7 activates the BMP pathway by binding to bone morphogenetic protein receptors (BMPR). Activating SMAD1/5/8, the myogenic regulators of murine and human mesoangioblasts [87], can block EndMT-inducing signals and help maintain endothelial cell characteristics [86]. These promising new insights may pro-

vide useful pointers for pharmacological interventions and prenatal therapies to prevent EFE in HLHS fetuses.

Cerebroplacental hemodynamics and neurological outcomes in HLHS

Fetuses with severe forms of CHD are at high risk of impaired neurodevelopmental outcomes in later childhood [88, 89]. A significant proportion of CHD children are reported to have neurological abnormalities even before undergoing postnatal surgery [90]. Masoller et al. reported that CHD fetuses had a reduced head circumference and a higher rate of cerebral redistribution in the second trimester of pregnancy [91]. Our own work has revealed that the head circumference of fetuses with low placental blood content and therefore low levels of oxygen delivery to the brain (as occurs with severe left heart obstruction) decreases during gestation depending on the direction of aortic arch flow [92]. Furthermore, a high percentage of CHD infants show cerebral abnormalities on magnetic resonance imaging and have a smaller head size and brain volume [93–96]. Kuhn et al. examined the impact of surgical and therapeutic risk factors on pre- and postoperative brain MRI findings in 48 neonates with complex CHD (HLHS and dextro-transposition of the great arteries) using a brain injury score. The preoperative brain MRI was abnormal in 27 of 48 neonates (56%) with no significant differences between the two groups with regard to the total injury score ($p = 0.47$) [97]. This led to a supposition that the pathological processes had a prenatal origin, leading to poor later neurodevelopment in CHD patients. Changes in the cerebroplacental hemodynamics of CHD fetuses may have an impact on neurodevelopmental abnormalities. For example, lower values for the middle cerebral artery (MCA) pulsatility index (PI) have been reported for HLHS fetuses [98–102], particularly in the third trimester [103]. Cerebral vasodilatation generally reflects fetal adaptation to hypoxia, which suggests that all of the differences observed in CHD patients may be secondary to reduced cerebral oxygen delivery [104, 105]. As MH has been shown to increase fetal partial pressure of oxygen in the umbilical artery and vein as well as umbilical arterial oxygen saturation [106–109], Szwasz et al. hypothesized that MH may have a neuroprotective function as it increases cerebral oxygen delivery by increasing the partial pressure of oxygen in the fetus. Szwasz et al. observed a first increase of MCA-PI in response to MH at ≥ 28 weeks of gestation in 43 HLHS fetuses. A baseline MCA-PI z-score of less than -0.96 was predictive of an increase in cerebrovascular resistance in response to MH [110]. However, Edwards et al. reported relatively diminished fetal biparietal diameter growth and smaller infant head circumference z-scores at 6 months in fetuses with left heart hypoplasia and in utero MH exposure. No differences between controls (left heart hypoplasia without MH exposure in utero) and children exposed to MH in utero were observed during neurodevelopmental testing at 6 and 12 months [111]. These results may provide an impetus to conduct more randomized clinical trials with larger case series and postnatal follow-up to achieve a better understanding of MH as a useful neuroprotective tool in HLHS fetuses. However, it should be mentioned again that the potential negative effects of MH must be investigated in prospective studies with large sample sizes to determine the value of MH to treat HLHS.

Main advances in the diagnosis, therapy and care of HLHS patients

Approximately one-third of live-born newborns with HLHS die before undergoing surgical intervention [112]. This comparatively high mortality rate is due, in the main, to delayed postnatal diagnosis and the associated hemodynamic instability. Prenatal diagnosis improves planning, as infants can be delivered close to or in specialized pediatric heart centers which reduces preoperative morbidity and mortality rates of HLHS neonates [112–114]. Prenatal diagnosis also has a positive impact on the preoperative state (lowest pH value, need for vasoactive drugs etc.) [115]. Surgery-related mortality rates of HLHS neonates undergoing a Norwood procedure continue to decline [116, 117]. Survival rates of more than 95% following HLHS stage 1 palliation have been reported for selected centers [118]. Advances in surgical techniques in the last decades have resulted in four viable options for the long-term survival of HLHS patients: the Norwood procedure, the “true” hybrid approach, a hybrid bridge-to-Norwood approach, and cardiac transplantation [119]. However, due to their single ventricle physiology, HLHS children have a high risk of mortality in the interstage period, i.e., the period between their discharge home after stage 1 palliation until stage 2 palliation at 4 to 6 months. Interstage mortality rates reported for single centers are between 10 and 18.9% [120–123]. Novel management strategies such as interstage home surveillance monitoring (HSM) have been developed to cope with this problem. HSM models are multidisciplinary programs which provide focused parental education before patients are discharged home after palliation. HSM programs include home weight checks, oxygen saturation monitoring and educating parents to recognize specific symptoms indicating potential cardiopulmonary or nutritional decompensation [124]. Ghanayem and colleagues reported that interstage mortality dropped from 15.8 to 0% in 24 HLHS patients after an HSM model was implemented [125]. In their 10-year experience with interstage HSM, they reported a 98% interstage survival rate [126]. HSM represents a promising approach for the care of HLHS patients.

Conclusion

As cardiac output depends on the right ventricle in HLHS children, prenatal assessment of fetal RV function is of interest to predict poor functional status of the RV before becoming systemic ventricle. Prenatal cardiac interventions like fetal aortic valvuloplasty and non-invasive procedures like maternal hyperoxygenation seem to be promising treatment options, which however have to be evaluated with regard to long-term outcome. Novel approaches such as stem cell therapy or neuroprotection in HLHS provide important clues for the complexity of the disease. New aspects in diagnostics and therapy of HLHS show the potential of a targeted prenatal treatment planning. This could be used to optimize parental counseling as well as pre- and postnatal management of affected children.

Conflict of Interest

The authors declare that they have no conflict of interest.

References

- [1] Allan LD, Sharland GK, Milburn A et al. Prospective diagnosis of 1,006 consecutive cases of congenital heart disease in the fetus. *J Am Coll Cardiol* 1994; 23: 1452–1458
- [2] Hoffman JL. Incidence of congenital heart disease: II. Prenatal incidence. *Pediatr Cardiol* 1995; 16: 155–165
- [3] Ferencz C, Rubin JD, McCarter RJ et al. Congenital heart disease: prevalence at livebirth. The Baltimore-Washington Infant Study. *Am J Epidemiol* 1985; 121: 31–36
- [4] Fyler DC, Buckley LP, Hellenbrand WE et al. Report of the New England Regional Infant Cardiac care Program. *Pediatrics* 1980; 65: 375–461
- [5] Hoffman JL, Kaplan S. The incidence of congenital heart disease. *J Am Coll Cardiol* 2002; 39: 1890–1900
- [6] Allan LD, Anderson RH, Cook AC. Atresia or absence of the left-sided atrioventricular connection in the fetus: echocardiographic diagnosis and outcome. *Ultrasound Obstet Gynecol* 1996; 8: 295–302
- [7] Axt-Flidner R, Enzensberger C, Fass N et al. Fetal diagnosis of hypoplastic left heart, associations and outcomes in the current era. *Ultraschall Med* 2012; 33: E51–E56
- [8] Akintürk H, Michel-Behnke I, Valeske K et al. Hybrid transcatheter-surgical palliation: basis for univentricular or biventricular repair: the Giessen experience. *Pediatr Cardiol* 2007; 28: 79–87
- [9] Chrisant MR, Naftel DC, Drummond-Webb J et al. Fate of infants with hypoplastic left heart syndrome listed for cardiac transplantation: a multi-center study. *J Heart Lung Transplant* 2005; 24: 576–582
- [10] Karamlou T, Diggs BS, Ungerleider RM et al. Evolution of treatment options and outcomes for hypoplastic left heart syndrome over an 18-year period. *J Thorac Cardiovasc Surg* 2010; 139: 119–126
- [11] Murtuza B, Elliott MJ. Changing attitudes to the management of hypoplastic left heart syndrome: a European perspective. *Cardiol Young* 2011; 21 (Suppl. 2): 148–158
- [12] Norwood WI, Lang P, Hansen DD. Physiologic repair of aortic atresia-hypoplastic left heart syndrome. *N Engl J Med* 1983; 308: 23–26
- [13] Tworetzky W. Balloon Dilation of Severe Aortic Stenosis in the Fetus: Potential for Prevention of Hypoplastic Left Heart Syndrome: Candidate Selection, Technique, and Results of Successful Intervention. *Circulation* 2004; 110: 2125–2131
- [14] Kohl T. Chronic Intermittent Materno-Fetal Hyperoxygenation in Late Gestation May Improve on Hypoplastic Cardiovascular Structures Associated with Cardiac Malformations in Human Fetuses. *Pediatr Cardiol* 2010; 31: 250–263
- [15] Donofrio MT, Bremer YA, Schieken RM et al. Autoregulation of cerebral blood flow in fetuses with congenital heart disease: the brain sparing effect. *Pediatr Cardiol* 2003; 24: 436–443
- [16] Goldberg CS, Schwartz EM, Brunberg JA et al. Neurodevelopmental outcome of patients after the fontan operation: A comparison between children with hypoplastic left heart syndrome and other functional single ventricle lesions. *J Pediatr* 2000; 137: 646–652
- [17] Kaltman JR, Di H, Tian Z et al. Impact of congenital heart disease on cerebrovascular blood flow dynamics in the fetus. *Ultrasound Obstet Gynecol* 2005; 25: 32–36
- [18] Miller SP, McQuillen PS, Hamrick S et al. Abnormal brain development in newborns with congenital heart disease. *N Engl J Med* 2007; 357: 1928–1938
- [19] Sarajuuri A, Jokinen E, Puosi R et al. Neurodevelopment in children with hypoplastic left heart syndrome. *J Pediatr* 2010; 157: 414–420
- [20] Natarajan S, Szwast A, Tian Z et al. Right ventricular mechanics in the fetus with hypoplastic left heart syndrome. *J Am Soc Echocardiogr* 2013; 26: 515–520
- [21] Brooks PA, Khoo NS, Mackie AS et al. Right ventricular function in fetal hypoplastic left heart syndrome. *J Am Soc Echocardiogr* 2012; 25: 1068–1074
- [22] Szwast A, Tian Z, McCann M et al. Right ventricular performance in the fetus with hypoplastic left heart syndrome. *Ann Thorac Surg* 2009; 87: 1214–1219
- [23] Axt-Flidner R, Graupner O, Degenhardt J et al. Evaluation of right ventricular function in the fetus with hypoplastic left heart using tissue Doppler techniques. *Ultrasound Obstet Gynecol* 2014; 45: 670–677
- [24] Graupner O, Enzensberger C, Wieg L et al. Evaluation of right ventricular function in fetal hypoplastic left heart syndrome by color tissue Doppler imaging. *Ultrasound Obstet Gynecol* 2016; 47: 732–738
- [25] Graupner O, Enzensberger C, Wieg L et al. Endocardial fibroelastosis of the left ventricle affects right ventricular performance in fetuses with hypoplastic left heart syndrome: A prospective study using M-Mode, PW- and Tissue Doppler techniques. *Ultraschall Med* 2018; 39: 413–421
- [26] Rychik J. Hypoplastic Left Heart Syndrome. In: Rychik J, Tian Z, eds. *Fetal Cardiovascular Imaging: a Disease based Approach*. Philadelphia: Elsevier Saunders; 2012: 231–241
- [27] Altmann K, Printz BF, Solowiejczyk DE et al. Two-dimensional echocardiographic assessment of right ventricular function as a predictor of outcome in hypoplastic left heart syndrome. *Am J Cardiol* 2000; 86: 964–968
- [28] Axt-Flidner R, Kreiselmair P, Schwarze A et al. Development of hypoplastic left heart syndrome after diagnosis of aortic stenosis in the first trimester by early echocardiography. *Ultrasound Obstet Gynecol* 2006; 28: 106–109
- [29] Enzensberger C, Vogel M, Degenhardt J et al. Fetal pulmonary venous flow and restrictive foramen ovale in hypoplastic left heart. *Ultraschall Med* 2012; 33: E38–E45
- [30] Furck AK, Uebing A, Hansen JH et al. Outcome of the Norwood operation in patients with hypoplastic left heart syndrome: a 12-year single-center survey. *J Thorac Cardiovasc Surg* 2010; 139: 359–365
- [31] Hartge DR, Weichert J, Krapp M et al. Results of early foetal echocardiography and cumulative detection rate of congenital heart disease. *Cardiol Young* 2011; 21: 505–517
- [32] Khairy P, Fernandes SM, Mayer JE jr. et al. Long-term survival, modes of death, and predictors of mortality in patients with Fontan surgery. *Circulation* 2008; 117: 85–92
- [33] Tei C, Nishimura RA, Seward JB et al. Noninvasive Doppler-derived myocardial performance index: correlation with simultaneous measurements of cardiac catheterization measurements. *J Am Soc Echocardiogr* 1997; 10: 169–178
- [34] Aoki M, Harada K, Ogawa M et al. Quantitative assessment of right ventricular function using doppler tissue imaging in fetuses with and without heart failure. *J Am Soc Echocardiogr* 2004; 17: 28–35
- [35] Enzensberger C, Fischer S, Graupner O et al. Evaluation of right ventricular myocardial contraction in fetuses with Hypoplastic Left Heart using 2D Speckle Tracking technique. *Ultrasound Obstet Gynecol* 2018; 52 (Suppl. 1): 66–137
- [36] Petko C, Uebing A, Furck A et al. Changes of right ventricular function and longitudinal deformation in children with hypoplastic left heart syndrome before and after the Norwood operation. *J Am Soc Echocardiogr* 2011; 24: 1226–1232
- [37] Zaidi SJ, Lefaiver CA, Muangmingsuk S et al. Right Ventricular Longitudinal Shortening Before and After Stage I Surgical Palliation Correlates with Outcomes. *Pediatr Cardiol* 2018; 39: 526–532
- [38] Zaidi SJ, Penk J, Cui VW et al. Right Ventricular Systolic Function Parameters in Hypoplastic Left Heart Syndrome. *Pediatr Cardiol* 2018. doi:10.1007/s00246-018-1912-x
- [39] Arzt W, Wertaschnigg D, Veit I et al. Intrauterine aortic valvuloplasty in fetuses with critical aortic stenosis: experience and results of 24 procedures. *Ultrasound Obstet Gynecol* 2011; 37: 689–695

- [40] McElhinney DB, Marshall AC, Wilkins-Haug LE et al. Predictors of technical success and postnatal biventricular outcome after in utero aortic valvuloplasty for aortic stenosis with evolving hypoplastic left heart syndrome. *Circulation* 2009; 120: 1482–1490
- [41] Moon-Grady AJ, Morris SA, Belfort M et al. International Fetal Cardiac Intervention Registry: a worldwide collaborative description and preliminary outcomes. *J Am Coll Cardiol* 2015; 66: 388–399
- [42] Kovacevic A, Öhman A, Tulzer G et al. Fetal hemodynamic response to aortic valvuloplasty and postnatal outcome: a European multicenter study. *Ultrasound Obstet Gynecol* 2018; 52: 221–229
- [43] Wohlmuth C, Wertaschnigg D, Wieser I et al. Tissue Doppler imaging in fetuses with aortic stenosis and evolving hypoplastic left heart syndrome before and after fetal aortic valvuloplasty. *Ultrasound Obstet Gynecol* 2016; 47: 608–615
- [44] Ishii T, McElhinney DB, Harrild DM et al. Ventricular strain in fetuses with aortic stenosis and evolving hypoplastic left heart syndrome before and after prenatal aortic valvuloplasty. *Fetal Diagn Ther* 2014; 35: 18–26
- [45] Rychik J, Rome JJ, Collins MH et al. The hypoplastic left heart syndrome with intact atrial septum: atrial morphology, pulmonary vascular histopathology and outcome. *J Am Coll Cardiol* 1999; 34: 554–560
- [46] Vlahos AP. Hypoplastic Left Heart Syndrome With Intact or Highly Restrictive Atrial Septum: Outcome After Neonatal Transcatheter Atrial Septostomy. *Circulation* 2004; 109: 2326–2330
- [47] Schidlow DN, Freud L, Friedman K et al. Fetal interventions for structural heart disease. *Echocardiography* 2017; 34: 1834–1841
- [48] Glatz JA, Tabbutt S, Gaynor JW et al. Hypoplastic left heart syndrome with atrial level restriction in the era of prenatal diagnosis. *Ann Thorac Surg* 2007; 84: 1633–1638
- [49] Szwaast A, Tian Z, McCann M et al. Vasoreactive response to maternal hyperoxygenation in the fetus with hypoplastic left heart syndrome. *Circ Cardiovasc Imaging* 2010; 3: 172–178
- [50] Olivieri L, Ratnayaka K, Levy RJ et al. Hypoplastic left heart syndrome with intact atrial septum sequelae of left atrial hypertension in utero. *J Am Coll Cardiol* 2011; 57: e369
- [51] Marshall AC, Levine J, Morash D et al. Results of in utero atrial septoplasty in fetuses with hypoplastic left heart syndrome. *Prenat Diagn* 2008; 28: 1023–1028
- [52] Lara DA, Morris SA, Maskatia SA et al. Pilot study of chronic maternal hyperoxygenation and effect on aortic and mitral valve annular dimensions in fetuses with left heart hypoplasia. *Ultrasound Obstet Gynecol* 2016; 48: 365–372
- [53] Co-Vu J, Lopez-Colon D, Vyas HV et al. Maternal hyperoxygenation: A potential therapy for congenital heart disease in the fetuses? A systematic review of the current literature. *Echocardiography* 2017; 34: 1822–1833
- [54] Enzensberger C, Axt-Fliedner R, Degenhardt J et al. Pulmonary vasoreactivity to materno-fetal hyperoxygenation testing in fetuses with hypoplastic left heart. *Ultraschall Med* 2016; 37: 195–200
- [55] Kohl T. Effects of maternal-fetal hyperoxygenation on aortic arch flow in a late-gestation human fetus with closed oval foramen at risk for coarctation. *J Thorac Cardiovasc Surg* 2011; 142: e67–e69
- [56] Borik S, Macgowan CK, Seed M. Maternal hyperoxygenation and foetal cardiac MRI in the assessment of the borderline left ventricle. *Cardiol Young* 2015; 25: 1214–1217
- [57] Channing A, Szwaast A, Natarajan S et al. Maternal hyperoxygenation improves left heart filling in fetuses with atrial septal aneurysm causing impediment to left ventricular inflow. *Ultrasound Obstet Gynecol* 2015; 45: 664–669
- [58] Schidlow DN, Donofrio MT. Prenatal Maternal Hyperoxygenation Testing and Implications for Critical Care Delivery Planning among Fetuses with Congenital Heart Disease: Early Experience. *Am J Perinatol* 2018; 35: 16–23
- [59] Gibbs JL, Wren C, Watterson KG et al. Stenting of the arterial duct combined with banding of the pulmonary arteries and atrial septectomy or septostomy: a new approach to palliation for the hypoplastic left heart syndrome. *Br Heart J* 1993; 69: 551–555
- [60] Pawade A, Waterson K, Laussen P et al. Cardiopulmonary bypass in neonates weighing less than 2.5 kg: analysis of the risk factors for early and late mortality. *J Cardiac Surg* 1993; 8: 1–8
- [61] Akintuerk H, Michel-Behnke I, Valeske K et al. Stenting of the arterial duct and banding of the pulmonary arteries: basis for combined Norwood stage I and II repair in hypoplastic left heart. *Circulation* 2002; 105: 1099–1103
- [62] Galantowicz M, Cheatham JP, Phillips A et al. Hybrid approach for hypoplastic left heart syndrome: intermediate results after the learning curve. *Ann Thorac Surg* 2008; 85: 2063–2071
- [63] Brescia AA, Jureidini S, Danon S et al. Hybrid versus Norwood procedure for hypoplastic left heart syndrome: contemporary series from a single center. *J Thorac Cardiovasc Surg* 2014; 147: 1777–1782
- [64] Davies RR, Radtke WA, Klenk D et al. Bilateral pulmonary arterial banding results in an increased need for subsequent pulmonary artery interventions. *J Thorac Cardiovasc Surg* 2014; 147: 706–712
- [65] Dodge-Khatami A, Chancellor WZ, Gupta B et al. Achieving benchmark results for neonatal palliation of hypoplastic left heart syndrome and related anomalies in an emerging program. *World J Pediatr Congenit Heart Surg* 2015; 6: 393–400
- [66] Lloyd DF, Cutler L, Tibby SM et al. Analysis of preoperative condition and interstage mortality in Norwood and hybrid procedures for hypoplastic left heart syndrome using the aristotle scoring system. *Heart* 2014; 100: 775–780
- [67] Cao JY, Lee SY, Phan K et al. Early Outcomes of Hypoplastic Left Heart Syndrome Infants: Meta-Analysis of Studies Comparing the Hybrid and Norwood Procedures. *World J Pediatr Congenit Heart Surg* 2018; 9: 224–233
- [68] Schranz D, Bauer A, Reich B et al. Fifteen-year single center experience with the “Giessen Hybrid” approach for hypoplastic left heart and variants: current strategies and outcomes. *Pediatr Cardiol* 2015; 36: 365–373
- [69] Yerebakan C, Murray J, Valeske K et al. Long-term results of biventricular repair after initial Giessen hybrid approach for hypoplastic left heart variants. *J Thorac Cardiovasc Surg* 2015; 149: 1112–1120
- [70] Latus H, Nassar MS, Wong J et al. Ventricular function and vascular dimensions after Norwood and hybrid palliation of hypoplastic left heart syndrome. *Heart* 2018; 104: 244–252
- [71] Bittle GJ, Morales D, Deatrck KB et al. Stem Cell Therapy for Hypoplastic Left Heart Syndrome: Mechanism, Clinical Application, and Future Directions. *Circ Res* 2018; 123: 288–300
- [72] Si MS, Ohye RG. Stem cell therapy for the systemic right ventricle. *Expert Rev Cardiovasc Ther* 2017; 15: 813–823
- [73] Ryan JJ, Archer SL. The right ventricle in pulmonary arterial hypertension: disorders of metabolism, angiogenesis and adrenergic signaling in right ventricular failure. *Circ Res* 2014; 115: 176–188
- [74] Schreckenber R, Rebelo M, Deten A et al. Specific mechanisms underlying right heart failure: the missing upregulation of superoxide dismutase-2 and its decisive role in antioxidative defense. *Antioxid Redox Signal* 2015; 23: 1220–1232
- [75] Salih C, Sheppard MN, Ho SY. Morphometry of coronary capillaries in hypoplastic left heart syndrome. *Ann Thorac Surg* 2004; 77: 903–907
- [76] Sutendra G, Dromparis P, Paulin R et al. A metabolic remodeling in right ventricular hypertrophy is associated with decreased angiogenesis and a transition from a compensated to a decompensated state in pulmonary hypertension. *J Mol Med (Berl)* 2013; 91: 1315–1327
- [77] Ptaszek LM, Mansour M, Ruskin JN et al. Towards regenerative therapy for cardiac disease. *Lancet* 2012; 379: 933–942

- [78] Hu S, Liu S, Zheng Z et al. Isolated coronary artery bypass graft combined with bone marrow mononuclear cells delivered through a graft vessel for patients with previous myocardial infarction and chronic heart failure: a single-center, randomized, double-blind, placebo-controlled clinical trial. *J Am Coll Cardiol* 2011; 57: 2409–2415
- [79] Kimura N. Regenerative Therapy for Patients with Congenital Heart Disease. *Keio J Med* 2018. doi:10.2302/kjm.2018-0002-IR
- [80] Ishigami S, Ohtsuki S, Tarui S et al. Intracoronary autologous cardiac progenitor cell transfer in patients with hypoplastic left heart syndrome: the TICAP prospective phase 1 controlled trial. *Circ Res* 2015; 116: 653–664
- [81] Ishigami S, Ohtsuki S, Eitoku T et al. Intracoronary cardiac progenitor cells in single ventricle physiology: the PERSEUS (Cardiac Progenitor Cell Infusion to Treat Univentricular Heart Disease) randomized phase 2 trial. *Circ Res* 2017; 120: 1162–1173
- [82] Kaushal S, Wehman B, Pietris N et al. Study design and rationale for ELPIS: a phase I/IIb randomized pilot study of allogeneic human mesenchymal stem cell injection in patients with hypoplastic left heart syndrome. *Am Heart J* 2017; 192: 48–56
- [83] Oh H. Cell therapy trials in congenital heart disease. *Circ Res* 2017; 120: 1353–1366
- [84] Tarui S, Ishigami S, Ousaka D et al. Transcoronary infusion of cardiac progenitor cells in hypoplastic left heart syndrome: Three-year follow-up of the Transcoronary Infusion of Cardiac Progenitor Cells in Patients With Single-Ventricle Physiology (TICAP) trial. *J Thorac Cardiovasc Surg* 2015; 150: 1198–1207, 1208.e1–1208.e2
- [85] Vorisek C, Shimada S, Axt-Fliehdner R et al. [Inhibition of endocardial fibroelastosis in unborn children with hypoplastic left heart in the cell culture model]. *Z Geburtshilfe Neonatol* 2015; 219 - P08_7
- [86] Xu X, Friehs I, Zhong Hu T et al. Endocardial fibroelastosis is caused by aberrant endothelial to mesenchymal transition. *Circ Res* 2015; 116: 857–866
- [87] Costamagna D, Quattrocchi M, van Tienen F et al. Smad1/5/8 are myogenic regulators of murine and human mesoangioblasts. *J Mol Cell Biol* 2016; 8: 73–87
- [88] Majnemer A, Limperopoulos C, Shevell M et al. Long-term neuromotor outcome at school entry of infants with congenital heart defects requiring open-heart surgery. *J Pediatr* 2006; 148: 72–77
- [89] Limperopoulos C, Majnemer A, Shevell M et al. Neurodevelopmental status of newborns and infants with congenital heart defects before and after open heart surgery. *J Pediatr* 2000; 137: 638–645
- [90] Limperopoulos C, Majnemer A, Shevell MI et al. Predictors of developmental disabilities after open heart surgery in young children with congenital heart defects. *J Pediatr* 2002; 141: 51–58
- [91] Masoller N, Martínez JM, Gómez O et al. Evidence of second-trimester changes in head biometry and brain perfusion in fetuses with congenital heart disease. *Ultrasound Obstet Gynecol* 2014; 44: 182–187
- [92] Graupner O, Koch J, Enzensberger C et al. Head biometry in fetuses with isolated congenital heart disease. *Ultraschall Med* 2018. doi:10.1055/a-0796-6502
- [93] Khalil A, Suff N, Thilaganathan B et al. Brain abnormalities and neurodevelopmental delay in congenital heart disease: systematic review and meta-analysis. *Ultrasound Obstet Gynecol* 2014; 43: 14–24
- [94] Mahle WT, Tavani F, Zimmerman RA et al. An MRI study of neurological injury before and after congenital heart surgery. *Circulation* 2002; 106 (12 Suppl. 1): 109–114
- [95] Miller SP, McQuillen PS, Hamrick S et al. Abnormal brain development in newborns with congenital heart disease. *N Engl J Med* 2007; 357: 1928–1938
- [96] Limperopoulos C, Tworetzky W, McElhinney DB et al. Brain volume and metabolism in fetuses with congenital heart disease: evaluation with quantitative magnetic resonance imaging and spectroscopy. *Circulation* 2010; 121: 26–33
- [97] Kuhn V, Carpenter JL, Tague L et al. Brain Injury Scores of Neonates with Complex Congenital Heart Disease. *Thorac Cardiovasc Surg* 2018 (abstract accepted for publication as conference paper)
- [98] Berg C, Gembruch O, Gembruch U et al. Doppler indices of the middle cerebral artery in fetuses with cardiac defects theoretically associated with impaired cerebral oxygen delivery in utero: is there a brain-sparing effect? *Ultrasound Obstet Gynecol* 2009; 34: 666–672
- [99] Donofrio MT, Bremer YA, Schieken RM et al. Autoregulation of cerebral blood flow in fetuses with congenital heart disease: the brain sparing effect. *Pediatr Cardiol* 2003; 24: 436–443
- [100] Kaltman JR, Di H, Tian Z et al. Impact of congenital heart disease on cerebrovascular blood flow dynamics in the fetus. *Ultrasound Obstet Gynecol* 2005; 25: 32–36
- [101] Yamamoto Y, Khoo NS, Brooks PA et al. Severe left heart obstruction with retrograde arch flow importantly influences fetal cerebral and placental blood flow. *Ultrasound Obstet Gynecol* 2013; 42: 294–299
- [102] Graupner O, Koch J, Enzensberger C et al. Cerebroplacental and maternal hemodynamics in pregnancies complicated by congenital heart disease of the fetus. *Ultraschall Med* 2018 (submitted for publication)
- [103] Szwasz A, Tian Z, McCann M et al. Comparative analysis of cerebrovascular resistance in fetuses with single-ventricle congenital heart disease. *Ultrasound Obstet Gynecol* 2012; 40: 62–67
- [104] Sun L, Macgowan CK, Sled JG et al. Reduced fetal cerebral oxygen consumption is associated with smaller brain size in fetuses with congenital heart disease. *Circulation* 2015; 131: 1313–1323
- [105] Masoller N, Sanz-Cortés M, Crispi F et al. Mid-gestation brain Doppler and head biometry in fetuses with congenital heart disease predict abnormal brain development at birth. *Ultrasound Obstet Gynecol* 2016; 47: 65–73
- [106] Huch A, Huch R, Schneider H et al. Continuous transcutaneous monitoring of fetal oxygen tension during labour. *Br J Obstet Gynaecol* 1977; 84 (Suppl. 1): 1–39
- [107] Nicolaidis KH, Campbell S, Bradley R] et al. Maternal oxygen therapy for intrauterine growth retardation. *Lancet* 1987; 1: 942–945
- [108] Parpaglion R, Capogna G, Celleno D et al. Intraoperative fetal oxygen saturation during Caesarean section: general anaesthesia using sevoflurane with either 100% oxygen or 50% nitrous oxide in oxygen. *Eur J Anaesthesiol* 2002; 19: 115–118
- [109] Willcourt RJ, King JC, Queenan JT. Maternal oxygenation administration and the fetal transcutaneous PO₂. *Am J Obstet Gynecol* 1983; 146: 714–715
- [110] Szwasz A, Putt M, Gaynor JW et al. Cerebrovascular response to maternal hyperoxygenation in fetuses with hypoplastic left heart syndrome depends on gestational age and baseline cerebrovascular resistance. *Ultrasound Obstet Gynecol* 2018; 52: 473–478. doi:10.1002/uog.18919
- [111] Edwards LA, Lara DA, Sanz Cortes M et al. Chronic Maternal Hyperoxygenation and Effect on Cerebral and Placental Vasoregulation and Neurodevelopment in Fetuses with Left Heart Hypoplasia. *Fetal Diagn Ther* 2018; 17: 1–13
- [112] Morris SA, Ethen MK, Penny DJ et al. Prenatal diagnosis, birth location, surgical center, and neonatal mortality in infants with hypoplastic left heart syndrome. *Circulation* 2014; 129: 285–292
- [113] Brown DW, Cohen KE, O'Brien P et al. Impact of prenatal diagnosis in survivors of initial palliation of single ventricle heart disease: analysis of the National Pediatric Cardiology Quality Improvement Collaborative database. *Pediatr Cardiol* 2015; 36: 314–321
- [114] Allen RH, Benson CB, Haug LW. Pregnancy outcome of fetuses with a diagnosis of hypoplastic left ventricle on prenatal sonography. *J Ultrasound Med* 2005; 24: 1199–1203
- [115] Thakur V, Munk N, Mertens L et al. Does prenatal diagnosis of hypoplastic left heart syndrome make a difference? – a systematic review. *Prenat Diagn* 2016; 36: 854–863

- [116] Pasquali SK, Ohye RG, Lu M et al. Variation in perioperative care across centers for infants undergoing the Norwood procedure. *J Thorac Cardiovasc Surg* 2012; 144: 915–921
- [117] Feinstein JA, Benson DW, Dubin AM et al. Hypoplastic left heart syndrome: Current considerations and expectations. *J Am Coll Cardiol* 2012; 59: S1–S42
- [118] Ghanayem NS, Hoffman GM, Mussatto KA et al. Perioperative monitoring in high-risk infants after stage 1 palliation of univentricular congenital heart disease. *J Thorac Cardiovasc Surg* 2010; 140: 857–863
- [119] Greenleaf CE, Urencio JM, Salazar JD et al. Hypoplastic left heart syndrome: current perspectives. *Transl Pediatr* 2016; 5: 142–147
- [120] Cross RR, Harahsheh AS, McCarter R et al. Identified mortality risk factors associated with presentation, initial hospitalization, and interstage period for the Norwood operation in a multi-center registry: a report from the National Pediatric Cardiology-Quality Improvement Collaborative. *Cardiol Young* 2014; 24: 253–262
- [121] Simsic JM, Bradley SM, Stroud MR et al. Risk factors for interstage death after the Norwood procedure. *Pediatr Cardiol* 2005; 26: 400–403
- [122] Knirsch W, Bertholdt S, Stoffel G et al. Clinical course and interstage monitoring after the Norwood and Hybrid procedures for hypoplastic left heart syndrome. *Pediatr Cardiol* 2014; 35: 851–856
- [123] Castellanos DA, Herrington C, Adler S et al. Home monitoring program reduces mortality in high risk socioeconomic single-ventricle patients. *Pediatr Cardiol* 2016; 37: 1575–1580
- [124] Nieves JA, Uzark K, Rudd NA et al. Interstage Home Monitoring After Newborn First-Stage Palliation for Hypoplastic Left Heart Syndrome: Family Education Strategies. *Crit Care Nurse* 2017; 37: 72–88
- [125] Ghanayem NS, Hoffman GM, Mussatto KA et al. Home surveillance program prevents interstage mortality after the Norwood procedure. *J Thorac Cardiovasc Surg* 2003; 126: 1367–1377
- [126] Rudd N, Fommelt MA, Hehir DA et al. Improving interstage survival after Norwood operation: Outcomes following 10 years of home monitoring. *J Thorac Cardiovasc Surg* 2014; 148: 1540–1547