

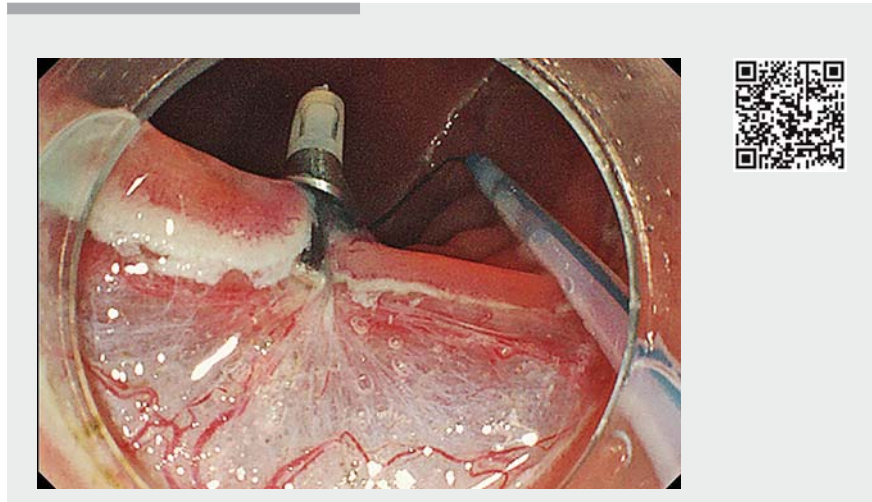
The crane technique: a novel traction method for use during rectal endoscopic submucosal dissection

In order to make it easier to access the submucosal layer during endoscopic submucosal dissection (ESD), various traction devices have been developed and used during colorectal ESD [1, 2]. We report a novel traction method, “the crane technique,” which involves the use of the EndoTrac (Top Corporation, Tokyo, Japan) [3], for rectal ESD.

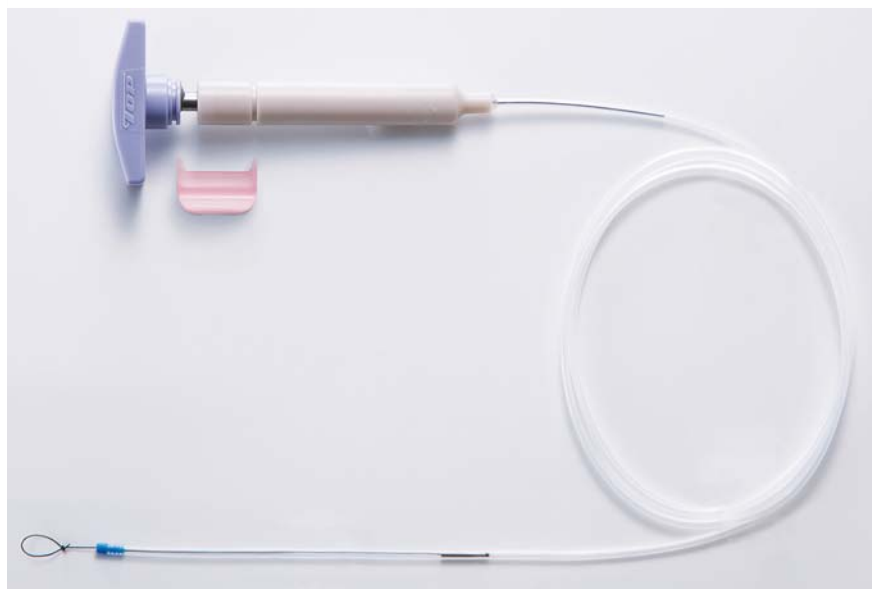The EndoTrac consists of a line with a clinch-knotted loop, a plastic sheath, and a T-shaped handle (► **Fig. 1**). After tying the line to an endoclip, the distance between the endoclip and the tip of the plastic sheath can be adjusted by operating the handle.

In the present case, a 60-mm lesion was located in the rectosigmoid colon. Macroscopically, it was classified as a granular type laterally spreading tumor (► **Fig. 2a**). The first mucosal incision was performed circumferentially, and the EndoTrac device was tied to an endoclip and deployed on the anal side of the margins of the lesion (► **Video 1**).

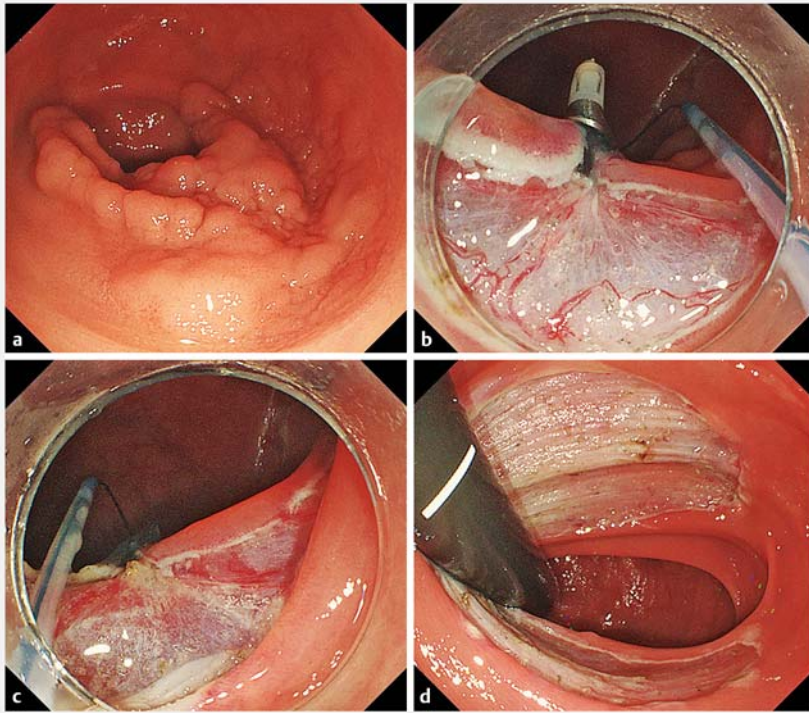
When the endoclip and the tip of the sheath were connected, it was difficult to access the submucosal layer because of interference from the sheath. However, when the endoclip was disconnected from the sheath tip, accessing the submucosal layer became easier by pushing the sheath. In addition, the towing direction could be changed (to the right or left) by altering the positions of the endoscope and sheath. We named this technique “the crane technique” (► **Fig. 2b, c**). This technique improved the visibility of the submucosal layer and made complete resection easier (► **Fig. 2d**, ► **Video 1**).



► **Video 1** The crane technique using the EndoTrac traction device (Top Corporation, Tokyo, Japan) for endoscopic submucosal dissection of a rectal lesion.



► **Fig. 1** The EndoTrac device (Top Corporation, Tokyo, Japan) for traction during endoscopic submucosal dissection.



► **Fig. 2** Endoscopic submucosal dissection (ESD) of a rectal lesion using the EndoTrac traction device (Top Corporation, Tokyo, Japan). **a** A 60-mm lesion in the rectosigmoid colon. **b** The crane technique (right-sided traction). **c** The crane technique (left-sided traction). **d** Condition after ESD.

Previous studies have reported that transanal submucosal endoscopic resection and multitasking platforms also make it possible to change the towing direction during ESD [4, 5]. However, these devices are too big and expensive. The EndoTrac is a much cheaper and simpler device. Thus, the technique described in the present study might facilitate rectal ESD and could become widely used.

Endoscopy_UCTN_Code_TTT_1AQ_2AD

Competing interests

Takashi Toyonaga has received the EndoTrac royalty from TOP.

The authors

Hiroya Sakaguchi, Takashi Toyonaga, Hidetoshi Kaku, Yoshiko Nakano, Shinwa Tanaka, Toshitatsu Takao, Yuzo Kodama
Division of Gastroenterology, Department of Internal Medicine, Kobe University Graduate School of Medicine, Kobe, Japan

Corresponding author

Takashi Toyonaga, MD
Division of Gastroenterology, Department of Internal Medicine, Kobe University Graduate School of Medicine, 7-5-1 Chuo-ku, Kusunoki-cho, Kobe, Hyogo 650-0017, Japan
Fax: +81-78-382-6309
toyonaga@bf7.so-net.ne.jp

References

- [1] Uraoka T, Ishikawa S, Kato J et al. Advantages of using thin endoscope-assisted endoscopic submucosal dissection technique for large colorectal tumors. *Dig Endosc* 2010; 22: 186–191
- [2] Motohashi O. Two-point fixed endoscopic submucosal dissection in rectal tumor (with video). *Gastrointest Endosc* 2011; 74: 1132–1136
- [3] Tanaka S, Toyonaga T, Kaku H et al. A novel traction device (EndoTrac) for use during endoscopic submucosal dissection. *Endoscopy* 2019. doi:10.1055/a-0830-4556 (in press)
- [4] Tsiamoulos ZP, Warusavitarne J, Faiz O et al. A new instrumental platform for trans-anal submucosal endoscopic resection (TASER). *Gut* 2015; 64: 1844–1846
- [5] Phee SJ, Reddy N, Chiu PW et al. Robot-assisted endoscopic submucosal dissection is effective in treating patients with early-stage gastric neoplasia. *Clin Gastroenterol Hepatol* 2012; 10: 1117–1121

Bibliography

DOI <https://doi.org/10.1055/a-0825-6235>
Published online: 7.2.2019
Endoscopy 2019; 51: E88–E89
© Georg Thieme Verlag KG
Stuttgart · New York
ISSN 0013-726X

ENDOSCOPY E-VIDEOS

<https://eref.thieme.de/e-videos>



Endoscopy E-Videos is a free access online section, reporting on interesting cases and new techniques in gastroenterological endoscopy. All papers include a high quality video and all contributions are freely accessible online.

This section has its own submission website at <https://mc.manuscriptcentral.com/e-videos>