

Peroral endoscopic myotomy and fundoplication: a novel NOTES procedure

Authors

Haruhiro Inoue, Akiko Ueno, Yuto Shimamura, Anastassios Manolakis, Ashish Sharma, Shin Kono, Masayuki Nishimoto, Kazuya Sumi, Haruo Ikeda, Kenichi Goda, Manabu Onimaru, Noriko Yamaguchi, Hiroaki Itoh

Institution

Digestive Diseases Center, Showa University Koto Toyosu Hospital, Showa University, Tokyo, Japan

submitted 2.3.2018

accepted after revision 1.11.2018

Bibliography

DOI <https://doi.org/10.1055/a-0820-2731>

Published online: 17.1.2019 | *Endoscopy* 2019; 51: 161–164

© Georg Thieme Verlag KG Stuttgart · New York

ISSN 0013-726X


Corresponding author

Haruhiro Inoue, MD, PhD, Digestive Diseases Center, Showa University Koto Toyosu Hospital, Showa University,

5-1-38 Toyosu, Koto-ku, Tokyo, Japan 135-8577

Fax: +81-3-62046000

haruinoue777@yahoo.co.jp

 Scan this QR-Code for the author's interview.



ABSTRACT

Background Peroral endoscopic myotomy (POEM) has become the minimally invasive endoscopic treatment for achalasia; however, gastroesophageal reflux (GER) post-POEM has been reported. A pilot study was conducted in which an endoscopic fundoplication was added to the standard POEM (POEM+F) procedure to overcome this issue. We report the technical details of POEM+F and short-term safety results.

Methods POEM+F was performed in 21 patients. After completing myotomy, the endoscope was advanced from the submucosal tunnel into the peritoneal cavity. A partial mechanical barrier was created by retracting the anterior gastric wall at the esophagogastric junction with the use of endoclips and an endoloop.

Results POEM+F was technically feasible in all cases and created a visually recognizable fundoplication. The clinical course after POEM+F was uneventful. No immediate or delayed complications occurred.

Conclusion POEM+F may help mitigate the post-POEM incidence of GER and serve as a minimally invasive endoscopic alternative to a laparoscopic Heller-Dor procedure. This is the largest case series of peroral natural orifice transluminal endoscopic surgery without laparoscopic assistance in the human foregut.

Introduction

Since its introduction in 2008, peroral endoscopic myotomy (POEM) has become the minimally invasive endoscopic treatment of choice for achalasia [1,2]. However, the incidence of significant gastroesophageal reflux (GER) post-POEM has been reported in multiple studies [3,4]. In order to overcome this potential adverse event, we conducted a pilot study where an endoscopic partial fundoplication was added to the standard POEM procedure (POEM+F). Here, we report as a case series, the technical details of POEM+F and the short-term safety of the procedure. This is also the largest case series of pure peroral (no laparoscopic assistance) natural orifice transluminal endoscopic surgery (NOTES) in the human foregut.

Methods

Study population

The study was conducted between August 2017 and February 2018 at Showa University Koto Toyosu Hospital (Tokyo, Japan). Patients scheduled to undergo POEM for achalasia were offered POEM+F. Achalasia was diagnosed based on clinical symptoms and high resolution manometry using Chicago 3.0 classification [5]. Patients with significant cardiac comorbidities or gastric surgery were excluded.

The POEM+F study was approved by the Showa University research ethics committee (IRB approval number: 17T5010). Written consent was obtained from all patients before POEM+F.

POEM + F procedure

The POEM+F procedure consists of two major steps: POEM and fundoplication.

POEM

A standard POEM procedure consists of the creation of a submucosal tunnel in the anterior wall of the esophagus at the 12 o'clock position. The tunnel adequacy, in terms of orientation and length, is confirmed by transillumination across the lesser curvature of the gastric wall by using the double-scope technique [6]. A full-thickness myotomy is then carried out in the distal esophagus and extended for about 3 cm along the gastric wall.

Prior to fundoplication, a pediatric gastroscope (XP260N; Olympus, Tokyo, Japan) is placed in the retroflexed position to evaluate the gastroesophageal junction (GEJ) for its laxity. After performing myotomy, a widely opened GEJ can be confirmed.

Fundoplication (▶ Video 1)

The post-POEM fundoplication procedure consists of three steps: entry into the peritoneal cavity; distal and proximal anchoring of the endoloop with clips (the loop and clip technique); and closure of the endoloop.

Step 1 – Entry into the peritoneal cavity (▶ Fig. 1a)

The diaphragmatic crus is endoscopically identified from the submucosal tunnel as a mobile pale-colored indentation that separates the mediastinum from the abdominal cavity. This can be further confirmed by its contraction in response to application of electric current by coagulation forceps. Distal to the diaphragm, a full-thickness myotomy is carried out along the anterior wall of the submucosal tunnel in a 12 o'clock orientation. This defect is enlarged using a combination of a triangle tip (TT) knife (KD645; Olympus) and coagulation forceps (FD-410LR; Olympus) (▶ Fig. 1b).

The peritoneum is grasped and gently dissected using a blend of soft and forced coagulation to open and enter the peritoneal cavity. Meticulous coagulation of intervening blood ves-

sels is carried out to prevent any bleeding. Pneumoperitoneum is achieved with CO₂ insufflation through the endoscope (GIF-Q260J; Olympus) and confirmed by palpation of the abdominal wall. Upon entering the peritoneal cavity, the left hepatic lobe is visualized (▶ Fig. 1c). With continued CO₂ insufflation for optimal visualization, the scope is angulated upwards and to the left in order to reach the anterior surface of the gastric wall.

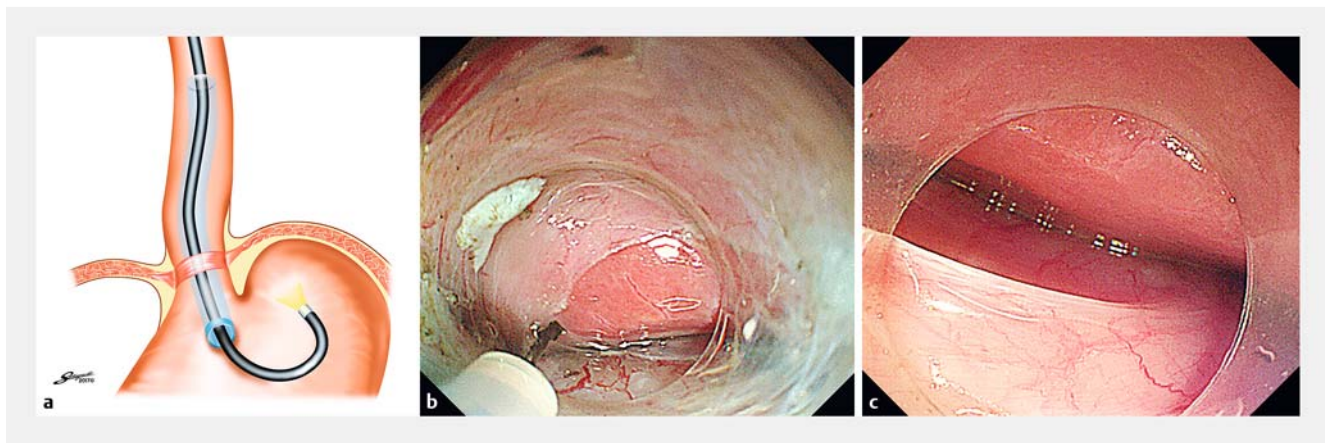
Step 2 – Distal and proximal anchoring of the endoloop with clips (loop and clip technique) (▶ Fig. 2a)

The pediatric gastroscope is placed into the stomach in a retroflexed position to help identify the optimal site for fundoplication. In order to identify the ideal distal anchoring site on the gastric wall that would correspond to the starting point of the fundoplication, multiple "simulations" are carried out by grasping and pulling the anterior gastric wall towards the GEJ at different sites. The site that creates the most prominent identifiable wrap with closure of the GEJ hiatus as seen from the retroflexed scope, is selected for placement of the distal anchor with clips.

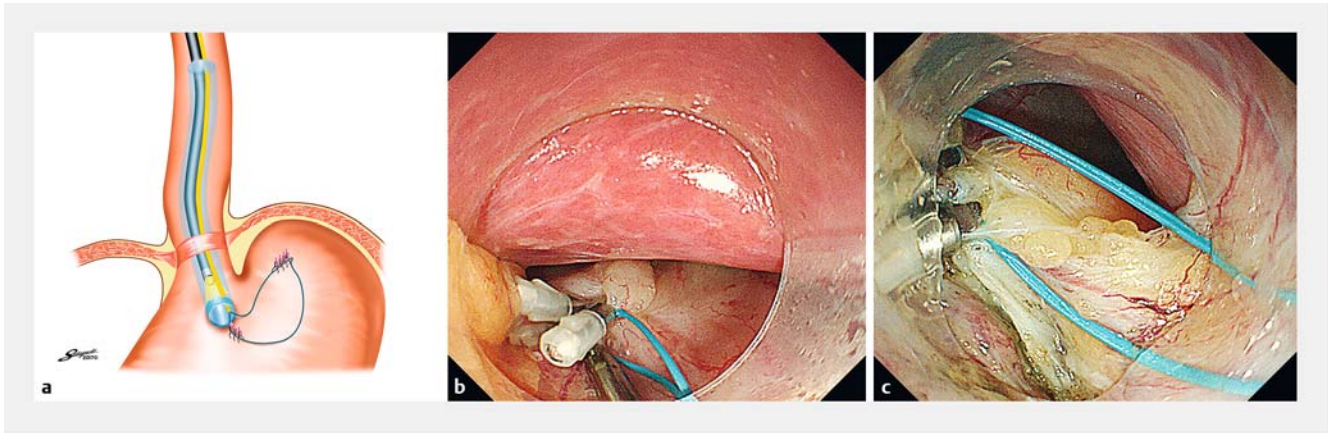
A 2-cm endoloop (HX-400U-30; Olympus) in the open position is then gently grasped by a clip (Quick Clip Pro, HX-610-090S; Olympus) and carried through the submucosal tunnel into the peritoneal cavity (▶ Fig. 2b). The endoloop is positioned and fixed with the aid of four clips to the previously identified distal anchoring site. The other end of the open endoloop is fixed to the edges of the dissected esophageal muscle located at the junction of the submucosal tunnel and the peritoneal cavity using four clips (HX-610-090S; Olympus) (proximal anchoring site) (▶ Fig. 2c).

Step 3 – Closure of the endoloop (▶ Fig. 3a)

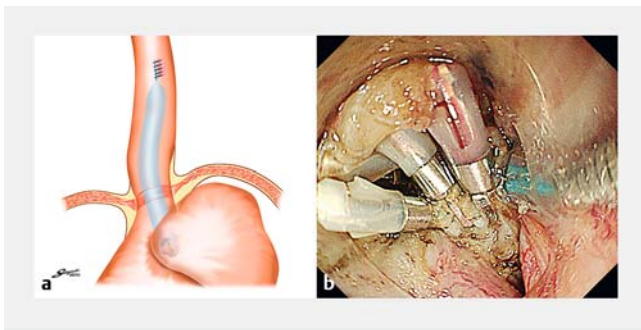
This step involves closure of the endoloop to retract the anterior gastric wall. Under direct visualization, the endoloop is gradually tightened until complete closure is achieved. This par-



▶ **Fig. 1** Conventional peroral endoscopic myotomy (POEM) is completed at the anterior wall of the esophagus. Next, the peritoneal cavity is accessed through the submucosal tunnel. **a** Schematic drawing of POEM with fundoplication (POEM + F) procedure (Step 1). The endoscope is advanced into the peritoneal cavity, just after passing the diaphragmatic crus. **b** Entry into the peritoneal cavity. Distal to the diaphragm, a full-thickness myotomy is carried out along the anterior wall of the submucosal tunnel in a 12 o'clock orientation. This defect is enlarged using a combination of a Triangle Tip knife (Olympus, Tokyo, Japan) and coagulation forceps. **c** The endoscope is advanced into the peritoneal cavity. The left lobe of the liver and the anterior side of the stomach can be seen. Source for illustration: Kent Sakaguchi



► **Fig. 2** Anchoring the endoloop with endoclips to the anterior wall of the gastric fornix and the esophagogastric junction. **a** Schematic drawing of peroral endoscopic myotomy with fundoplication (POEM + F) procedure (Step 2). The endoloop is fixed to the anterior gastric wall and the distal end of the submucosal tunnel with clips. **b** The distal anchor at the gastric anterior wall. **c** Proximal anchor clips at the distal end of the submucosal tunnel. Source for illustration: Kent Sakaguchi



► **Fig. 3** Closure of the endoloop, creating fundoplication. **a** Schematic drawing of peroral endoscopic myotomy with fundoplication (POEM + F) procedure (Step 3). **b** By closing the endoloop, the distal anchor clips are pulled towards the proximal anchor clips. The endoloop is closed tightly and anterior partial fundoplication is achieved. Source for illustration: Kent Sakaguchi

tially rotates and pulls the relatively mobile anterior gastric wall (distal anchoring site) towards the fixed distal esophageal myotomy site (proximal anchor), creating a mechanical barrier that narrows the GEJ hiatus. This mimics the mechanical antireflux barrier of a surgical partial fundoplication. Care is taken to keep the clips placed at the myotomy site in the peritoneal cavity (distal anchoring site) (► **Fig. 3b**). The retraction of the gastric wall and creation of the partial wrap of the gastric cardia is confirmed by the retroflexed pediatric gastroscope placed within the stomach.

Results

A total of 21 patients (mean age 45.4 years (SD 14.0); 10 male) underwent the POEM+F procedure. Patients' perioperative characteristics are shown in ► **Table 1**.

The partial rotation and traction of the anterior gastric wall toward the GEJ created a visually identifiable wrap that mimicked partial fundoplication; this could be seen in all cases. Both still images and video recording were used to compare

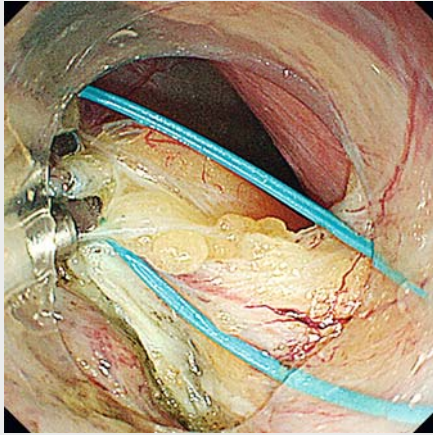
► **Table 1** Patient demographic and perioperative characteristics of peroral endoscopic myotomy followed by fundoplication.

	POEM + F (n = 21)
Age, mean (SD), years	45.4 (14.0)
Sex, male/female, n	10/11
Type, straight/sigmoid, n	18/3
Degree of dilation, I/II/III, n	9/10/2
Chicago classification, I/II/III/other, n	13/5/1/2 ¹
Preoperative IRP pressure, mean (SD), mmHg	22.8 (12.2)
Duration of disease, mean (SD), years	7.2 (7.4)
Primary procedure, none/PBD/other, n	18/3/0
Baseline Eckardt score, mean (SD)	5.7 (1.8)
Procedure completion rate, n (%)	21 (100)
Total operation time, minutes	
▪ Mean (SD)	118.9 (20.2)
▪ Median (range)	115 (92 – 178)
Fundoplication time, minutes	
▪ Mean (SD)	51.3 (18.5)
▪ Median (range)	44 (28 – 88)
Acute adverse event ² , n (%)	0 (0)
Postoperative stay, mean (SD), days	4.7 (0.8)

IRP, integrated relaxation pressure; PBD, pneumatic balloon dilation; POEM + F, peroral endoscopic myotomy followed by fundoplication.

¹ Ineffective esophageal motility, Jackhammer esophagus.

² Bleeding, infection, and any other organ injury.



Video 1 Peroral endoscopic myotomy with fundoplication.
Online content viewable at:
<https://doi.org/10.1055/a-0820-2731>

the pre- and postfundoplication status of the GEJ. Retroflex view of the GEJ after endoscopic fundoplication showed narrowing of the GEJ compared with the preprocedure endoscopic findings. The passage of the scope across the GEJ after fundoplication also felt tighter compared with preprocedure.

The fundoplication was technically feasible in all cases ($n=21$). The fundoplication added 51.3 minutes (SD 18.5; range 28–88) to the POEM procedure time. The pneumoperitoneum was intentional and resolved with removal of the CO₂ gas through the scope or with abdominal/external decompression of the peritoneal cavity. The clinical course after POEM+F was uneventful.

No immediate or delayed complications occurred. Hospital stay and use of analgesia were similar to the conventional POEM procedure.

On follow-up endoscopy at 2 months, almost all POEM+F patients visually appeared to maintain the wrap across the GEJ (95.2%; $n=20$).

Discussion

GER due to disruption of the lower esophageal sphincter is a major complication of the POEM procedure and has been reported in multiple studies [3,4]. After a surgical Heller myotomy for achalasia, a fundoplication (Dor procedure) is often carried out to prevent subsequent GER. The aim of our study was to assess the technical feasibility of endoscopic fundoplication following the POEM procedure. We hoped to achieve this by endoscopically entering the peritoneal cavity through the original tunnel created for the POEM procedure, and retracting the anterior gastric wall to create a partial mechanical barrier and to narrow the hiatus at the GEJ.

In this proof-of-concept study, we were able to access the peritoneal cavity through the submucosal tunnel created for the POEM procedure. At least visually, the concept of creating

a mechanical barrier (fundoplication) by retracting the anterior gastric wall appears to have been achieved. Most importantly, there were no complications, specifically in terms of bleeding or damage to abdominal viscera.

Although the endoscopic approach to the peritoneal cavity through the esophagus has been described previously, this study, to our knowledge, is the first attempt to endoscopically replicate the results of a surgical procedure (fundoplication) and is both trans-peritoneal and uses a NOTES procedure. To our knowledge, this is the largest case series in humans of peroral “pure” NOTES of the foregut.

The relative ease and safety of this procedure suggest that this transperitoneal approach may also be incorporated into other diagnostic and therapeutic interventions requiring intra-peritoneal access, ultimately increasing its use and clinical value.

Conclusions

Although larger, prospective studies are needed to evaluate the efficacy of this technique, POEM+F may help mitigate the post-POEM incidence of GER and serve as a minimally invasive endoscopic alternative to the laparoscopic Heller-Dor procedure.

Acknowledgment

The abstract of an earlier version of this article was presented at Digestive Disease Week 2018 (June 2–5; Washington, DC, USA).

Competing interests

Dr. Inoue is an advisor for Olympus Corporation and Top Corporation. He has also received educational grants from Olympus Corp. and Takeda Pharmaceutical Co.

References

- [1] Inoue H, Minami H, Kobayashi Y et al. Peroral endoscopic myotomy (POEM) for esophageal achalasia. *Endoscopy* 2010; 42: 265–271
- [2] Swanstrom LL, Kurian A, Dunst CM et al. Long-term outcomes of an endoscopic myotomy for achalasia: the POEM procedure. *Ann Surg* 2012; 256: 659–667
- [3] Kumbhari V, Familiari P, Bjerregaard NC et al. Gastroesophageal reflux after peroral endoscopic myotomy: a multicenter case-control study. *Endoscopy* 2017; 49: 634–642
- [4] Wang XH, Tan YY, Zhu HY et al. Full-thickness myotomy is associated with higher rate of postoperative gastroesophageal reflux disease. *World J Gastroenterol* 2016; 22: 9419–9426
- [5] Kahrilas PJ, Bredenoord AJ, Fox M et al. International High Resolution Manometry Working Group. The Chicago Classification of esophageal motility disorders, v3.0. *Neurogastroenterol Motil* 2015; 27: 160–174
- [6] Grimes KL, Inoue H, Onimaru M et al. Double-scope per oral endoscopic myotomy (POEM): a prospective randomized controlled trial. *Surg Endosc* 2016; 30: 1344–1351