

Interventional Treatment of Acute Portal Vein Thrombosis

Interventionelle Therapie der akuten Pfortaderthrombose

Authors

Karsten Wolter¹, Georges Decker¹, Daniel Kuetting¹, Jonel Trebicka², Steffen Manekeller³, Carsten Meyer¹, Hans Schild¹, Daniel Thomas¹

Affiliations

- 1 Dept. of Radiology, University Hospital Bonn, Germany
- 2 Dept. of Internal Medicine 1, University Hospital Bonn, Germany
- 3 Dept. of Surgery, University Hospital Bonn, Germany

Key words

interventional procedures, thrombolysis, thrombectomy, TIPSS, portal hemodynamics, portal vein thrombosis

received 27.12.2017

accepted 14.05.2018

Bibliography

DOI <https://doi.org/10.1055/a-0631-9265>

Published online: 2018

Fortschr Röntgenstr 2018; 190: 740–746

© Georg Thieme Verlag KG, Stuttgart · New York
ISSN 1438-9029

Correspondence

Dr. Karsten Wolter
Radiologische Klinik, Universitätsklinik Bonn,
Sigmund-Freud Str. 25, 53127 Bonn, Germany
Tel.: ++49/2 28/28 71 59 60
Fax: ++49/2 28/28 71 90 83
karsten.wolter@ukb.uni-bonn.de

ZUSAMMENFASSUNG

Hintergrund Die akute Thrombose der Pfortader (aPVT) ist eine schwerwiegende Erkrankung mit hoher Mortalitätsrate. Bei symptomatischen Patienten, welche nicht auf eine systemische Antikoagulantien-Therapie ansprechen, haben sich zunehmend interventionelle Verfahren als Alternative zur Operation etabliert. In der vorliegenden Studie stellen wir in einer retrospektiven Auswertung initiale Ergebnisse der interventionellen Therapie der aPVT dar.

Methode Zwischen 2014 und 2016 wurden 11 Patienten aufgrund einer aPVT behandelt (M: 7; W: 4; mitt. Alter: 41,06 J.). Alle Patienten zeigten rasch einsetzende Symptome ohne portale Kollateralenbildung. Die Thrombose der Patienten betrafte die Pfortader (PA)(11/11), die V. lienalis (VL) (10/11) und die V. mesenterica superior (VMS) (10/11). Techniken der Rekanalisierung: Katheterthrombaspation (1/9), Angiojet (7/9), solitäre lokale Lyse (1/9) und TIPSS (7/9). Lokale Lyse

wurde im Ein- (5/9) oder Zweikatheterverfahren (4/9) appliziert. Das mitt. Follow-up betrug 24,32 Monate.

Ergebnisse Erfolgreiche transjuguläre-transhepatische Punktion bei 9 Patienten. Die Thrombuslast konnte in allen 9 Fällen reduziert werden mit residuellen Thromben in PA (n = 3), VMS (n = 7) und VL (n = 5). Eine Rethrombose mit fortbestehenden abdominellen Schmerzen konnte in einem Fall beobachtet werden, fortschreiten der Thrombose nach initialer Rekanalisierung in einem weiteren Fall. Symptombefreiheit konnte in 6 Fällen erreicht werden. Ein Patient entwickelte Pleuraergüsse, respiratorische Insuffizienz und portosystemische Kollateralen. Die Patienten, die nicht erfolgreich interveniert werden konnten, entwickelten eine kavernöse Transformation der PA. Einer mit fortbestehenden abdominellen Schmerzen.

Schlussfolgerung Interventionelle perkutane Verfahren können die Prognose von Patienten mit aPVT verbessern. Die Ergebnisse weisen darauf hin, dass neben der Reduktion des Thrombus die Verbesserung des Ein- und Ausstroms ggf. mittels eines TIPSS und Lyse im Zweikatheterverfahren von größter Bedeutung ist.

Kernaussagen:

- Pharmacomechanische Thrombektomie mit lokaler Lyse ist ein erfolgversprechender Ansatz
- Der transjuguläre transhepatische Zugangsweg zeigt ein geringes Komplikationsrisiko
- TIPSS und Zwei-Katheter-Lyse können einen grossen Beitrag zur Flussverbesserung liefern

ABSTRACT

Background Acute portal vein thrombosis is a potentially fatal condition. In symptomatic patients not responding to systemic anticoagulation, interventional procedures have emerged as an alternative to surgery. This study sought to retrospectively evaluate initial results of interventional treatment of acute portal vein thrombosis (aPVT) using a transjugular interventional approach.

Materials and Methods Between 2014 and 2016, 11 patients were treated because of aPVT (male: 7; female: 4; mean age: 41.06 years). All patients presented a rapid onset of symptoms without collateralization of portal flow as assessed by a CT scan at the time of admittance. The patients showed thrombotic occlusion of the main portal vein (11/11), the lienal vein (10/11) and the superior mesenteric vein (10/11). Different techniques for recanalization were

employed: catheter thromboaspiration (1/9), AngioJet device (7/9), local-lysis-only (1/9) and TIPSS (7/9). Local lysis was administered using a dual (4/9) or single (5/9) catheter technique. The mean follow-up was 24.32 months.

Results In 9 patients transhepatic access was successful. Initially reduction of thrombus load and recanalization were achieved in all 9 cases with residual thrombi in PV (n = 3), SMV (n = 7), and IL (n = 5). In the collective undergoing interventional procedures (n = 9) rethrombosis and continuous abdominal pain were seen in one patient, and thrombus progression after successful recanalization was seen in another. Freedom from symptoms could be achieved in 6 patients. One patient developed peritoneal and pleural effusion, respiratory insufficiency and portosystemic collaterals. Both patients who could not undergo an interventional procedure developed a cavernous transformation of the portal vein. One of them also had continuous intermittent abdominal pain.

Conclusion Interventional percutaneous approaches are able to improve patient outcome in patients with aPVT. It

appears to be of utmost importance to not only remove/reduce the thrombotic material but to establish sufficient inflow and outflow by TIPS and simultaneous multi-catheter thrombolysis.

Key Points:

- Pharmacomechanic thrombectomy in combination with local thrombolysis is a feasible approach
- The transjugular transhepatic approach seems to be a safe procedure
- TIPSS and dual catheter lysis may support flow management

Citation Format

- Wolter K, Decker G, Kuetting D et al. Interventional Treatment of Acute Portal Vein Thrombosis. *Fortschr Röntgenstr* 2018; 190: 740–746

Introduction

Portal vein (PV) thrombosis (PVT) is a rare condition with an incidence of about 0.7 per 100 000 per year [1]. The acute and subacute onset of PVT (aPVT) is even more infrequent, but specific incidence rates are not known. Many occurrences of aPVT remain asymptomatic but serious, painful clinical courses with mortality rates of up to 75 % have been reported [2]. To avoid fatal outcomes, early diagnosis and treatment are vital. Most authors agree upon employing systemic anticoagulation as first-line therapy with a high rate of non-responders especially in younger patients [3–5]. Particularly involvement of the superior mesenteric vein (SMV) is associated with a severe outcome [6, 7] and should be treated more aggressively to prevent bowel ischemia. Recently, interventional therapies have been proposed to facilitate rapid recanalization and therefore restitution of normal portal pressure in acute PVT [8, 9].

The proposed techniques vary between selective thrombolysis through the superior mesenteric artery, as well as local thrombolysis with or without mechanical thrombectomy using a percutaneous transhepatic or a transjugular transhepatic access.

The objective of the current study is to report our initial experience in the interventional treatment aPVT.

Materials and Methods

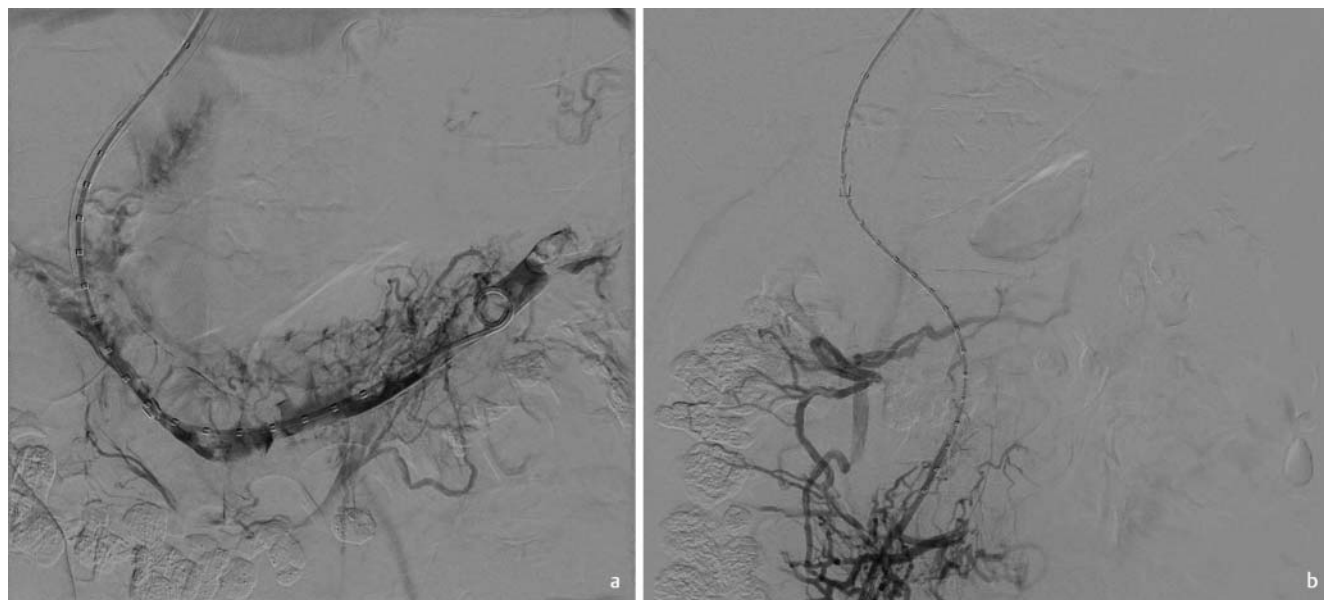
Between 2014 and 2016, a total of 11 patients (M: 7; F: 4; mean age: 41.06 years; age range: 16–66 years) who had undergone interventional treatment of acute PVT were retrospectively identified. The mean follow-up was 24.32 months (range: 2.1–92 months). In all cases PVT was diagnosed with CT scans using contrast agent at portal venous timing. Acuteness was defined analog to Franchis et al. [5] as the presentation of symptoms like rapid onset of abdominal pain, ascites and fever with no portosystemic

collaterals and portal cavernoma. These patients were scheduled for interventional treatment after failure of adequate response under systemic anticoagulation. In five patients, an underlying condition was found which predisposed for hypercoagulopathy (1 polycythaemia vera, 1 protein s deficiency, 1 essential thrombocythemia, 1 antiphospholipid syndrome, 1 liver transplantation after autoimmune hepatitis). Two patients had a history of recent blunt abdominal trauma. In one patient, a Budd-Chiari syndrome of unknown origin was found. The cause of PVT remained undiscerned in three patients.

All patients (n = 11) suffered from full occlusion of the extrahepatic portal vein. In ten patients, the thrombus extended into the superior mesenteric vein (SMV) and in nine also into the splenic vein (LV), thereby fully occluding these.

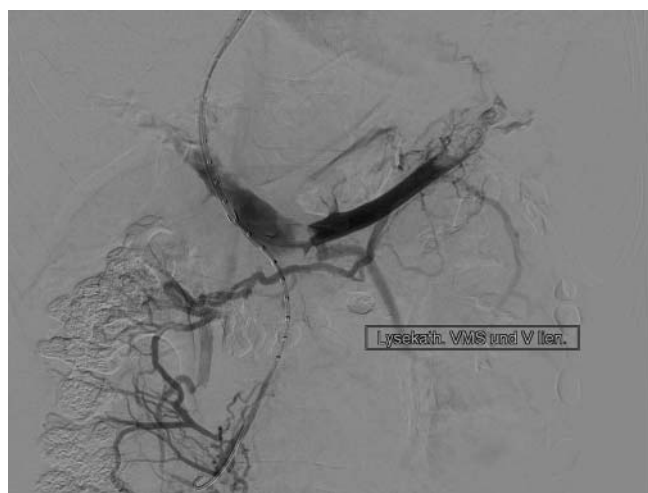
Interventional procedure

In all patients, a transjugular approach was used. Transhepatic puncture was performed under ultrasound guidance. A hydrophilic wire (Terumo, Tokyo, Japan) was threaded through the puncture cannula and a 5-Fr vertebral catheter (Cook medical, Bloomington, USA) was subsequently advanced into the portal vein (PV), the lineal vein (LV) and the superior mesenteric vein (SMV). Venography was then performed at these sites (► **Fig. 1**). In all but one patient (n = 8) local thrombolysis was preceded by thromboaspiration. In 1 patient, thromboaspiration was performed manually utilizing a 6-Fr. catheter (Envoy, Cook). In seven patients, a rheolytic mechanical thromboaspiration device (AngioJet Zelan-teDVT, Boston scientific, Marlborough, USA) was employed for recanalization of the splanchnic veins. In these cases the thrombus was infiltrated with 100 000 IE Urokinase (medac GmbH, Wedel, Germany) prior to thrombectomy using a “pulse spray” technique (5 * AngioJet supported; 1 * catheter aspiration, 2 * AngioJet + catheter).



► **Fig. 1** **a** Acute thrombosis portal vein, lienal vein and superior mesenteric vein – diagnostic contrast injection in lienal vein; **b** Acute thrombosis portal vein, lienal vein and superior mesenteric vein – diagnostic contrast injection in superior mesenteric vein.

► **Abb. 1** **a** Akute Thrombose der Pfortader, der V. lienalis und der V. mes. sup. – Kontrastmittelspritzung über V. lien. **b** Kontrastmittelspritzung über V. mes. sup.



► **Fig. 2** Simultaneous dual catheter local lysis using two transjugular transhepatic catheters located in lienal und superior mesenteric veins.

► **Abb. 2** Simultane lokale Lyse über zwei transjugulär transhepatisch eingebrachte Katheter in der V. lien. und V. mes. sup.

In 4 cases two catheters were employed to infuse the lytic agent (Urokinase) (► **Fig. 2**), which were placed into the SMV and IL (n = 3), or SMV and inferior mesenteric vein (IMV) (n = 1). Single catheter infusion was used in 5 patients with placement in the SMV (n = 3) and LV (n = 2).

Dosage was adapted to patient weight (<65kg: 80 000 IE/h; >65kg: 100 000 IE/h). All patients were under continuous surveillance at the local intensive care unit (ICU). After 6 to 10 hours (and

at 12- to 2- hour intervals thereafter), portal venography was performed to reevaluate the thrombolytic result (► **Fig. 3**).

Thrombolysis was ended when no further improvement of hemodynamics could be achieved or contraindications for ongoing therapy emerged (low blood fibrinogen concentration <125 mg/dl).

In 7 of 11 patients, a transjugular portosystemic stent shunt (TIPSS) was established to enhance blood flow in the portal vessels and reduce the rate of recurrent occlusion. A TIPSS was created by dilatation of the transhepatic accessway to 8 mm diameter, deployment of the 10 mm stent graft (VIATORR Endoprosthesis, Gore medical, Newark, Delaware, USA) and subsequent balloon dilatation to 8 mm.

Technical success was defined as being able to create transjugular-transhepatic access and reestablish blood flow in the main portal vein.

Results

An overview of each case with outcomes and follow-up is presented in ► **Table 1** (► **Fig. 1 – 5**).

In two cases the intervention had to be aborted because transhepatic access to the portal system could not be established. These patients were treated with systemic anticoagulation. Both patients developed a cavernous transformation of the portal vein. One of them with persistent intermittent abdominal pain. We observed no periinterventional bleeding complications. We also did not observe any other complications.

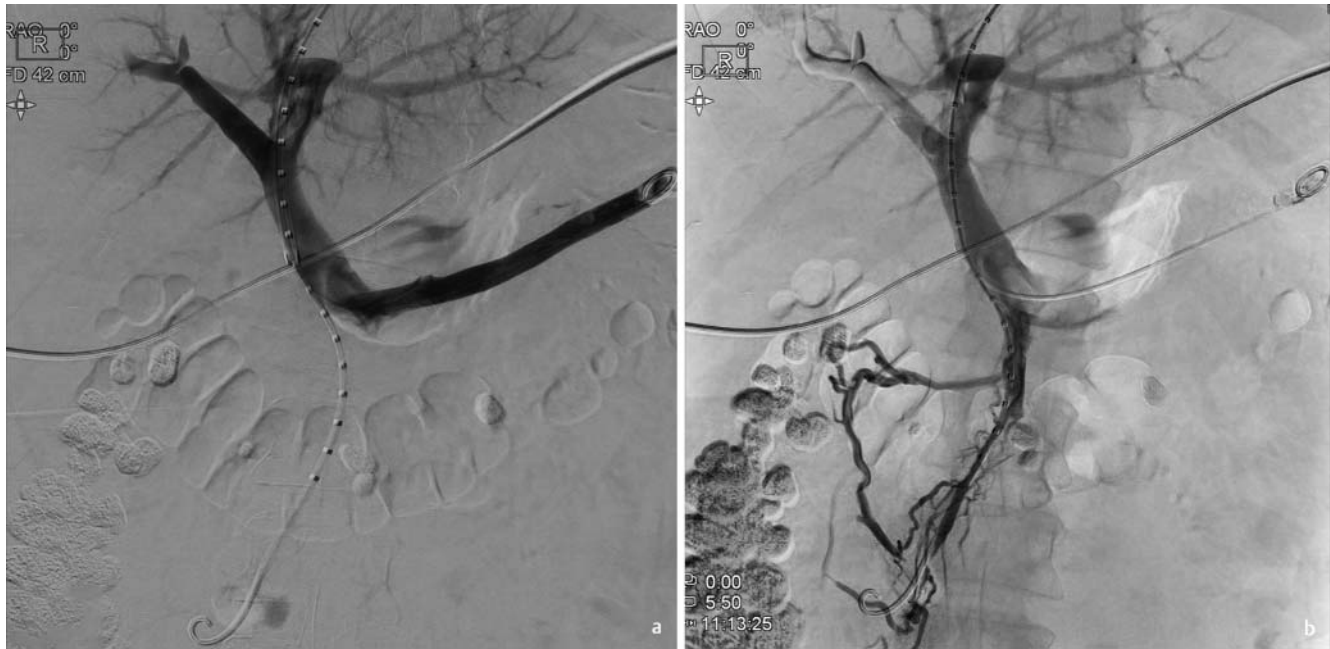Initial reduction of thrombus load and recanalization was achieved in all 9 remaining cases with residual thrombi in the PV

► **Table 1** Case overview.

► **Tab. 1** Fallüberblick.

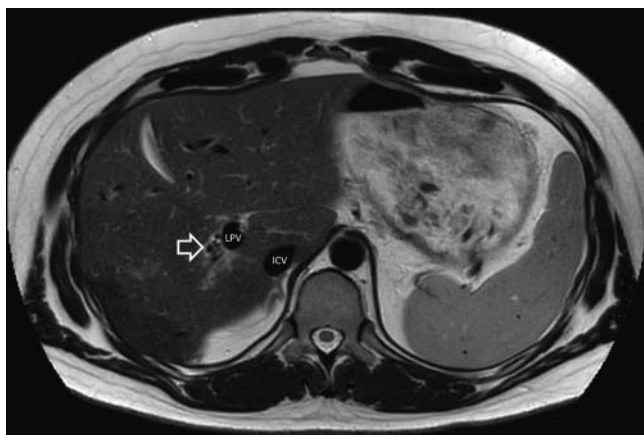
patient no.	age	diagnosis	cirrhosis	thrombosis	inter- vention	lysis location	lysis duration (days)	TIPSS	follow-up duration (months)	recanalization patency	complication	clinical status at endpoint
1	66	C2, Hep C, abdominal trauma	+	PV, SMV, LV	cath-TE	SMV, LV	6	yes	2	partial	no	no recurrent symptoms
2	31	unknown	+	PV, SMV, LV	AngioJet-TE	SMV, IMV	2	yes	28	patent	hepatic encephalopathy	no recurrent symptoms
3	47	essential thrombocythemia	–	PV, SMV, LV	AngioJet-TE	SMV	2	yes	20	patent	no	no recurrent symptoms
4	31	Budd Chiari syndrome	–	PV, LV	lysis only	LV	2	yes	40	patent	no	no recurrent symptoms
5	44	protein S insufficiency	–	PV, SMV	AngioJet-TE	SMV	1	yes	22	patent	TIPSS occlusion	no recurrent symptoms
6	52	unknown	–	PV, SMV, LV	AngioJet-TE	SMV, LV	3	yes	13	occlusion	TIPSS occlusion, rethrombosis	rethrombosis, abdominal pain
7	45	antiphospholipid syndrome	–	PV, SMV, LV	AngioJet-TE	LV	4	no	15	patent	no	no recurrent symptoms
8	34	JAK2 mutation	–	PV, SMV, LV	AngioJet-TE	SMV, LV	3	no	10	partial	no	slight recurrent abdominal pain
9	27	JAK2 mutation	–	PV, SMV, LV	n/a	n/a	n/a	no	92	occlusion	cavernous transformation, esophageal varices I°	recurrent abdominal pain
10	54	polycythaemia vera	–	PV, SMV, LV	n/a	n/a	n/a	no	24	occlusion	cavernous transformation, esophageal varices I°	recurrent pleural effusions, no abdominal pain
11	16	liver transplantation after autoimmune hepatitis, splenect.	–	PV, SMV	AngioJet-TE	SMV	4	yes	3	occlusion	TIPSS occlusion, rethrombosis	multi-organ failure

PV = portal vein; SMV = superior mesenteric vein; LV = lienal vein; TE = thrombectomy; Hep = Hepatitis; C2 = alcohol abuse.



► **Fig. 3** Control angiography during lysis – contrast injection in lienal vein **a** and superior mesenteric vein **b** – open portal vein with residual thrombi in SMV and intrahepatic right portal vein.

► **Abb. 3** Kontrollangiographie unter lokaler Lysetherapie - Kontrastmittelinjektion über V. lien. **a** und V. mes. sup. **b** – Offene Pfortader mit residuellen Thrombus in der V. mes. sup. und der intrahepatischen rechten Pfortader.



► **Fig. 4** Follow-up MRI after 10 months – cavernous transformation of intrahepatic right portal vein (arrow) – open intrahepatic left portal vein (LPV)- inferior caval vein (ICV).

► **Abb. 4** Verlaufskontrolle nach 10 Monaten (MRT) – kavernös transformierter intrahep. rechter Pfortaderast (Pfeil) – offener linker Pfortaderast (LPV) – V. cava inf. (ICV).

(n=3), SMV (n=7), and LV (n=5). To further improve blood flow and reduce the risk of rethrombosis, a TIPSS was created in 7 patients. Spontaneous TIPSS reocclusion in the follow-up period occurred in three patients. The first, which had initially been recanalized successfully, but with residual thrombi in the SMV and LV, showed complete reocclusion of all three veins (PV, SMV and LV) and the TIPSS. The second case demonstrated TIPSS occlusion without any impact on successful recanalization of the portal

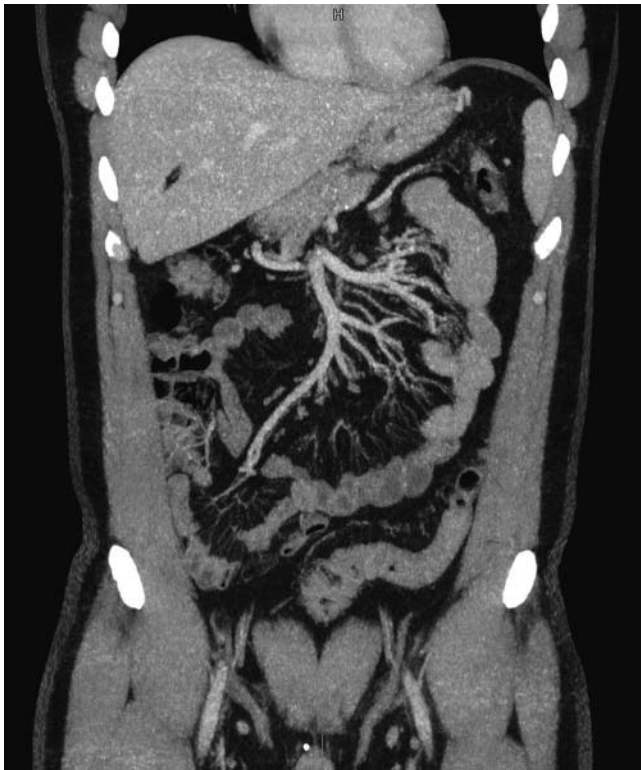system. The third patient suffered from thrombotic reocclusion of the TIPSS as well as PV and SMV (LV was absent due to prior splenectomy) during the initial thrombolytic treatment period after mechanical thrombectomy had been able to restore flow but with residual thrombi. The patient showed prominent mesenterico-iliac collaterals which were embolized during the initial control angiography to improve hepatopetal flow. Nevertheless, embolization and further local lysis were not able to prevent reocclusion.

In two patients, recanalization was not followed by a TIPSS procedure. Both patients were symptom-free after re-establishing flow, despite residual thrombus following the intervention. One of the patients showed full resolution of the thrombus under oral anticoagulation over a seven-month follow-up period. However, the other patient showed an increased thrombus load following the intervention, but no recurrent full occlusion.

Discussion

APVT is a rare yet potentially severe condition with reported high morbidity and mortality rates of up to 50% [2, 10, 11]. Fast diagnosis and management appears to be crucial in order to avoid complications and ensure patient survival [12].

At the moment, there is no interdisciplinary consensus for the management of acute PVT in the case of treatment failure with standard anticoagulation. Prior studies investigated the effectiveness of systemic anticoagulation with heparin [11, 13]. Anticoagulation may be able to achieve some degree of recanalization [13, 14]. However, in a recent larger study Maldonado et al. [15] reported



► **Fig. 5** Follow-up CT after 10 months (coronal MPR) – symptom-free patient with good recanalization result – open superior mesenteric vein, portal vein, lienal vein (not shown) and left intrahepatic portal vein.

► **Abb. 5** Verlaufs-CT nach 10 Monaten (koronare MPR) – symptomfreier Patient mit gutem Rekanalisationsergebnis – offene V. mes. sup., Pfortader und V. lien. (nicht dargestellt) und linkem Pfortaderast.

surprisingly high rates of the development of portal hypertension in the follow-up of patients receiving anticoagulation alone.

Thus, in symptomatic patients with an inadequate response to anticoagulative therapy, additional invasive treatment may be warranted.

As an alternative to anticoagulation, systemic thrombolysis has been suggested in the past. It has been shown to improve recanalization rates yet it was associated with an elevated level of bleeding complications [16].

To reduce systemic complications of thrombolytic therapy, catheter-directed approaches have been proposed in the past. Various routes of access consisting of transhepatic, transsplenic, transjugular-transhepatic access as well as indirect thrombolysis through the superior mesenteric artery (AMS) have been employed and described in small series of patients [6, 9]. Currently, there is no data supporting the use of either of these approaches over the others. The approach presented in this series of cases consists of a transjugular transhepatic approach comprising pharmacomechanical thrombectomy, local thrombolysis and portal flow management. The transjugular access has the advantage that it may be used to create a TIPSS for establishment of improved hepatopetal flow. Also, it is associated with a lower risk of bleeding, because it does

not involve puncture of the liver capsule or uncovered vascular segments in patients who will undergo subsequent lysis which has been described as a problem in the past [6, 9] with complication rates of about 60 % [9]. However, the puncture of thrombosed portal vein branches may be technically more challenging if the interventional team is not familiar with routine ultrasound-guided TIPSS procedure.

Using this technique, a high rate of initial technical success of 82 % (n = 9) was achieved with only two recurring full occlusions and no periinterventional bleeding complications. All seven remaining patients did not show any symptoms during the follow-up period. This seems to be in contrast to previous data where the splanchnic veins in all patients with aPVT could only be partially recanalized and suffered from early reocclusion [6]. Another report described complication rates as high as 65 % [9].

Analysis of the data, especially the cases in which the rethrombosis or partial rethrombosis occurred during the follow-up period, stressed the importance of good inflow and outflow management. In these cases, the inflow was insufficient due to persisting (partial) thrombosis of both VMS and VL, and/or the outflow was impaired and no TIPSS was established. In one of the cases (P11), the inflow was also compromised because of prior splenectomy and mesenterico-iliac collaterals.

Since establishment of a TIPSS is the only way to improve or increase hepatopetal flow, it is reasonable to assume that it will improve lysis and patient outcome. This is also supported by our data demonstrating a high patency rate in the group which was additionally treated with a TIPSS. Due to the small number (n = 2) of patients in our study treated without a TIPSS, this hypothesis needs further investigation in a larger patient population.

We used a two-catheter-based infusion technique in order to deliver the lytic agent (Urokinase) to both inflow vessels simultaneously in four cases, thus accelerating the re-establishment of inflow. To our knowledge this technique has previously only been described in one case report [17].

In seven cases, we employed a rheolytic thrombectomy device (AngioJet Zelante DVT). The successful employment of this device for portal vein thrombectomy has been reported in prior case reports [18, 19]. Its use has been thought to accelerate recanalization, thereby reducing hospitalization time and thrombolysis-associated complications. In contrast to earlier published case reports in the presented study population, additional continuous local lysis after mechanical thrombectomy was needed to further decrease thrombus load (mean: 3 days). This may be due to thrombotic material being older in some of the patients and therefore more rigid and less prone to mechanical removal. In one patient (P1) lysis was performed over more than four days because the results were not satisfactory and was stopped on day six when a satisfactory result was visible and no further thrombus reduction could be achieved.

Our study has several limitations. Firstly, due to the rarity of the described pathological entity, our number of cases is limited and the described results should be evaluated further in studies with a bigger number of cases.

In summary, the presented data shows that it is possible to successfully re-institutionalize blood flow in the mesenteric and portal veins using a combined pharmacomechanical transjugular approach. The treatment was successful in most cases, no major

complications occurred, and symptoms were resolved. Reestablishing hepatopetal flow in the portal system seems to play a pivotal role in successful treatment. This can be accomplished by establishing a TIPSS and performing simultaneous multi-catheter thrombolysis in both major feeding vessels.

CLINICAL RELEVANCE:

- aPVT is a potentially fatal disease where fast treatment is key to reduce complication rates
- Interventional pharmacomechanical thrombectomy in combination with local thrombolysis is a feasible approach with a good success rate
- This preliminary case series indicates that the transjugular transhepatic approach is a safe procedure
- Inflow and outflow management (placement of a TIPSS and dual catheter lysis) seems to be of major importance

Conflict of Interest

The authors declare that they have no conflict of interest.

Widmung

Diese Arbeit ist Herrn Universitäts-Professor Hans H. Schild gewidmet, bei dem wir uns herzlich für die langjährige und stete Unterstützung in allen klinischen und wissenschaftlichen Belangen bedanken möchten.

References

- [1] Rajani R, Björnsson E, Bergquist A et al. The epidemiology and clinical features of portal vein thrombosis: A multicentre study. *Aliment Pharmacol Ther* 2010; 32: 1154–1162
- [2] Gertsch P, Matthews J, Lerut J. Acute thrombosis of the splanchnic veins. *Arch Surg* 1993; 128: 341–345
- [3] Chung JW, Kim GH, Lee JH et al. Safety, efficacy, and response predictors of anticoagulation for the treatment of nonmalignant portal-vein thrombosis in patients with cirrhosis: a propensity score matching analysis. *Clin Mol Hepatol* 2014; 20: 384–391
- [4] Amitrano L, Guardascione MA, Menchise A et al. Safety and efficacy of anticoagulation therapy with low molecular weight heparin for portal vein thrombosis in patients with liver cirrhosis. *J Clin Gastroenterol* 2010; 44: 448–451
- [5] Sarin SK, Valla DC, De Franchis R. Revising consensus in portal hypertension: Report of the Baveno v Consensus Workshop on methodology of diagnosis and therapy in Portal Hypertension. *J Hepatol* 2011; 54: 1082–1083
- [6] Rosenqvist K, Eriksson LG, Rorsman F et al. Endovascular treatment of acute and chronic portal vein thrombosis in patients with cirrhotic and non-cirrhotic liver. *Acta Radiol* 2016; 57: 572–579
- [7] Abraham MN, Mathiason MA, Kallies KJ et al. Portomesenteric venous thrombosis: A community hospital experience with 103 consecutive patients. *In: Am J Surg* 2011; 759–764
- [8] Kim HS, Patra A, Khan J et al. Transhepatic Catheter-directed Thrombectomy and Thrombolysis of Acute Superior Mesenteric Venous Thrombosis. *J Vasc Interv Radiol* 2005; 16: 1685–1691
- [9] Hollingshead M, Burke CT, Mauro MA et al. Transcatheter Thrombolytic Therapy for Acute Mesenteric and Portal Vein Thrombosis. *J Vasc Interv Radiol* 2005; 16: 651–661
- [10] Cohen J, Edelman RR, Chopra S. Portal vein thrombosis: a review. *Am J Med* 1992; 92: 173–182
- [11] Rhee RY, Glociczki P. Mesenteric venous thrombosis. *Surg Clin North Am* 1997; 77: 327–338
- [12] Ferro C, Rossi UG, Bovio G et al. Transjugular intrahepatic portosystemic shunt, mechanical aspiration thrombectomy, and direct thrombolysis in the treatment of acute portal and superior mesenteric vein thrombosis. *Cardiovasc Interv Radiol* 2007; 30: 1070–1074
- [13] Condat B, Pessione F, Helene Denninger M et al. Recent portal or mesenteric venous thrombosis: increased recognition and frequent recanalization on anticoagulant therapy. *Hepatology* 2000; 32: 466–470
- [14] Sheen CL, Lamparelli H, Milne A et al. Clinical features, diagnosis and outcome of acute portal vein thrombosis. *QJM* 2000; 93: 531–534
- [15] Maldonado TS, Blumberg SN, Sheth SU et al. Mesenteric vein thrombosis can be safely treated with anticoagulation but is associated with significant sequelae of portal hypertension. *J Vasc Surg Venous Lymphat Disord* 2016; 4: 400–406
- [16] Malkowski P, Pawlak J, Michalowicz B et al. Thrombolytic Treatment of Portal Thrombosis. *Hepatogastroenterology* 2003; 50: 2098–2100
- [17] Sehgal M, Haskal ZJ. Use of Transjugular Intrahepatic Portosystemic Shunts during Lytic Therapy of Extensive Portal Splenic and Mesenteric Venous Thrombosis: Long-term Follow-up. *J Vasc Interv Radiol* 2000; 11: 61–65
- [18] Sze DY, O'Sullivan GJ, Johnson DL et al. Mesenteric and portal venous thrombosis treated by transjugular mechanical thrombolysis. *Am J Roentgenol* 2000; 175: 732–734
- [19] Stambo GW, Grauer L. Transhepatic portal venous power-pulse spray rheolytic thrombectomy for acute portal vein thrombosis after CT-guided pancreas biopsy. *Am J Roentgenol* 2005; 184: 118–119