

# Current Technique and Application of Percutaneous Cryotherapy

## Aktuelle Technik und Anwendung der perkutanen Kryotherapie

### Authors

Andreas H. Mahnken, Alexander Marc König, Jens Holger Figiel

### Affiliation

Department of Diagnostic&Interventional Radiology,  
Philipps-University Marburg, Germany

### Key words

cryoablation, oncology, ablation, neoplasm, cancer,  
image-guided

received 01.02.2018

accepted 27.02.2018

### Bibliography

DOI <https://doi.org/10.1055/a-0598-5134>

Published online: 17.4.2018

Fortschr Röntgenstr 2018; 190: 836–846

© Georg Thieme Verlag KG, Stuttgart · New York

ISSN 1438-9029

### Correspondence

Prof. Andreas H. Mahnken

Diagnostic&Interventional Radiology, Philipps-University  
Marburg, Baldingerstrasse, 35043 Marburg, Germany

Tel.: ++ 49/64 21/5 86 62 30

mahnken@med.uni-marburg.de

### ABSTRACT

**Purpose** Local ablative therapies have become an established treatment option in interventional oncology. Radiofrequency ablation (RFA) and microwave ablation (MWA) are a standard of care in the treatment of hepatocellular carcinoma (HCC). Currently, there is an increasing interest in cryotherapy, one of the oldest ablation techniques. It has some unique characteristics with regard to technology and mechanism of action.

**Materials and Methods** A systematic literature search using the terms cryotherapy, cryosurgery and cryoablation was performed. Selected studies are presented dealing with the mechanism of action, cryobiology and clinical use of percutaneous, image-guided cryoablation. Recent developments and perspectives are presented.

**Results** Cryotherapy is increasingly used and has been included in guidelines for selected tumor entities such as renal cell carcinoma. Cryo-immunotherapy and combination treatments are future areas of interest.

**Conclusion** Cryoablation may be used in many indications. Its major advantages are its unique visualization and the anesthesiologic effects of cold. While there are only a few prospectively randomized trials, the existing data on the use of cryo-

ablation is promising. Its use appears to be justified in selected tumors, oligometastatic patients and for palliative indications.

### Key Points

- Interventionalists need to know about the unique characteristics and advantages of cryoablation.
- Proper patient selection and optimal image guidance are essential for successful cryotherapy.
- Cryoablation offers unique advantages such as anesthesiologic effects and characteristic imaging features.
- The lack of prospective randomized trials is a key disadvantage of cryoablation.

### Citation Format

- Mahnken AH, König AM, Figiel JH. Current Technique and Application of Percutaneous Cryotherapy. Fortschr Röntgenstr 2018; 190: 836–846

### ZUSAMMENFASSUNG

**Hintergrund** Lokal-ablative Therapien haben sich als wichtiger interventionell-onkologischer Therapieansatz etabliert. Radiofrequenzablation (RFA) und Mikrowellenablation (MWA) sind heute ein therapeutischer Standard zur Therapie des hepatozellulären Karzinoms (HCC). Die Kryotherapie, als eine der ältesten lokal-ablativen Methoden, erfährt aktuell eine Renaissance. Dabei verfügt die Kryotherapie über charakteristische Eigenschaften in Bezug auf Technik und Wirkmechanismus.

**Material und Methode** Nach einer systematischen Literaturrecherche mit den Suchbegriffen Kryotherapie, Kryochirurgie und Kryoablation erfolgte eine selektive Auswahl der Studien und Darstellung von Wirkmechanismus, Kryobiologie und Anwendungen der perkutanen, bildgesteuerten Kryoablation für vornehmlich onkologische Anwendungen. Aktuelle Entwicklungen werden betrachtet.

**Ergebnisse** Die Kryotherapie erfährt wieder zunehmende klinische Beachtung und hat für einige Entitäten wie die Behandlung des Nierenzellkarzinoms Eingang in die Leitlinien gefunden. Kryo-Immuntherapie und Kombinationstherapien sind künftige Entwicklungsfelder.

**Schlussfolgerung** Die Kryoablation hat ein weites Anwendungsfeld. Die größten Vorteile sind die gute Visualisierung in der Bildgebung und der anesthesiologische Effekt von Kälte. Obwohl nur sehr wenige prospektive randomisierte Studien zur Effektivität der Kryoablation vorliegen, sind die bisherigen Daten vielversprechend und rechtfertigen den Einsatz der Kryoablation bei ausgewählten Primärtumoren, Metastasen beim oligometastatischen Patienten sowie in palliativer Indikation.

## Introduction

The application of extreme cold is a well-established method for destroying tissue [1]. Cryotherapy is currently used in numerous organ regions from the head to the foot. Although the brain, eye, heart, esophagus, and respiratory tract are also target structures for cryotherapy, primarily malignancies of the liver, kidney, lung, prostate, and breast are treated with cryotherapy in interventional radiology. As a result of increasingly early detection of tumors, expertise regarding the use of image-guided puncture techniques, and broad availability of such techniques, local ablation of tumors has become a mainstay of tumor therapy. Cryoablation is only one of many techniques for tissue destruction but has very specific characteristics that are particularly interesting for tumor treatment. The following provides an overview of the use and current status of percutaneous cryotherapy.

## History of cryotherapy

The clinical application of cryotherapy dates back to the 19th century. Already prior to 1850, saline solutions were cooled to temperatures between  $-18$  and  $-24$  °C and used to treat superficial tumors, e. g. in the region of the breast and cervix [2]. At the start of the 20th century, a significantly more effective cryogen with a temperature of  $-78.5$  °C became available in the form of dry ice (solid  $\text{CO}_2$ ), resulting in a significant expansion of the application of cryotherapy, primarily in dermatology [3]. Commercial availability of liquid nitrogen marked the beginning of modern cryotherapy. This highly effective cryogen made it possible to reach a temperature of  $-196$  °C, and the development of various applicators made it possible to treat deeper locations.

The introduction of a vacuum-assisted applicator for neurosurgery in 1961 marked a decisive milestone for cryotherapy [4]. What was originally a dermatological method developed into an entire group of primarily intraoperative applications. Thus, the term cryosurgery became established. Despite many developments, e. g. the development of gas-based cryotherapy devices [5], routine use remained limited to a few indications. Cryotherapy again achieved clinical significance in the 1990s with modern imaging and the miniaturization of applicators. The image-guided cryotherapy systems used today in interventional radiology utilize the Joule-Thomson effect which describes the isenthalpic throttling effect of gases, i. e., the ability of a gas to extract thermal energy from the surrounding area during fast expansion. This form of image-guided therapy resulted in the term cryoablation so that today the terms cryotherapy, cryosurgery, and cryoablation are often used synonymously.

## Mechanism of action and cryobiology

The type and extent of tissue reaction depend on the severity of the cold damage. This is largely controlled by the use of freezing and thawing processes and the temperatures that are achieved. The total cold damage is a mixture of direct and indirect effects.

The application of cold initially results in the formation of extracellular ice crystals. As a result of a shift of the osmotic

balance, water moves from the intracellular space into the interstitium, resulting in dehydration and initial cell damage. This process is at least partially reversible. However, if freezing occurs very quickly, a majority of the fluid remains intracellular since there is insufficient time for osmotic processes, resulting in the formation of intracellular ice crystals. These have a destructive effect on the cell membrane and cell organelles. During thawing, water flows from the hypotonic interstitium into the cells thus resulting in further cell damage or even bursting of the cells. Consequently, more intracellular water is available in a second freezing process for the formation of particularly lethal intracellular ice crystals [6].

A further relevant factor is the collapse of the blood supply on the microvascular level due to damage to the vessel wall as a result of ice formation in the endothelium. After thawing, the damaged endothelium comes in contact with the thrombocytes, resulting in the formation of a thrombosis and thus local ischemia. Moreover, the increased capillary permeability resulting from the vascular damage and the local formation of edema with consecutive swelling of the tissue contribute to the ischemia [7].

In recent years apoptosis has also been recognized as an important mechanism for local tumor therapy particularly in the periphery of the ablation zone. Mitochondrial damage due to activation of caspase 3 and the bax protein has been identified [8].

The sensitivity of different tissues to cold differs greatly. While it can be assumed that one-time application of a temperature of  $-40$  °C to  $-60$  °C is sufficient to completely destroy tissue, this is not the case at a temperature of  $-20$  °C. Tissue differences have a greater impact at this temperature. For example, while osteocytes will definitely die in this temperature range, tissue from a healthy liver, kidney or prostate can survive one-time application of such a temperature. Compared to healthy cells, tumor cells have greater and variable resistance to cold [9]. Moreover, fibroblasts and collagen fibers usually survive a freezing process [10].

The extent of the aforementioned effects and thus the effectiveness of cryoablation can be influenced by the speed, duration, and number of freeze and thaw processes. According to current knowledge, the use of at least two freeze-thaw cycles with fast freezing and slow thawing is particularly effective [11]. The freezing process should last at least 10 minutes since equilibrium between cold generation and the dissipation of cold at the periphery of the ablation zone is achieved and the ice ball reaches its maximum size only after 10–15 minutes. Furthermore, the speed of the freezing process decreases from the center to the periphery so that the freezing process does not last long enough in the peripheral tissue to achieve lethal damage. It must be taken into consideration that prolonged freezing is necessary primarily at higher temperatures to achieve a pronounced destructive effect. The second freeze-thaw cycle helps to bring the lethal effects to the periphery of the ice ball. Moreover, it is essential that the ice ball extend beyond the borders of the targeted treatment area since the  $0$  °C isotherm as the border of the visible ice ball does not correspond to the border of the effective ablation area. It must exceed the lesion to be treated by at least 5–8 mm so that the  $-20$  °C zone reaches the entire lesion.

## Application

Significant and very fast cooling is induced around an applicator inserted into the tissue. The Joule Thomson effect is utilized by the currently available percutaneous systems. This effect describes how real gases experience a change in temperature after fast expansion. Gases with a high inversion temperature, such as argon, experience cooling under expansion (argon up to  $-185^{\circ}\text{C}$ ). Gases with a low inversion temperature, e. g. helium, undergo warming.

Currently used cryoablation systems are closed systems in which gas is conducted under high pressure into a thin applicator. An expansion chamber in which the gas can expand very quickly so that the Joule Thomson effect is utilized is located in the tip of the applicator. An insulator which prevents the cold from traveling along the shaft is applied to the shaft of the cryo-applicator proximal to the expansion chamber to limit the cold effect on tissue outside the target area.

Two systems for percutaneous cryoablation are currently in common use: Visual Ice (Galil – BTG, Farnham, UK) and Endocare Cryocare (Health Tronics, Austin, TX, USA). Both systems use argon for freezing and helium for thawing. Some newer probes for the Visual Ice system can also be electrically heated. This allows ablation of the puncture tract and does not require expensive helium.

The broad availability of image guidance techniques contributed to the renaissance of cryoablation in the late 1990s. The ice ball can be effectively visualized and monitored with ultrasound, computed tomography, and magnetic resonance imaging (► **Fig. 1**). The ice ball can also be visualized three-dimensionally on CT and MRI. Even thermometry within the ice is possible with MRI [12]. In contrast, ultrasound shows only the surface of the ice with subsequent total echo cancellation. This limits the use of ultrasound-guided cryoablation.

Application-relevant advantages of cryotherapy compared to other techniques are the anesthetic effect of cold which simplifies use in local anesthesia. Application does not require any electrical currents so that cryoablation does not interact with imaging. Therefore, continuous monitoring of the size of the ice is possible even with MR guidance. Since every probe is independent, multiple probes can be used in combination with greater flexibility than in radiofrequency ablation (RFA), for example. Additional theoretical advantages are the preservation of fibroblasts which often maintains the primary tissue structure resulting in a matrix for healing. Therefore, for example, ablation in the direct vicinity of the renal pelvis without destruction of the renal pelvis is possible [13]. Healing, albeit often prolonged healing, is possible even in the ablation of nerves if the nerve sheath is preserved (► **Fig. 2**) [14, 15] The pronounced immune-stimulating effects of cryoablation compared to other ablation techniques can also be seen as an advantage.

A clear disadvantage of cryoablation is the relatively high cost not only for probes but also for helium and argon. Each cryotherapy probe has only a limited range in tissue so that multiple probes are usually needed. This provides medically desirable flexibility regarding the size and shape of the ablation area but is not covered by the current DRG-based billing system in Germany. Moreover, cryoablation results in an inflammatory response that

can result in individual cases – primarily in the ablation of large liver tumors – in systemic cytokine-mediated cryoshock syndrome with hypotension, dyspnea, and disseminated intravascular coagulation. Moreover, aggressive manipulation of probes in frozen tissue can result in parenchyma tears and subsequent bleeding [16].

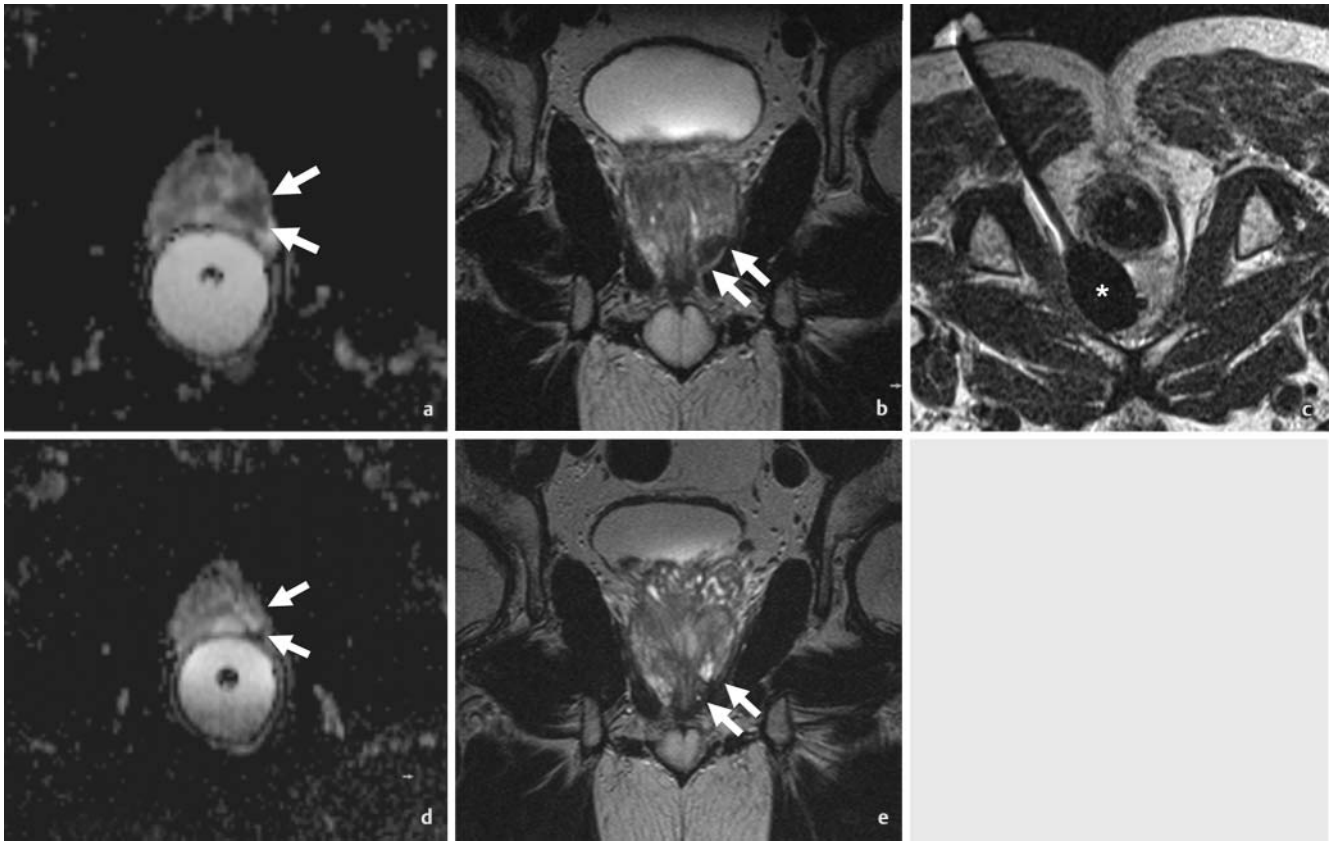
## Results

There are numerous reports regarding the application of cryoablation for almost all organ and body regions. Most of these are retrospective cohort studies with high variability regarding patient selection, procedure, and aftercare so that there is only limited comparability of data. Only a few high-quality comparative studies and randomized controlled trials are available. Selected study data are presented in the following for the most commonly treated organ regions to provide an overview of the current status of the use of percutaneous cryotherapy.

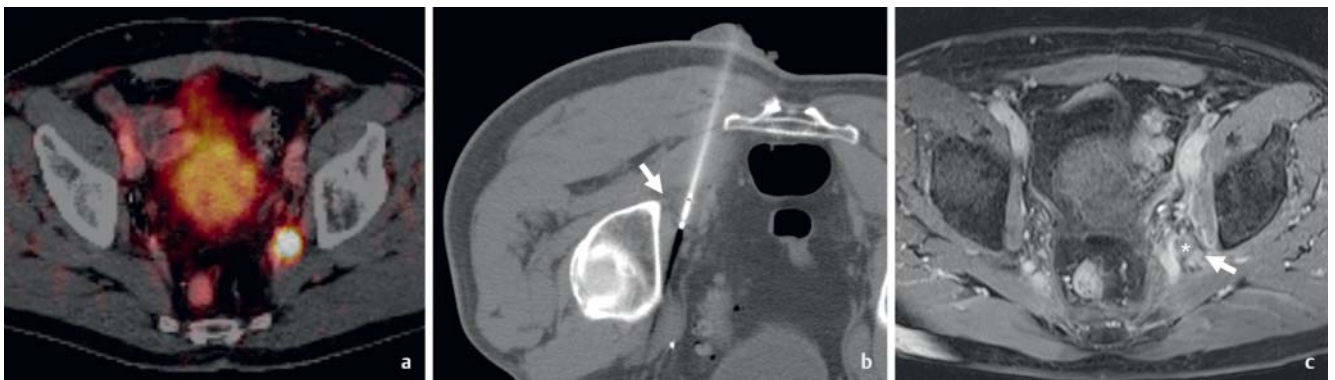
### Kidney

Next to the treatment of prostate cancer, the treatment of kidney tumors is probably the most common application area of cryoablation. Cryotherapy is usually performed both percutaneously and laparoscopically. Percutaneous cryoablation is indicated in small tumors (T1a). However, T1b tumors are also included in numerous studies. Given the rarity of lymph node metastases in these organ-limited lesions, therapy is performed with a curative intent.

The oncological effectiveness of percutaneous cryoablation for the treatment of T1 renal cell carcinomas has been repeatedly shown. For example, Breen et al. were able to show in 171 T1a/b tumors with an average follow-up period of 20.1 months that treatment is also safe in patients with relevant comorbidities (Charlson Index Score = 7.15) with 4.6% Clavien–Dindo grade 2 complications. Only one case of local tumor relapse occurred during follow-up and was accessible for another cryotherapy procedure [17]. Georgiades found a 5-year overall survival rate of 97% with a tumor-specific overall survival rate of 100% in 134 histologically verified T1a/b renal cell carcinomas. Grade 3 or 4 complications according to the Common Terminology Criteria for Adverse Events (CTCAE – Version 4.0) occurred in 6% of patients [18]. Both series did not show a significantly worse result for the treatment of T1b tumors but the number of patients with tumors >4 cm was limited in both series. A metaanalysis found no differences between percutaneous and laparoscopic cryoablation regarding oncological results. No difference could be shown with respect to survival, but the length of hospitalization was shorter for percutaneous cryotherapy [19]. The data compared to percutaneous cryotherapy with partial nephrectomy are more difficult to interpret. Some examinations do not show a difference regarding the oncological result [20, 21] while other data have an advantage for partial nephrectomy – however with a significant bias in patient selection in favor of partial nephrectomy [22]. Interestingly, the relevant oncological results were not worse even in the treatment of T1b tumors in the aforementioned series. However, the



► **Fig. 1** 59-year old patient with histologically proven prostate cancer (Gleason 4 + 4). Biopsy and multiparametric MRI both showed the malignant lesion on the left apex of the prostate gland. Diffusion-weighted (arrows, **a**) and T2-weighted images (arrows, **b**) prior to treatment depict the carcinoma as a hypointense lesion. The patient underwent MR-guided cryoablation. Real-time MRI shows an elliptical signal void (asterisk), corresponding to the ice. Follow-up MRI one year after the procedure shows no signs of residual or recurrent tumor. The signal intensity of the tumor bearing part of the prostate is inconspicuous (arrows, **d** & **e**). According to biochemical markers, the patient was free of tumor.



► **Fig. 2** A 68-year-old patient presented with a biochemical recurrence 10 years after radical prostatectomy. PSMA (prostate-specific membrane antigen)-PET/CT revealed a histologically proven lymph node metastasis **a**. The patient underwent CT-guided cryoablation of the lymph node metastasis, which was located in close proximity to the sciatic nerve (arrow, **b**). On post-interventional MRI **c**, there is no contrast enhancement of the lymph node, indicating successful treatment. The sciatic nerve is swollen. Impaired sensation of the skin and foot recovered spontaneously several weeks after treatment. Nine months after the procedure, the patient is free of tumor according to imaging and biochemical markers.

complication rates increase to 15–17% when treating large tumors [23, 24] so that cryotherapy should be limited to patients with T1a tumors particularly in high-risk patients.

## Liver

Cryoablation of the liver was considered problematic for a long time following reports about fatal outcomes due to so-called cryoshock after ablation of large liver lesions [25]. More recent

studies no longer report this problem and high-quality data regarding the treatment of hepatocellular carcinoma (HCC) is now available [16]. However, the significance of cryoablation of liver tumors compared to RFA or microwave ablation (MWA) is negligible.

The most important study on cryoablation of HCC to date is a randomized, controlled multicenter study published by Wang et al. in 2015 in which 180 patients with 1–2 HCCs <4 cm and Child-Pugh stage A or B were treated either via cryoablation or RFA. A significantly lower local progression rate after cryoablation (7.7%) compared to RFA (18.2%;  $p = 0.041$ ) was able to be shown for tumors >3 cm in particular. However, no difference in survival rate was able to be shown. The 1-, 3-, and 5-year overall survival rates were almost identical at 97%, 67%, and 40%, respectively, for cryoablation compared to 97%, 66%, and 38%, respectively, after RFA ( $p = 0.747$ ). As an important finding, the safety of hepatic cryoablation with a complication rate similar to RFA of 3.9% versus 3.3% could be shown ( $p = 0.776$ ) [25].

Other case series have been able to confirm better local control of early HCCs after cryoablation compared to RFA [26]. However, a current metaanalysis shows a more inhomogeneous picture with a higher complication rate after cryoablation [27]. The use of cryoablation in intermediate and advanced HCCs and in unresectable and recurrent tumors has also been reported. Of course, such cases are associated with worse results than in earlier stages and in smaller tumors [28, 29].

The use of percutaneous cryotherapy in liver metastases is more problematic than in HCCs. Although current series mainly including liver metastases of colorectal tumors are available, there are no prospective randomized studies. Two current series including 742 liver tumors yielded acceptable results regarding safety in tumors <4 cm with grade  $\geq 3$  complications in 5.8–8.7% of interventions but a significant increase in the complication rate in larger lesions [30, 31]. There are significant differences with respect to results, i. e., Littrup et al. showed a local progression rate similar to that of other methods of 11.1% after 1.8 years in metastases of colorectal tumors [30] while the progression rate reported by Glazer et al. after 2.5 years was 25.4% [31]. In a separate study including 59 patients with 151 liver metastases of colorectal carcinomas, Littrup's group reports an average survival rate of 23.6 months after cryotherapy [32]. As a result of the use of different report standards and adjuvant therapies, it is difficult to compare data. However, smaller tumors showed significantly better local control also in this case.

Promising results are also available for liver metastases in breast cancer [33], ovarian cancer [34], and neuroendocrine tumors [35]. Numerous series provide initial information regarding the local effectiveness of this therapy also in liver metastases of other tumor entities [30, 31]. Recommendations regarding cryoablation of liver metastases have not yet been able to be derived from the limited data.

## Lung

In the treatment of primary lung tumors, there is currently minimal but positive data regarding non-small cell lung cancer (NSCLC). In 64 high-risk patients with NSCLC in stage I who were not suitable for lobectomy, Zemlyak et al. were not able to show a difference regarding survival between cryoablation, radiofre-

quency ablation, and sublobar resection with a 3-year overall survival rate of 77%, 87.5%, and 87.1%, respectively ( $p > 0.05$ ). The tumor-specific 3-year overall survival rate (90.2%, 90.6% and 87.5%) showed even smaller differences [36]. Only recently were Moore et al. able to confirm these results with a 3-year and 5-year overall survival rate of 78.1% and 67.8%, respectively. The tumor-specific 5-year survival rate was even 87.9% here [37].

Cryotherapy has also been used for the treatment of advanced NSCLC. However, given the usually palliative treatment intention and the use of multiple treatment options, these cases are difficult to interpret. Niu et al. were able to show in a retrospective analysis in 54 patients (31 with cryoablation, 23 without cryoablation) that a survival advantage can be achieved even for patients in stage IV. In a follow-up period of 6.5 years, the survival of patients receiving additional intra- and/or extrathoracic cryoablation was significantly better than in patients who did not undergo additional ablative therapy. The average overall survival rate of both groups was 14 vs. 7 months ( $p < 0.01$ ) [38].

The current data for the treatment of lung metastases is significantly more problematic. The only prospective study available to date on this topic has only one treatment arm including a total of 60 lesions of different entities, primarily lung metastases of colorectal tumors (40%). After a year at a tumor-specific survival rate of 100%, new metastases were detected in 40% of the patients. Although local control could not be achieved in only 5.8% of patients, the systemic problem of the underlying disease is still present [39]. Numerous retrospective studies confirm this data with there being significant variability regarding local control and survival [40–42].

The complications of pulmonary ablation are similar to those of other needle-based ablation techniques. Therefore, pneumothorax and pleural effusion as well as hemoptysis are common and are reported in up to 60% of procedures. However, they usually do not require treatment. Only the need for a thoracic drain was reported in up to 25% of cases of pneumothorax. Tumor size and the use of multiple ablation electrodes were independent risk factors for the development of a complication [43].

## Breast

Cryotherapy of the breast was initially primarily successfully used to treat symptomatic fibroadenomas [44]. Treatment results in a significant volume reduction and more than 80% of fibroadenomas are no longer palpable a year after treatment [45].

The use of cryotherapy in breast cancer has also become established. However, some special features must be taken into consideration. There is initially a significantly elevated risk of locally incomplete ablation in tumors >2 cm so that the size is a decisive prognostic factor [46, 47]. Moreover, most ablations were performed with ultrasound guidance. Since ultrasound shows only the surface of the ice ball without the three-dimensional context, it must be viewed as suboptimal technology given existing techniques. In a current metaanalysis, it was able to be shown that the technical success rate of cryoablation was 93% (95% CI 81–98%). At the same time, with a rate of major complications of only 2% (95% CI 1–7%), cryoablation had the most favorable risk profile of all ablation techniques [48].

86 patients with 87 breast carcinomas < 2 cm were included in a current prospective study with subsequent resection of the lesions and were treated via cryotherapy with an ablation system based on liquid nitrogen. This requires ultrasound-guided positioning of only one needle. Under these problematic conditions, local tumor control could be achieved in 92 % of cases with the result being significantly better in small tumors up to 1 cm than in larger tumors [49]. Another study showed local control of 76.9 % of breast carcinomas up to 3 cm after 12 months. The need to use multiple needles particularly in large lesions > 1.5 cm is referenced here [50]. The advantages of cryoablation are the low complication rate and the good cosmetic results. A clear disadvantage is the inability to perform axillary lymph node dissection so that there is total dependence on imaging. High variability in the relevant number of local and locoregional relapses in 1.7 % to 20 % of cases was described even after skin-sparing, breast-conserving resection [51]. In light of current data, local cryotherapy of breast cancer in high-risk patients with small tumors seems worth considering.

### Musculoskeletal system

Cryoablation is established for controlling symptomatic musculoskeletal lesions primarily in palliative cases. It could be shown for a broad range of skeletal regions including the spinal column that both improvement of the pain score and a reduction in pain medication can be achieved in only one week [52, 53]. Callstrom et al. reported a reduction of the pain score on a visual analog scale from 7.1/10 prior to treatment to 4/10 after 4 weeks [53]. However, the long-term effects are variable. Some studies report an improvement over 6 months and longer [53] while other authors describe a recurrence of pain already after 3 months in individual patients [54]. Adjunctive measures, such as selective nerve blocks, can support the effect of cryotherapy in a palliative indication [52]. The combination of cryoablation in this indication with bisphosphonate therapy is advantageous since the effects are synergistic [55]. Complications are rare with temporary neuropathy being described most frequently in up to 6 % of cases depending on the position of the lesion [52].

The use of cryoablation in primary bone tumors has been described in various constellations. It can be effective in benign lesions such as aneurysmatic bone cysts [56, 57]. Cryotherapy has also been successfully evaluated for benign, locally invasive desmoid tumors with good response rates and tumor progression between 0 % and 4 % over 2 years after ablation [58, 59]. Only anecdotal reports regarding malignant primary tumors of the musculoskeletal system are available [60] so that cryoablation is not indicated as a primary therapy outside of studies. However, cryotherapy can be successful for the management of symptomatic retroperitoneal sarcoma relapse, for example. Therefore, Fan et al. were able to report a significant pain reduction from 7.49/10 to 5.44/10 ( $p=0.01$ ) on a visual analog scale after cryotherapy of cases of retroperitoneal sarcoma relapse [61].

The treatment of bone and soft-tissue metastases in oligometastatic patients with up to 4 musculoskeletal metastases to be treated has also been evaluated in large retrospective series with variable local tumor control: 67 % in bone lesions and 97 % in soft-tissue lesions after 21 months [62]. Another series describes a

local relapse rate of 10 % after 11 months with there being differences depending on the tumor location [63]. Treatment of a limited number of bone metastases seems promising. Deschamps et al. report local tumor-free survival in 67 % of patients after one year in a collective of 89 oligometastatic patients with 122 bone metastases of various primary tumors after radiofrequency ablation or cryoablation. Lesions smaller than 2 cm without cortical erosion had a particularly favorable prognosis. Local tumor-free survival after one year was achieved in 85 % of cases [64]. Supplementary measures such as osteoplasty can be necessary regardless of ablative therapy. This form of treatment does not rule out subsequent radiotherapy. The complication rates are very low with only individual grade 3 complications in the above-mentioned series.

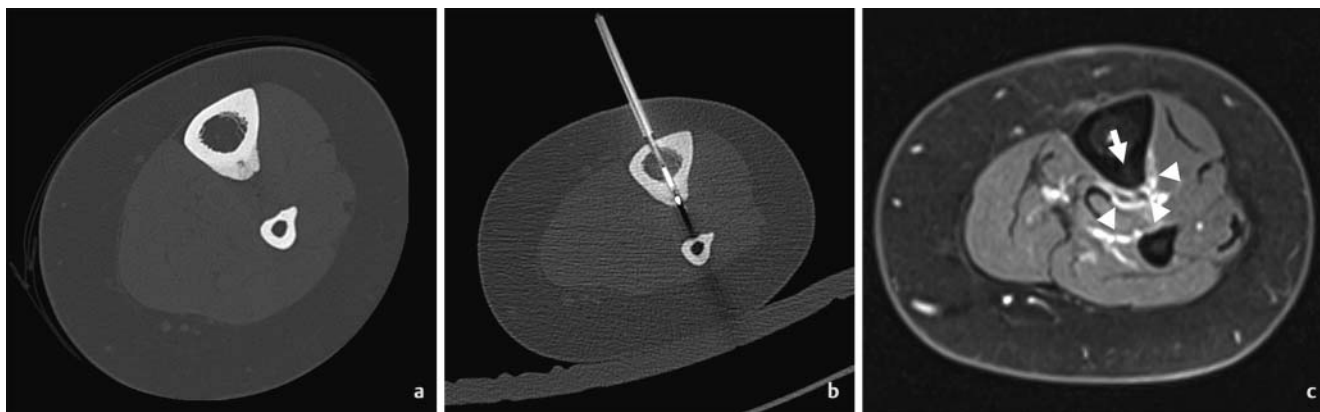
### Prostate

Focal treatment of prostate cancer is a commonly performed but also controversial treatment option [65, 66]. Cryotherapy is one of multiple focal treatment options. Both treatment of the entire prostate and focal treatment of tumor areas verified on imaging and by biopsy are possible. However, in the latter approach it must be taken into consideration that prostate cancer is often multifocal. However, not every verified carcinoma is biologically relevant. Cryotherapy of the prostate also plays a role as a salvage option after radiation therapy. In this situation, the operation is particularly complex and is associated with a significantly increased rate of complications, such as damage to the rectum (~2 %) and incontinence (~23 %) [67].

The COLD register can be referenced as the largest individual study regarding cryoablation of the prostate. The results of focal cryotherapy in 1160 patients and ablation of the entire prostate in 4099 patients are documented here. The biochemical recurrence-free survival rate after 3 years was 75.7 % after focal ablation and 75.1 % after ablation of the entire prostate. The complication rates after focal ablation are lower than after cryoablation of the entire prostate. However, on the whole, the complication rates are lower than after surgical therapy [68]. A current systematic review regarding focal therapy of prostate cancer identified 11 analyzable publications regarding focal cryotherapy. Prospective randomized studies are lacking. Ablation was performed under transrectal ultrasound guidance. In a median follow-up interval of 26 months, tumor-specific survival and overall survival were both 100 %. A second focal treatment was necessary in 7.6 % of patients. The rate of severe complications was low (2.5 %). Continence was able to be maintained in all patients and the ability to get an erection was preserved in 81.5 % of patients [69].

Cryoablation of the prostate can also be used as salvage therapy. The largest patient collective including 297 reported patients in a salvage situation is from the database of the COLD register. The 5-year survival rate after cryotherapy is 97 % with a biochemical tumor-free 5-year survival rate of 58.9 % [70]. The complication rates are higher in this situation than in native ablation. In the last analysis of the database of the COLD register, the incontinence rate was 1.6 % after focal ablation versus 12.3 % after ablation in the salvage situation [68].

Initial data regarding MRI-guided cryoablation of the prostate as an innovative approach is available. Gangi et al. reported on 11



► **Fig. 3** A 29-year-old female patient presented with the typical clinical and imaging findings of an osteoid osteoma of the left tibia **a**. The lesion was treated with cryoablation. After CT-guided drilling, the cryoprobe was placed inside the nidus of the lesion **b**. The day after the procedure the patient was free of pain. MRI on the second day after the procedure showed no contrast enhancement of the nidus of lesion (arrow), but there was some peristal and soft tissue swelling with moderate contrast enhancement at the rim of the ablated area (arrowheads, **c**).

patients who underwent MRI-guided cryoablation of the entire prostate. With technical success in 10/11 patients, only one major complication with a spontaneously healing rectourethral fistula occurred [71]. Bomers et al. reported similar data regarding focal MRI-guided cryoablation in the case of relapse after radiation therapy of prostate cancer. A current study regarding MRI-guided cryoablation in the case of relapse after radiation therapy in 47 patients shows control of the disease in only 24 (51%) of the patients after 12 months while residual or recurrent tumor was detected in the remaining 23 patients [72]. Initial data regarding the use of focal MRI-guided cryoablation as the primary treatment in patients with low to average risk showed a technical success rate of 100% in 10 patients and primary clinical success in 9/10 patients (► **Fig. 1**). One patient required reintervention due to initially incomplete ablation [73].

### Miscellaneous

Successful use of cryoablation in oncology for treating malignancies of the adrenal gland or in the head-neck region has also been described [74, 75]. Particularly in a palliative indication, the low morbidity is an advantage of local ablative therapies.

Cryoablation of the pancreas deserves special attention. This organ represents a particular challenge due to specific and serious complication risks. Cryoablation with the preservation of fibroblasts and thus connective tissue structures provides an at least theoretical advantage over other ablative techniques. The first clinical case series regarding pancreatic cryoablation was already reported in 1991 [76]. Since then, numerous reports on this topic have been published. For example, in a retrospective series including 32 patients with advanced pancreatic cancer, Niu et al. report a 1-year overall survival rate of 59.7% after cryoablation of the pancreas. The positive side effects such as reduction of pain medication (22/32) and improvement of the Karnofsky Index (16/32) are particularly important [77]. A current overview describes the current status of cryotherapy of the pancreas, albeit in a small clinical case series, as a notable treatment option [78].

In addition to the oncological applications described above, the successful use of cryotherapy for the treatment of numerous benign entities has also been described. Therefore, cryoablation has a success rate for example in the treatment of osteoid osteomas similar to that of other percutaneous ablation techniques with a clinical success rate of 90.5% to 100% (► **Fig. 3a–c**) [79, 80]. Case series also report the successful treatment of painful lesions such as Morton's neuromas or neuromas after amputation [81, 82]. Cryotherapy as a monotherapy or part of a combination therapy for treating vascular malformations is a newer application [83, 84]. The value of the latter indications for cryotherapy is currently still unclear since only low-quality case series have been reported. However, this shows the major potential of this type of treatment outside of typical oncological applications.

## Outlook

### Immunoablation

Since the introduction of immunotherapy in the routine treatment of various malignancies, there has been significant interest in the immune-modulating effects of cryoablation. These are ultimately due to the fact that antigenic material remains in the body after local ablation. Necrotic tissue releases damage-associated molecular patterns (DAMPs). These include heat-shock proteins, S100 proteins, non-protein components, and nucleic acids. Various immunostimulation pathways are activated via dendritic cells that phagocytize these DAMPs. This is also referred to as in-vivo dendritic cell vaccine by some authors [85]. Cryoablation produces the strongest immune-stimulating response as shown by interleukins or tumor necrosis factor- $\alpha$  (TNF- $\alpha$ ) [86]. However, the resulting apoptosis also has an immunosuppressive effect [87].

Experiments involving various combinations of cryoablation and immunotherapy have already been performed. Therefore, it was able to be shown in melanomas in a mouse model that the combination of cryotherapy and CpG-B oligodeoxynucleotides results in significantly more effective tumor control and even regression of

secondary tumors compared to monotherapy [85]. Similar results could also be shown for the combination of cryoablation with Imliquimod, a TLR7 agonist and stimulator of dendritic cells [88]. The combination of CTLA-4 antibodies and cryoablation also improves the treatment result [89]. The combination of cryotherapy and cyclophosphamide yielded a survival advantage in colorectal cancer in a mouse model. Suppression of regulatory T-cells with an increase in tumor-specific T-cells was detected [90]. The combination of cryoablation and anti-CTD25 antibodies also has a synergistic effect resulting in prolonged survival in the animal model [89].

Initial clinical data regarding cryoimmunotherapy of pancreatic cancer is promising [91]. The examination of these effects and transfer to the clinical routine represent important challenges for the near future of local ablation.

## Combination therapy

Due to the decreasing effectiveness of cryotherapy with respect to the periphery with only partial cell destruction in the range of -20 to 0 °C with simultaneous reparative processes with hyperemia and inflammation, this is the ideal target region for combination therapies. Only minimal data in this regard is currently available. Various experimental approaches were used to examine the combination of cryotherapy and systemic chemotherapy. A combination effect in terms of improved survival in the animal model was seen for various substances, e. g. for cyclophosphamide and 5-fluorouracil [90, 92]. With synchronized administration in contrast to preinterventional administration, trapping of the substance in the cryolesion could be shown for peplomycin and bleomycin [93, 94]. Combination therapy similar to electrochemotherapy also seems possible since local cryoablation in melanoma cells results in an increase in the permeability of cell walls for bleomycin [95].

A survival advantage of a combination of cryotherapy and chemotherapy in colorectal cancer compared to chemotherapy alone could be shown in a clinical case series in the case of metastasized colorectal cancer [96].

Combination with transarterial techniques has only been insufficiently examined. A large series regarding cryotherapy of colorectal liver metastases combined cryotherapy with TACE in 280 of 526 patients with liver metastases of colorectal tumors treated with cryotherapy. The local progression rate after 32 months was 6.4% [97]. Further promising reports regarding combination therapy for sarcomas are available [98]. Although this combination therapy is an obvious combination based on experience with hyperthermic ablation techniques, there is insufficient data regarding the evaluation of these therapies.

Cryotherapy also has the potential to increase the radiosensitivity of various tissues. This has been known for some time from in-vitro studies [99] and was clinically confirmed also for pancreatic and lung cancer in small case series [100, 101].

## Summary

In summary, there is now sufficient evidence to justify the use of percutaneous cryotherapy as an effective and relatively pain-free treatment alternative to surgical or other percutaneous treatment techniques. The good visualization of the ice ball in cryotherapy

improves control compared to other ablative techniques and also offers the potential to effectively and safely treat tumors in critical locations. However, there are still no prospective randomized studies with respect to the effectiveness of this type of treatment compared to surgical methods and to combination with systemic chemotherapy or immunotherapy. For combination therapy and particularly immunoablation, the available data indicates a significant advantage for patients.

## Conflict of Interest

The authors declare that they have no conflict of interest.

## References

- [1] Gage AA. History of cryosurgery. *Semin Surg Oncol* 1998; 14: 99–109
- [2] Arnott J. Practical illustrations of the remedial efficacy of a very low or anaesthetic temperature. I. In cancer. *Lancet* 1850; 2: 257–259
- [3] Pusey WA. The use of carbon dioxide snow in the treatment of nevi and other lesions of the skin. *J Am Med Assoc* 1907; 49: 1354–1356
- [4] Cooper IS, Lee A. Cryostatic congelation: a system for producing a limited controlled region of cooling or freezing of biologic tissues. *J Nerv Ment Dis* 1961; 133: 259–263
- [5] Torre D. Alternate cryogens for cryosurgery. *J Dermatol Surg* 1975; 1: 56–58
- [6] Gage AA, Baust J. Mechanisms of tissue injury in cryosurgery. *Cryobiology* 1998; 37: 171–186
- [7] Hoffmann NE, Bischof JC. The cryobiology of cryosurgical injury. *Urology* 2002; 60 (Suppl. 1): 40–49
- [8] Wen J, Duan Y, Zou Y et al. Cryoablation induces necrosis and apoptosis in lung adenocarcinoma in mice. *Technol Cancer Res Treat* 2007; 6: 635–640
- [9] Gage AA, Baust JM, Baust JG. Experimental cryosurgery investigations in vivo. *Cryobiology* 2009; 59: 229–243
- [10] Shepherd JP, Dawber RP. Wound healing and scarring after cryosurgery. *Cryobiology* 1984; 21: 157–169
- [11] Gage AA, Guest K, Montes M et al. Effect of varying freezing and thawing rates in experimental cryosurgery. *Cryobiology* 1985; 22: 175–182
- [12] Wansapura JP, Daniel BL, Vigen KK et al. In vivo MR thermometry of frozen tissue using R2\* and signal intensity. *Acad Radiol* 2005; 12: 1080–1084
- [13] Janzen NK, Perry KT, Han KR et al. The effects of intentional cryoablation and radio frequency ablation of renal tissue involving the collecting system in a porcine model. *J Urol* 2005; 173: 1368–1374
- [14] Whittaker DK. Degeneration and regeneration of nerves following cryosurgery. *Br J Exp Pathol* 1974; 55: 595–600
- [15] Beazley RM, Bagley DH, Ketcham AS. The effect of cryosurgery on peripheral nerves. *J Surg Res* 1974; 16: 231–234
- [16] Seifert JK, Morris DL. World survey on the complications of hepatic and prostate cryotherapy. *World J Surg* 1999; 23: 109–114
- [17] Breen DJ, Bryant TJ, Abbas A et al. Percutaneous cryoablation of renal tumours: outcomes from 171 tumours in 147 patients. *BJU Int* 2013; 112: 758–765
- [18] Georgiades CS, Rodriguez R. Efficacy and safety of percutaneous cryoablation for stage 1A/B renal cell carcinoma: results of a prospective, single-arm, 5-year study. *Cardiovasc Intervent Radiol* 2014; 37: 1494–1499
- [19] Jiang K, Tang K, Guo X et al. Laparoscopic cryoablation vs. percutaneous cryoablation for treatment of small renal masses: a systematic review and meta-analysis. *Oncotarget* 2017; 8: 27635–27644
- [20] Ko YH, Park HS, Moon duG et al. A matched-cohort comparison of laparoscopic renal cryoablation using ultra-thin cryoprobes with open



- partial nephrectomy for the treatment of small renal cell carcinoma. *Cancer Res Treat* 2008; 40: 184–189
- [21] Goyal J, Verma P, Sidana A et al. Single-center comparative oncologic outcomes of surgical and percutaneous cryoablation for treatment of renal tumors. *J Endourol* 2012; 26: 1413–1419
- [22] Thompson RH, Atwell T, Schmit G et al. Comparison of partial nephrectomy and percutaneous ablation for cT1 renal masses. *Eur Urol* 2015; 67: 252–259
- [23] Atwell TD, Vlaminck JJ, Boorjian SA et al. Percutaneous cryoablation of stage T1b renal cell carcinoma: technique considerations, safety, and local tumor control. *J Vasc Interv Radiol* 2015; 26: 792–799
- [24] Moynagh MR, Schmit GD, Thompson RH et al. Percutaneous cryoablation of clinical T2 (≥7 cm) renal masses: technical considerations, complications, and short-term outcomes. *J Vasc Interv Radiol* 2015; 26: 800–806
- [25] Wang C, Wang H, Yang W et al. Multicenter randomized controlled trial of percutaneous cryoablation versus radiofrequency ablation in hepatocellular carcinoma. *Hepatology* 2015; 61: 1579–1590
- [26] Ei S, Hibi T, Tanabe M et al. Cryoablation provides superior local control of primary hepatocellular carcinomas of >2 cm compared with radiofrequency ablation and microwave coagulation therapy: an underestimated tool in the toolbox. *Ann Surg Oncol* 2015; 22: 1294–1300
- [27] Wu S, Hou J, Ding Y et al. Cryoablation versus radiofrequency ablation for hepatic malignancies: a systematic review and literature-based analysis. *Med (Baltimore)* 2015; 94: e2252
- [28] Zhou L, Yang YP, Feng YY. Efficacy of argon-helium cryosurgical ablation on primary hepatocellular carcinoma: a pilot clinical study. *Ai Zheng* 2009; 28: 45–48
- [29] Chen HW, Lai EC, Zhen ZJ et al. Ultrasound-guided percutaneous cryotherapy of hepatocellular carcinoma. *Int J Surg* 2011; 9: 188–191
- [30] Littrup PJ, Aoun HD, Adam B et al. Percutaneous cryoablation of hepatic tumors: long-term experience of a large U. S. series. *Abdom Radiol (NY)* 2016; 41: 767–780
- [31] Glazer DI, Tatli S, Shyn PB et al. Percutaneous Image-Guided Cryoablation of Hepatic Tumors: Single-Center Experience With Intermediate to Long-Term Outcomes. *Am J Roentgenol* 2017; 209: 1381–1389
- [32] Bang HJ, Littrup PJ, Currier BP et al. Percutaneous Cryoablation of Metastatic Lesions from Colorectal Cancer: Efficacy and Feasibility with Survival and Cost-Effectiveness Observations. *ISRN Minim Invasive Surg* 2012: 2012
- [33] Zhang W, Yu H, Guo Z et al. Percutaneous cryoablation of liver metastases from breast cancer: initial experience in 17 patients. *Clin Radiol* 2014; 69: 231–238
- [34] Gao W, Guo Z, Zhang X et al. Percutaneous cryoablation of ovarian cancer metastasis to the liver: initial experience in 13 patients. *Int J Gynecol Cancer* 2015; 25: 802–808
- [35] Bilchik AJ, Sarantou T, Foshag LJ et al. Cryosurgical palliation of metastatic neuroendocrine tumors resistant to conventional therapy. *Surgery* 1997; 122: 1040–1048
- [36] Zemlyak A, Moore WH, Bilfinger TV. Comparison of survival after sublobar resections and ablative therapies for stage I non-small cell lung cancer. *J Am Coll Surg* 2010; 211: 68–72
- [37] Moore W, Talati R, Bhattacharji P et al. Five-year survival after cryoablation of stage I non-small cell lung cancer in medically inoperable patients. *J Vasc Interv Radiol* 2015; 26: 312–319
- [38] Niu L, Chen J, Yao F et al. Percutaneous cryoablation for stage IV lung cancer: a retrospective analysis. *Cryobiology* 2013; 67: 151–155
- [39] de Baere T, Tselikas L, Woodrum D et al. Evaluating Cryoablation of Metastatic Lung Tumors in Patients—Safety and Efficacy: The ECLIPSE Trial—Interim Analysis at 1 Year. *J Thorac Oncol* 2015; 10: 1468–1474
- [40] Liu S, Ren R, Liu M et al. MR imaging-guided percutaneous cryotherapy for lung tumors: initial experience. *J Vasc Interv Radiol* 2014; 25: 1456–1462
- [41] Chou HP, Chen CK, Shen SH et al. Percutaneous cryoablation for inoperable malignant lung tumors: midterm results. *Cryobiology* 2015; 70: 60–65
- [42] Yamauchi Y, Izumi Y, Kawamura M et al. Percutaneous cryoablation of pulmonary metastases from colorectal cancer. *PLoS One* 2011; 6: e27086
- [43] McDevitt JL, Mouli SK, Nemcek AA et al. Percutaneous Cryoablation for the Treatment of Primary and Metastatic Lung Tumors: Identification of Risk Factors for Recurrence and Major Complications. *J Vasc Interv Radiol* 2016; 27: 1371–1379
- [44] Edwards MJ, Broadwater R, Tafra L et al. Progressive adoption of cryoablative therapy for breast fibroadenoma in community practice. *Am J Surg* 2004; 188: 221–224
- [45] Kaufman CS, Littrup PJ, Freman-Gibb LA et al. Office-based cryoablation of breast fibroadenomas: 12-month followup. *J Am Coll Surg* 2004; 198: 914–923
- [46] Sabel MS, Kaufman CS, Whitworth P et al. Cryoablation of early-stage breast cancer: work-in-progress report of a multiinstitutional trial. *Ann Surg Oncol* 2004; 11: 542–549
- [47] Pfeleiderer SO, Freesmeyer MG, Marx C et al. Cryotherapy of breast cancer under ultrasound guidance: initial results and limitations. *Eur Radiol* 2002; 12: 3009–3014
- [48] Mauri G, Sconfienza LM, Pescatori LC et al. Technical success, technique efficacy and complications of minimally-invasive imaging-guided percutaneous ablation procedures of breast cancer: A systematic review and meta-analysis. *Eur Radiol* 2017; 27: 3199–3210
- [49] Simmons RM, Ballman KV, Cox C et al. A phase II trial exploring the success of cryoablation therapy in the treatment of invasive breast carcinoma: results from ACOSOG (Alliance) Z1072. *Ann Surg Oncol* 2016; 23: 2438–2445
- [50] Cazzato RL, de Lara CT, Buy X et al. Single-centre experience with percutaneous cryoablation of breast cancer in 23 consecutive nonsurgical patients. *Cardiovasc Interv Radiol* 2015; 38: 1237–1243
- [51] Greenway RM, Schlossberg L, Dooley WC. Fifteen-year series of skin-sparing mastectomy for stage 0 to 2 breast cancer. *Am J Surg* 2005; 190: 918–922
- [52] Tomasian A, Wallace A, Northrup B et al. Spine cryoablation: pain palliation and local tumor control for vertebral metastases. *Am J Neuroradiol* 2016; 37: 189–195
- [53] Callstrom MR, Dupuy DE, Solomon SB et al. Percutaneous image-guided cryoablation of painful metastases involving bone: multicenter trial. *Cancer* 2013; 119: 1033–1041
- [54] Prologo JD, Passalacqua M, Patel I et al. Image-guided cryoablation for the treatment of painful musculoskeletal metastatic disease: a single-center experience. *Skeletal Radiol* 2014; 43: 1551–1559
- [55] Li F, Wang W, Li L et al. An effective therapy to painful bone metastases: cryoablation combined with zoledronic acid. *Pathol Oncol Res* 2014; 20: 885–891
- [56] Tsoumakidou G, Too CW, Garnon J et al. Treatment of a spinal aneurysmal bone cyst using combined image-guided cryoablation and cementoplasty. *Skeletal Radiol* 2015; 44: 285–289
- [57] Griaudze J, Gemmete JJ, Farley F. Successful treatment of a Musculoskeletal Tumor Society grade 3 aneurysmal bone cyst with N-butyl cyanoacrylate embolization and percutaneous cryoablation. *J Vasc Interv Radiol* 2015; 26: 905–909
- [58] Havez M, Lippa N, Al-Ammari S et al. Percutaneous image-guided cryoablation in inoperable extra-abdominal desmoid tumors: a study of tolerability and efficacy. *Cardiovasc Interv Radiol* 2014; 37: 1500–1506
- [59] Schmitz JJ, Schmit GD, Atwell TD et al. Percutaneous cryoablation of extraabdominal desmoid tumors: a 10-year experience. *Am J Roentgenol* 2016; 207: 190–195
- [60] Fan W, Niu L, Wang Y et al. Percutaneous computed tomography-guided cryoablation for recurrent retroperitoneal soft tissue sarcoma: a study of safety and efficacy. *Oncotarget* 2016; 7: 42639–42649

- [61] Fan WZ, Niu LZ, Wang Y et al. Initial Experience: Alleviation of Pain with Percutaneous CT-Guided Cryoablation for Recurrent Retroperitoneal Soft-Tissue Sarcoma. *J Vasc Interv Radiol* 2016; 27: 1798 – 1805
- [62] McMenemy BP, Kurup AN, Johnson GB et al. Percutaneous cryoablation of musculoskeletal oligometastatic disease for complete remission. *J Vasc Interv Radiol* 2013; 24: 207 – 213
- [63] Littrup PJ, Bang HJ, Currier BP et al. Soft-tissue cryoablation in diffuse locations: feasibility and intermediate term outcomes. *J Vasc Interv Radiol* 2013; 24 (12): 1817 – 1825
- [64] Deschamps F, Farouil G, Ternès N et al. Thermal ablation techniques: a curative treatment of bone metastases in selected patients? *Eur Radiol* 2014; 24: 1971 – 1980
- [65] Silva RD, Kim FJ. Focal Cryotherapy in Low-Risk Prostate Cancer: Are We Treating the Cancer or the Mind? – The Cancer. *Int Braz J Urol* 2015; 41: 5 – 9
- [66] Reis LO, Carter HB. The Mind: Focal Cryotherapy in Low-Risk Prostate Cancer: Are We Treating the Cancer or the Mind? *Int Braz J Urol* 2015; 41: 10 – 14
- [67] Stephenson AJ, Scardino PT, Bianco FJ Jr et al. Morbidity and functional outcomes of salvage radical prostatectomy for locally recurrent prostate cancer after radiation therapy. *J Urol* 2004; 172: 2239 – 2243
- [68] Ward JF, Jones JS. Focal cryotherapy for localized prostate cancer: a report from the national Cryo On-Line Database (COLD) Registry. *BJU Int* 2012; 109: 1648 – 1654
- [69] Valerio M, Cerantola Y, Eggenner SE et al. New and Established Technology in Focal Ablation of the Prostate: A Systematic Review. *Eur Urol* 2017; 71: 17 – 34
- [70] Pisters LL, Rewcastle JC, Donnelly BJ et al. Salvage prostate cryoablation: initial results from the cryo on-line data registry. *J Urol* 2008; 180: 559 – 564
- [71] Gangi A, Tsoumakidou G, Abdelli O et al. Percutaneous MR-guided cryoablation of prostate cancer: initial experience. *Eur Radiol* 2012; 22: 1829 – 1835
- [72] Overduin CG, Jenniskens SFM, Sedelaar JPM et al. Percutaneous MR-guided focal cryoablation for recurrent prostate cancer following radiation therapy: retrospective analysis of iceball margins and outcomes. *Eur Radiol* 2017; 27: 4828 – 4836
- [73] Figiel J, Koenig A, Hegele A et al. MRI-guided percutaneous transgluteal ablation of unilateral prostate carcinoma: initial experiences and results. *Insights into Imaging* 2018; 9 (Suppl. 1): S 228
- [74] Welch BT, Atwell TD, Nichols DA et al. Percutaneous image-guided adrenal cryoablation: procedural considerations and technical success. *Radiology* 2011; 258: 301 – 307
- [75] Guenette JP, Tuncali K, Himes N et al. Percutaneous Image-Guided Cryoablation of Head and Neck Tumors for Local Control, Preservation of Functional Status, and Pain Relief. *Am J Roentgenol* 2017; 208: 453 – 458
- [76] Patiutko Iul, Barkanov AI, Kholikov TK et al. The combined treatment of locally disseminated pancreatic cancer using cryosurgery. *Vopr Onkol* 1991; 37: 695 – 700 [Russisch]
- [77] Niu L, He L, Zhou L et al. Percutaneous ultrasonography and computed tomography guided pancreatic cryoablation: feasibility and safety assessment. *Cryobiology* 2012; 65: 301 – 307
- [78] Luo XM, Niu LZ, Chen JB et al. Advances in cryoablation for pancreatic cancer. *World J Gastroenterol* 2016; 22: 790 – 800
- [79] Coupal TM, Mallinson PI, Munk PL et al. CT-guided percutaneous cryoablation for osteoid osteoma: initial experience in adults. *Am J Roentgenol* 2014; 202: 1136 – 1139
- [80] Whitmore MJ, Hawkins CM, Prologo JD et al. Cryoablation of Osteoid Osteoma in the Pediatric and Adolescent Population. *J Vasc Interv Radiol* 2016; 27: 232 – 237
- [81] Cazzato RL, Garnon J, Ramamurthy N et al. Percutaneous MR-Guided Cryoablation of Morton's Neuroma: Rationale and Technical Details After the First 20 Patients. *Cardiovasc Intervent Radiol* 2016; 39: 1491 – 1498
- [82] Prologo JD, Gilliland CA, Miller M et al. Percutaneous Image-Guided Cryoablation for the Treatment of Phantom Limb Pain in Amputees: A Pilot Study. *J Vasc Interv Radiol* 2017; 28: 24 – 34.e4
- [83] Cornelis F, Havez M, Labrèze C. Percutaneous cryoablation of symptomatic localized venous malformations: preliminary short-term results. *J Vasc Interv Radiol* 2013; 24: 823 – 827
- [84] Woolen S, Gemmete JJ. Treatment of Residual Facial Arteriovenous Malformations after Embolization with Percutaneous Cryotherapy. *J Vasc Interv Radiol* 2016; 27: 1570 – 1575
- [85] den Brok MH, Suttmuller RP, Nierkens S et al. Synergy between in situ cryoablation and TLR9 stimulation results in a highly effective in vivo dendritic cell vaccine. *Cancer Res* 2006; 66: 7285 – 7292
- [86] Mehta A, Oklu R, Sheth RA. Thermal Ablative Therapies and Immune Checkpoint Modulation: Can Locoregional Approaches Effect a Systemic Response? *Gastroenterol Res Pract* 2016; 2016: 9251375
- [87] Chu KF, Dupuy DE. Thermal ablation of tumours: biological mechanisms and advances in therapy. *Nat Rev Cancer* 2014; 14: 199 – 208
- [88] Redondo P, del Olmo J, López-Díaz de Cerio A et al. Imiquimod enhances the systemic immunity attained by local cryosurgery destruction of melanoma lesions. *J Invest Dermatol* 2007; 127: 1673 – 1680
- [89] den Brok MH, Suttmuller RP, Nierkens S et al. Efficient loading of dendritic cells following cryo and radiofrequency ablation in combination with immune modulation induces anti-tumour immunity. *Br J Cancer* 2006; 95: 896 – 905
- [90] Levy MY, Sidana A, Chowdhury WH et al. Cyclophosphamide unmasks an antimetastatic effect of local tumor cryoablation. *J Pharmacol Exp Ther* 2009; 330: 596 – 601
- [91] Niu L, Chen J, He L et al. Combination treatment with comprehensive cryoablation and immunotherapy in metastatic pancreatic cancer. *Pancreas* 2013; 42: 1143 – 1149
- [92] Le Pivert PJ, Morrison DR, Haddad RS et al. Percutaneous tumor ablation: microencapsulated echo-guided interstitial chemotherapy combined with cryosurgery increases necrosis in prostate cancer. *Technol Cancer Res Treat* 2009; 8: 207 – 216
- [93] Benson JW. Regional chemotherapy and local cryotherapy for cancer. *Oncology* 1972; 26: 134 – 151
- [94] Homasson JP, Pecking A, Roden S et al. Tumor fixation of bleomycin labeled with 57 cobalt before and after cryotherapy of bronchial carcinoma. *Cryobiology* 1992; 29: 543 – 548
- [95] Mir LM, Rubinsky B. Treatment of cancer with cryochemotherapy. *Br J Cancer* 2002; 86: 1658 – 1660
- [96] Li Z, Fu Y, Li Q et al. Cryoablation plus chemotherapy in colorectal cancer patients with liver metastases. *Tumour Biol* 2014; 35: 10841 – 10848
- [97] Xu KC, Niu LZ, He WB et al. Percutaneous cryosurgery for the treatment of hepatic colorectal metastases. *World J Gastroenterol* 2008; 14: 1430 – 1436
- [98] Khanevich MD, Manikhas GM, Vashkurov SM et al. Combination of vessel embolization and cryotherapy in surgical treatment of soft tissue sarcomas. *Vestn Khir Im I I Grek* 2015; 174: 39 – 44 [Russisch]
- [99] Burton SA, Paljug WR, Kalnicki S et al. Hypothermia-enhanced human tumor cell radiosensitivity. *Cryobiology* 1997; 35: 70 – 78
- [100] Niu L, Zhou L, Xu K et al. Combination of cryosurgery and Iodine-125 seeds brachytherapy for lung cancer. *J Thorac Dis* 2012; 4: 504 – 507
- [101] Xu K, Niu L, Mu F et al. Cryosurgery in combination with brachytherapy of iodine-125 seeds for pancreatic cancer. *Gland Surg* 2013; 2: 91 – 99

