



Original Article

The significance of retroflexion technique in the right colon on adenoma detection rates during colonoscopy



Mohamed S. EL Shahawy *, Mohamed EL Fayoumy

AL-Azhar University, Faculty of Medicine, Gastroenterology Unit, Cairo, Egypt

ARTICLE INFO

Article history:

Received 1 April 2019

Accepted 27 May 2019

Available online 21 June 2019

Keywords:

Colonoscopy

Forward view

Retroflexed view

Adenoma

ABSTRACT

Background and aim: Right colon adenomas can easily missed with significant adenoma miss rate particularly when they are located behind the haustral folds and anatomical flexures. The aim of this study was to assess the significance of retroflexion technique in the right colon for improving adenoma detection rates compared with forward-view technique.

Methods: A total of 200 patients scheduled for elective colonoscopy were recruited. During the standard forward-view examination, the colonoscope was withdrawn from the cecum to the hepatic flexure while under meticulous observation. Subsequently, the cecum was reintubated and the right side of the colon was assessed in the retroflexed-view to the hepatic flexure. The primary outcome of this study was comparison of the adenoma detection rates and adenoma miss rate of the retroflexed-view versus forward-view examination of the right colon.

Results: Of the 200 enrolled patients, retroflexion was successful in 182 (91%). Forward-view examination of the right colon detected 88 polyps, of which 66 were adenomas yielding a polyp and adenoma detection rates of 25.5% and 19%, respectively. Additionally, retroflexion detected a further 30 polyps of which 23 were adenomas, accordingly improving the polyp and adenoma detection rates to 29.5% and 25%, respectively. Furthermore, the polyp and adenoma miss rate in the right colon was 24.1% and 25.8% respectively.

Conclusion: Colonoscopy with right-sided retroflexion after forward-view examination significantly increases the detection of adenomas compared with standard forward-view examination with a high success rate and small risk of adverse events.

© 2019 Sociedade Brasileira de Coloproctologia. Published by Elsevier Editora Ltda. This is an open access article under the CC BY-NC-ND license (<http://creativecommons.org/licenses/by-nc-nd/4.0/>).

* Corresponding author.

E-mail: tep_alshahawy@yahoo.com (M.S. Shahawy).

<https://doi.org/10.1016/j.jcol.2019.05.009>

2237-9363/© 2019 Sociedade Brasileira de Coloproctologia. Published by Elsevier Editora Ltda. This is an open access article under the CC BY-NC-ND license (<http://creativecommons.org/licenses/by-nc-nd/4.0/>).

O significado da técnica de retroflexão no cólon direito nas taxas de detecção de adenomas durante a colonoscopia

R E S U M O

Palavras-chave:

Colonoscopia

Visualização frontal

Visualização retroflexionada

Adenoma

Antecedentes e objetivo: Os adenomas do cólon direito podem não ser diagnosticados, apresentando uma elevada taxa de não detecção de adenoma, especialmente quando estão localizados atrás das pregas haustrais e flexões anatômicas. O objetivo deste estudo foi comparar, no cólon direito, a técnica de visualização retroflexionada com a técnica de visualização frontal quanto à taxa de detecção de adenoma.

Métodos: Um total de 200 pacientes agendados para colonoscopia eletiva foram recrutados para o presente estudo. Durante o exame de visualização frontal padrão, o colonoscópio foi retirado do ceco em direção à flexão hepática sob observação meticulosa. Posteriormente, o ceco foi reintubado e o lado direito do cólon foi avaliado na visualização retroflexionada em direção à flexão hepática. O objetivo primário deste estudo foi comparar a taxa de detecção de adenoma e a taxa de não detecção de adenoma do exame de visualização retroflexionada e visualização frontal do cólon direito.

Resultados: Dos 200 pacientes inscritos, a retroflexão foi bem sucedida em 182 (91%). A visualização frontal do cólon direito detectou 88 pólipos, dos quais 66 eram adenomas, com uma taxa de detecção de pólipos e taxa de detecção de adenoma de 25,5% e 19%, respectivamente. Além disso, a visualização retroflexionada detectou mais 30 pólipos, dos quais 23 eram adenomas, aumentando a taxa de detecção de pólipos e adenoma para 29,5% e 25%, respectivamente. Além disso, a taxa não detecção de pólipos e a taxa de não detecção de adenoma no cólon direito foram de 24,1% e 25,8%, respectivamente.

Conclusão: A colonoscopia com visualização retroflexionada direita após visualização frontal aumenta significativamente a detecção de adenomas em comparação com a visualização frontal padrão, com uma alta taxa de sucesso e baixo risco de eventos adversos.

© 2019 Sociedade Brasileira de Coloproctologia. Publicado por Elsevier Editora Ltda. Este é um artigo Open Access sob uma licença CC BY-NC-ND (<http://creativecommons.org/licenses/by-nc-nd/4.0/>).

Introduction

Colonoscopy has been established as the gold standard for the screening of Colorectal Cancer (CRC). To help reduce the known variations in colonoscopy quality that exist from provider to provider, quality indicators have been established. Good quality indicators that have been established include the endoscopist's ADR, a reportable rate of the endoscopist's ability to find adenomas, attempt of endoscopic removal of pedunculated polyps and large (<2 cm) sessile polyps prior to surgical referral and cecal intubation. The endoscopist's ADR currently stands as the "gold standard" for quality measures in screening colonoscopy. The benchmark for ADRs is 25% overall, 30% in men, and 20% in women.¹ The adenoma-to-carcinoma sequence in colorectal carcinogenesis specifically refers to the development of cancers in the colorectum through an intermediate neoplastic step, known as adenoma. The neoplastic step includes tubular, tubular villous and villous adenomas. All adenomas are dysplastic by their nature but present with varying degrees of dysplasia. Therefore, the screening and removal of adenomatous polyps can effectively prevent CRC.² Despite reports indicating that colonoscopy and polypectomy can prevent up to 80% of colorectal cancers³ Colonoscopy is therefore an imperfect test with well-described adenoma miss rate identified across the medical literature, with reported rates between 15% and 27%,

particularly for diminutive polyps (≤ 5 mm).⁴ Previous studies, however, have reported that colonoscopy is less effective in preventing proximal CRC compared to distal CRC.⁵ Possible explanations for this discrepancy include differences in tumor biology and polyp morphology with right-sided lesions having faster growth rates and flatter polyp profiles making them harder to identify endoscopically.⁶ Moreover, right colon lesions especially tend to be missed when they are located behind the haustral folds and anatomical flexures as these are considered to be blind spots.⁷ As a result, research has focused on advancing colonoscopy technology to improve visualization and adenoma detection with wide-angle colonoscopy, third eye retroscope, full spectrum endoscopy, and cap-fitted colonoscopy.⁸ Reducing the adenoma miss rate in the right colon has become a pressing issue. Retroflexion of the colonoscope is a technique that has been suggested to improve visualization in the right colon, and refers to making a U-turn with the bending section of the colonoscope so that the viewing lens is looking backward.⁹ The use of retroflexion in the right colon makes it possible to observe the colon mucosa through a different angle. Previous studies that examined the impact of using the RV when performing second examinations from the cecum to the hepatic flexure have shown that this technique yields about an additional 10% of identified polyps. The benefit of this technique has been reported to be equal to that of performing a second examination using the FV.⁷ However, controversy remains over whether or not right colon

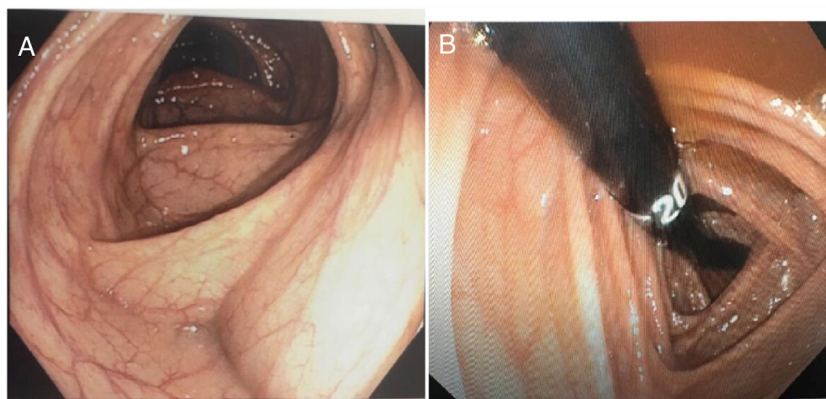


Fig. 1 – (A) Forward-view examination of the right colon and (B) retroflexed-view examination of the right colon.

retroflexion leads to significantly improved adenoma detection in the context of concerns about procedural safety and retroflexion maneuver success. Therefore, we conducted this study to assess the significance of retroflexion technique in the right colon for improving adenoma detection rates compared with FV technique.

Materials and methods

This prospective, observational study was conducted at EL-Hussein university hospital, AL-Azhar University, Cairo, Egypt between October 2018 and February 2019. This study was approved by ethical committee of AL-Azhar University and all study subjects provided informed consent.

Study design

Adult patient's ≥ 18 years old and scheduled for screening, surveillance or diagnostic colonoscopy were eligible for recruitment. Inclusion criteria also included complete colonoscopy (colonoscopy advanced to the cecum or ileum) and satisfactory bowel preparation (Boston bowel preparation scale ≥ 2).¹⁰ Patients were excluded if they could not be intubated to the cecum, had underlying inflammatory bowel disease, familial adenomatous polyposis, or Lynch syndrome, previous surgical resection of the right colon, anticoagulants therapy and finally had inadequate quality of bowel preparation (Boston Bowel Preparation Scale score < 2).

Endoscopic evaluation

The instruments used in this study were adult high-definition, wide-angle colonoscope and an electronic endoscopic system (Olympus EVIS Lucera Ellit CV-290; Olympus Medical Systems, Tokyo, Japan). All patients were offered conscious sedation with intravenous Midazolam (2.5–5 mg) and/or pethidine (25–125 mg). All of the endoscopic examinations were performed by one senior endoscopist with more than 10 years experiences in diagnostic and therapeutic endoscopy. Before undergoing the colonoscopy, all patients followed a standard bowel cleansing protocol using 1–2L of high concentrated polyethylene glycol-electrolyte solution. The quality of the

bowel preparation in the right colon was assessed according to the Boston Bowel Preparation Scale score. During the standard FV, the colonoscope was withdrawn from the cecum to the hepatic flexure while under meticulous observation and all visualized polyps were resected. Subsequently, the cecum was reintubated and the right side of the colon was assessed in the RV to the hepatic flexure. Retroflexion was done while the colonoscope tip in or near the cecum by turning the dials to the maximum up and maximum left directions. The bending section will now be hairpinned in the up–down deflection plane then rotation of the colonoscope insertion tube counter-clockwise to enter retroflexion then inspection is conducted as the instrument is withdrawn toward the hepatic flexure (Fig. 1). Once the right side of the colon was examined in retroflexion to the hepatic flexure, the retroflexion is reversed by releasing the up–down and right–left controls and simultaneously withdrawing the insertion tube, so that the bending section exerts minimal pressure on the colon wall as it unwinds. All resected tissues were collected for histopathological evaluation.

Outcome measures

The primary outcome of this study was comparison of the ADR and AMR of the RV versus FV examination. The ADR was calculated as the proportion of patients with at least one adenoma in each group. The adenoma miss rate was calculated by determining the proportion of total number of adenomas detected in the right colon on FV and the total number of additional adenomas detected during retroflexion. Thus, we calculated as the primary metameter of per-adenoma miss rate of the right colon as the number of additional adenomas in right colon detected by RV divided by the total adenomas in right colon detected with FV plus RV. Our secondary outcomes included the success rate of retroflexion, polyp detection and miss rates as well as adverse event rates.

Statistical analysis

All data were stored on a spreadsheet (Microsoft Office Excel, Microsoft, Redmond, Washington, United States), and all analyses were performed as intention-to-treat using statistical software Stata, version 10. Continuous variables

Table 1 – Baseline demographics.

Characteristic	
Age (years), mean \pm SD	37.64 \pm 15.52
Gender	
Male, n (%)	118 (59%)
Female, n (%)	82 (41%)
BMI	31.5 \pm 4.5
Smoking, n (%)	60 (30%)
DM	40 (20%)
Indication	
Anemia, n (%)	90 (45%)
Hematochezia, n (%)	40 (20%)
Abdominal pain, n (%)	20 (10)
Constipation, n (%)	18 (9%)
Screening, n (%)	17 (8.5%)
Others, n (%)	15 (7.5%)
Withdrawal time for total procedure, mean \pm SD	7.92 \pm 5.45 min
Withdrawal time for right colon with FV, mean \pm SD	2.13 \pm 1.37 min
Withdrawal time for right colon with RV, mean \pm SD	38.28 \pm 24.68 s

SD, standard deviation; DM, diabetes mellitus; BMI, body mass index; FV, forward-view; RV, retroflexed-view.

are reported as means \pm SD and categorical variables are reported as percentages. All data analyses were performed as intention-to-treat using statistical software Stata, version 10. Continuous data were compared using the Mann-Whitney *U* test. Confidence intervals (CIs) for the difference were calculated and Categorical variables were compared using either the χ^2 test or Fisher's exact test. Odds ratios were calculated for variables that may have been associated with failure to retroflex, and Logistic regression analysis was utilized for the purpose of evaluating predictors of unsuccessful retroflexion and adenoma detection in RV. A *p*-value <0.05 was considered statistically significant.

Results

A total of 200 patients were recruited over the study period. **Table 1** presents the baseline demographic and clinical characteristics for the patients. The predominant indication for colonoscopy was anemia 45% (90/200). Retroflexion was successful in 91% (182/200) of patients however, Retroflexion was failed in 9% (18/200), the predominant reason was narrow colon (44.4%; 8/18 patients), looping (33.3%; 6/18 patients) and finally right-sided diverticular disease (22.2%; 4/18 patients). Logistic regression analysis showed that the significant predictors of unsuccessful retroflexion were poor bowel preparation quality (Odds Ratio [OR]: 1.93, 95% Confidence Interval [95% CI]: 1.04–3.47) in addition to previous abdominal surgery (OR = 2.15, 95% CI: 1.16–3.89) (*p* < 0.001).

Forward view right-sided polyp detection

A total number of 88 polyps were detected in 51 patients on FV assessment of the right side of the colon, yielding a polyp detection rate of 25.5% on an intention-to-treat analysis. The overall ADR in the FV was 38 of 200 (19%). Furthermore, the AMR of the FV examination was 25.8%. As regard to

Table 2 – Polyp and adenoma detected on forward-view and retroflexion examination.

	Forward-view	Retroflexion
Total no. of polyps	88	30
ADR	19%	25%
PDR	25.5%	29.5
AMR	25.8%	
PMR	24.1%	
Histology		
Conventional adenoma	53 (60.22%)	18 (60%)
Hyperplastic	22 (25%)	8 (26.66%)
SSA	13 (14.77%)	4 (13.33%)
Mean size \pm SD	5.2 \pm 3.4 mm	5.5 \pm 3.8 mm
Location		
Hepatic flexure	20 (22.72%)	11 (36.66%)
Ascending colon	45 (51.31%)	17 (56.66%)
Cecum	23 (26.31%)	7 (23.33%)

ADR, adenoma detection rate; PDR, polyp detection rate; AMR, adenoma miss rate; PMR, polyp miss rate; SSA, sessile serrated adenoma.

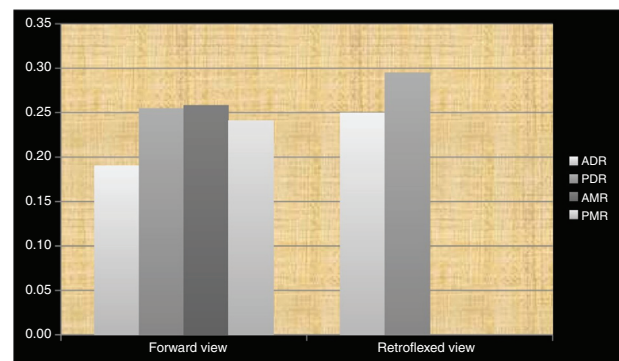


Fig. 2 – Polyp and adenoma detection and miss rates on forward-view and retroflexion examination. ADR, adenoma detection rate; PDR, polyp detection rate; AMR, adenoma miss rate; PMR, polyp miss rate.

polyps' location, 22.72% of the polyps were identified in the hepatic flexure, 51.31% in the ascending colon, and finally 26.31% at the cecum. The mean size of the polyps was 5.2 \pm 3.4 mm. Regarding histopathological assessment, 60.22% (53/88) polyps was conventional adenoma, 25% (22/88) was hyperplastic and 14.77% (13/88) was sessile serrated adenoma. The mean withdrawal time for right colon with FV was 2.13 \pm 1.37 min (**Table 2** and **Fig. 2**).

Retroflexed view right-sided polyp detection

A total of 30 polyps in 22 patients were detected in the retroflexed assessment of the right side of the colon. In 36.3% of these patients (8/22), no polyps were found on FV assessment, thus improving the polyp detection rate from 25.5% to 29.5% on an intention-to-treat analysis (*p* < 0.001). Polyps were predominantly identified in the ascending part of the right side of the colon (56.66%) then hepatic flexure 36.66% and finally in the cecum 23.33% and the mean size was

5.5 ± 3.8 mm. Polyps were characterized histologically as conventional adenomas 60% (18/30), hyperplastic 26.66% (8/30) and sessile serrated adenomas 13.33% (4/30). Adenomas were detected in 12 patients where none had been detected in the FV, thus improving the ADR from 19% to 25% ($p < 0.001$). The mean withdrawal time for right colon with RV was 38.28 ± 24.68 s (Table 2 and Fig. 2).

Adverse events

Only minor bleeding occurred in 2% (4/200) and mucosal tear in 1% (2/200). Perforation was not observed in any of the patients undergoing retroflexion.

Discussion

This study investigated the impact of using retroflexion technique in the right Colon versus the standard FV examination for improving the ADR as a primary outcome. Colonoscopy has been shown to be the diagnostic and therapeutic test-of-choice for the prevention of colon cancer. However, many studies have shown significant adenoma miss rates exist even in the most skilled endoscopists' hands and thus colonoscopy has less success preventing right-sided colon cancers.¹¹ Retroflexion in the right side of the colon may therefore identify polyps located on the proximal aspect of folds/flexures not visualized on forward-view withdrawal.¹² Endoscopists in Egypt doesn't routinely perform right-sided retroflexion during colonoscopy procedure with no enough studies regarding this technique therefore, our study aimed to evaluate RV technique and it's impact on improving the ADR. However, some adenomas could remain undetected on the proximal aspect of folds when only performing on FV examination we found additional adenomas during RV after the FV examination. Our results revealed that retroflexion was successful in 91%. Additionally, retroflexion in the right colon yielded an additional 30 polyps, of which 23 (76.66%) were adenomas across our 200 patients. The ADR was significantly improved from 19% during FV to 25% when retroflexion was also performed ($p < 0.001$). Previous work evaluating the benefit of right colon retroflexion upon adenoma detection compared with conventional colonoscopy has been discordant showing per-adenoma miss rates as low as 4.7%¹³ and as high as 33.3%¹⁴ and in this study, the adenoma miss rate of the FV examination was 25.8%. Significant predictors of the detection of at least one adenoma during the RV included older age and the presence of adenomas during the FV examination. Chandran et al., who recruited the largest number of patients, conducted a prospective cohort study with 1351 patients and five experienced endoscopists. They reported that 2.4% of patients (33/1351) had additional polyps identified on right colon retroflexion that shortened their recommended surveillance interval compared with conventional colonoscopy. Furthermore, of these, 60.6% (20/33) went from no adenomas identified on conventional colonoscopy to an additional 1–2 adenomas identified with reexamination of the right colon in retroflexed view shortening the recommended follow-up colonoscopy to 5 years as opposed to 10 years based

on most guidelines.¹⁵ This suggests that retroflexion might be necessary in order to thoroughly examine the right colon. Furthermore, our findings of an incremental increase in polyp and adenoma detection on retroflexion are in line with the 2 previous studies by Rex's group.¹⁶ In this study all endoscopic procedures was done by one senior endoscopist with more than 10 years experience with adequate retroflexion success rate (91%). Therefore, the experience of the endoscopists might affect the success rate of the retroflexion. While generalizability of adenoma detection, retroflexion success and adverse event rates may be affected by the fact that colonoscopies in many studies were performed by highly skilled endoscopists at major academic medical centers, a recent large RCT found that the overall right colon retroflexion success rate was 94% involving ten endoscopists with varying levels of experience.⁷ The colonoscopic withdrawal time, quality of bowel preparation, and optimal observation techniques of colonoscopist are important in reducing the adenoma miss rate.¹⁷ It is well known that longer withdrawal time is associated with higher adenoma detection rate.¹⁸ Since we spent 7.92 ± 5.45 min during colonoscopic withdrawal. In the present study, the mean withdrawal time for the right colon with FV examination was about 2.13 ± 1.37 min while in RV was 38.28 ± 24.68 s. Accordingly, this shorter withdrawal time, of FV and sequential RV observation might be applicable for use in daily routine practices. Novel emerging technology such as a retrograde viewing device and full-spectrum endoscopy have recently been proven to be beneficial with regard to improving the adenoma miss rate.¹⁹ However, these new modalities are currently only available at limited facilities. Retroflexion is both simple and suitable for routine applications and, thus, can be safely used in most situations. Moreover, as endoscopists need to be skilled in the use of retroflexion when resecting a polyp from behind a fold, these endoscopists should already be familiar with performing retroflexion during routine clinical practices. Finally, we believe that the optimal strategy for improving detection of right-sided adenomas is reexamination of the right colon in retroflexed view, the above-mentioned evidence strongly indicates that performing this techniques should be strongly considered in future standard of care colonoscopy quality guidelines for right-sided colon cancer prevention. This study has limitations. First, small sample size second, it was conducted at one academic medical centers and by one experienced endoscopist therefore, the results may not be applicable to the community setting.

Conclusion

Colonoscopy with right-sided retroflexion after FV examinations significantly increases the detection of adenomas in the ascending colon with a high success rate and small risk of adverse events. Furthermore, right colon retroflexion is a safe and highly effective technique for improving adenoma detection when performed by experienced endoscopists and should be strongly recommended for standard of care colonoscopy procedure for colon cancer prevention.

Conflicts of interest

The authors declare no conflicts of interest.

REFERENCES

1. Rex DK, Schoenfeld PS, Cohen J, Pike IM, Adler DG, Fennerty MB, et al. Quality indicators for colonoscopy. *Gastrointest Endosc.* 2015;81:31–53.
2. Zauber AG, Winawer SJ, O'Brien MJ, Lansdorp-Vogelaar I, van Ballegooijen M, Hankey BE, et al. Colonoscopic polypectomy and long-term prevention of colorectal-cancer deaths. *N Engl J Med.* 2012;366:687–96.
3. Citarda F, Tomaselli G, Capocaccia R, Barcherini S, Crespi M, Italian Multicentre Study Group. Efficacy in standard clinical practice of colonoscopic polypectomy in reducing colorectal cancer incidence. *Gut.* 2001;48:812–5.
4. Rex DK, Cutler CS, Lemmel GT, Rahmani EY, Clark DW, Helper DJ, et al. Colonoscopic miss rates of adenomas determined by back-to-back colonoscopies. *Gastroenterology.* 1997;112:24–8.
5. Baxter NN, Warren JL, Barrett MJ, Stukel TA, Doria-Rose VP. Association between colonoscopy and colorectal cancer mortality in a us cohort according to site of cancer and colonoscopist specialty. *J Clin Oncol.* 2012;30:2664–9.
6. Azzoni C, Bottarelli L, Campanini N, Di Cola G, Bader G, Mazzeo A, et al. Distinct molecular patterns based on proximal and distal sporadic colorectal cancer: arguments for different mechanisms in the tumorigenesis. *Int J Colorectal Dis.* 2007;22:115–26.
7. Kushnir VM, Oh YS, Hollander T, Chen CH, Sayuk GS, Davidson N, et al. Impact of retroflexion vs. second forward view examination of the right colon on adenoma detection: a comparison study. *Am J Gastroenterol.* 2015;110:415–22.
8. Matsushita M, Hajiro K, Okazaki K, Takakuwa H, Tominaga M. Efficacy of total colonoscopy with a transparent cap in comparison with colonoscopy without the cap. *Endoscopy.* 1998;30:444–7.
9. Rex DK, Vemulapalli KC. Retroflexion in colonoscopy: why? Where? When? How? What value? *Gastroenterology.* 2013;144:882–3.
10. Lai EJ, Calderwood AH, Doros G, Fix OK, Jacobson BC. The Boston bowel preparation scale: a valid and reliable instrument for colonoscopy-oriented research. *Gastrointest Endosc.* 2009;69:620–5.
11. Singh H, Nugent Z, Demers AA, Kliewer EV, Mahmud SM, Bernstein CN. The reduction in colorectal cancer mortality after colonoscopy varies by site of the cancer. *Gastroenterology.* 2010;139:1128–37.
12. Harrison M, Singh N, Rex DK. Impact of proximal colon retroflexion on adenoma miss rates. *Am J Gastroenterol.* 2004;99:519–22.
13. Aadam AA, Saeian K, Massey BT. Proximal colon retroflexion with adult versus pediatric colonoscopes. *Gastrointest Endosc.* 2013;77:AB426–7.
14. Vargas AL, Albuquerque M, Figa M, González-Huix F. Ascending colon exploration by retroviewing: technical feasibility and diagnosis performance. *Gastrointest Endosc.* 2015;81:AB293.
15. Chandran S, Parker F, Vaughan R, Mitchell B, Fanning S, Brown G, et al. Right-sided adenoma detection with retroflexion versus forward-view colonoscopy. *Gastrointest Endosc.* 2015;81:608–13.
16. Rex DK. Colonoscopic withdrawal technique is associated with adenoma miss rates. *Gastrointest Endosc.* 2000;51:33–6.
17. Rex DK. Maximizing detection of adenomas and cancers during colonoscopy. *Am J Gastroenterol.* 2006;101:2866–77.
18. Simmons DT, Harewood GC, Baron TH, Petersen BT, Wang KK, Boyd-Enders F, et al. Impact of endoscopist withdrawal speed on polyp yield: implications for optimal colonoscopy withdrawal time. *Aliment Pharmacol Ther.* 2006;24:965–71.
19. Ishaq S, Siau K, Harrison E, Tontini GE, Hoffman A, Gross S, et al. Technological advances for improving adenoma detection rates: the changing face of colonoscopy. *Dig Liver Dis.* 2017;49:721–7.