



Review Article

Controversies in presacral tumors management



Nidal Issa^{a,*}, Yaniv Fenig^b, Nimrod Aviran^a, Muhammad Khatib^a, Mustafa Yassin^a

^a Rabin Medical Center, Petah-Tikva, and the Faculty of Medicine Tel Aviv University, Israel

^b Monmouth Medical Center, Long Branch, New Jersey, United States

ARTICLE INFO

Keywords:

Presacral tumor
Preoperative biopsy
Neoadjuvant therapy

ABSTRACT

Presacral tumors are rare lesions of the retrorectal space that can present diagnostic and therapeutic difficulty because of their anatomic location and the different tissue types and etiology. Although the diagnosis and management of these tumors has evolved in recent years, several points still to be addressed in order to improve perioperative diagnosis and treatment. In the upcoming we will try to highlight some controversial points; the pre-operative biopsies, neoadjuvant therapy, the necessity of surgery and the role of minimally invasive surgeries of presacral tumors.

© 2017 Sociedade Brasileira de Coloproctologia. Published by Elsevier Editora Ltda. This is an open access article under the CC BY-NC-ND license (<http://creativecommons.org/licenses/by-nc-nd/4.0/>).

Palavras-chave:

Tumor pré-sacral
Biópsia pré-operatória
Terapia neoadjuvante

Controvérsias no tratamento de tumores pré-sacrais

RESUMO

Tumores pré-sacrais são lesões raras do espaço retrorretal que podem trazer dificuldades diagnósticas e terapêuticas por causa de sua localização anatômica e também pelos diferentes tipos de tecidos e etiologia. Embora nos últimos anos o diagnóstico e tratamento desses tumores tenham evoluído, diversos pontos ainda devem ser estudados com vistas à melhora do diagnóstico e tratamento no perioperatório. Mais adiante, tentaremos esclarecer alguns pontos controversos; biópsias pré-operatórias, terapia neoadjuvante, a necessidade de cirurgia e o papel das cirurgias minimamente invasivas para os tumores pré-sacrais.

© 2017 Sociedade Brasileira de Coloproctologia. Publicado por Elsevier Editora Ltda. Este é um artigo Open Access sob uma licença CC BY-NC-ND (<http://creativecommons.org/licenses/by-nc-nd/4.0/>).

Introduction

Presacral tumors are heterogeneous and relatively rare. Given these characteristics, the clinical presentation, natural history and treatment of presacral tumors is not well understood.

The presacral space is bounded by the peritoneal reflection and the recto-sacral fascia. The embryologic development at this anatomical site is complex due to the presence of totipotential germ cells that differentiate into 3 germ cell layers. This in turn leads to the development of different types of tissues including connective tissue, nerves, fat, and blood vessels. The multitude of tissue types gives rise to numerous tumor pathologies. In addition, because the presacral space has diverse histopathological findings, physicians from

* Corresponding author.

E-mail: nidaldrissa@hotmail.com (N. Issa).

<http://dx.doi.org/10.1016/j.jcol.2017.06.006>

2237-9363/© 2017 Sociedade Brasileira de Coloproctologia. Published by Elsevier Editora Ltda. This is an open access article under the CC BY-NC-ND license (<http://creativecommons.org/licenses/by-nc-nd/4.0/>).

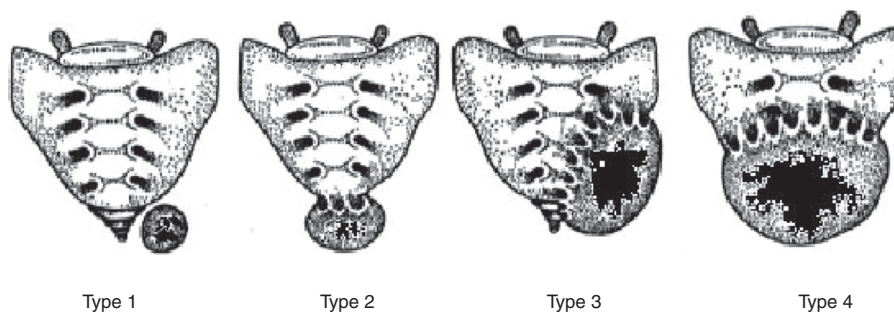


Fig. 1 – Classification based on tumor location.

diverse subspecialties including colorectal surgeons, obstetricians and gynecologists, urologists, neurosurgeons, and orthopedics are often involved in patient care.

Pre-sacral tumors were reported for the first time in the middle of the 19th century. Kiderlen et al. reported six cases in 1899 including a teratoma, which was the first reported case by Emmerich. The first pre-sacral tumor was resected by Dr. Middeldorpf, and this tumor was named after him for many years.¹

The true incidence of pre-sacral tumors in the general population is hard to assess because many reports come from tertiary centers and so do not represent the true incidence. The estimated incidence is about 1 case in every 40,000 hospital admissions. Most of the publications are individual case reports and small case series.²⁻⁴

As a result of the low incidence, there is no uniform classification system for these lesions. Four years ago, Uhlig and Johnson suggested a classification for these tumors according to its tissue of origin.² Physicians at Tel Aviv Medical Center proposed another classification system based on whether the lesion is congenital or acquired as well as whether it is benign or malignant.⁵

Yet another classification system is based on tumor location and its communication with the sacrum and/or coccyx (Fig. 1). Using tumor location as the basis for the classification facilitates the surgical approach.⁶ According to this classification type 1: the lesion is located at the coccyx level (below S3) and separated from the bony trunk of sacrococcyx, type 2 as type 1 but has connection with the coccyx sacrum. Type 3 the lesion involves the sacrum at or above the S3 nerve root unilaterally, and type 4 when large communication with the sacrum at or above S3 bilaterally.

Further, the above classification system reflects post-operative complications: resection of type 1 and 2 usually does not have neurological sequela and types 3 and 4 usually result in temporary or permanent incontinence.⁶

In recent years, the classification system proposed by Dozois and Jacofsky from the Mayo clinic is most commonly used. According to this classification (Table 1), tumors are divided into 5 categories which are further grouped into benign and malignant.⁷

About two thirds of all the pre-sacral tumors are congenital. Most of those are cystic and benign. 10% are of neurogenic in origin, 5-10% are of bone origin and about 15% are from other origins, including metastasis.⁸ In general, benign lesions are more common in females, while malignant tumors are

Table 1 – Classification of presacral retrorectal tumors.

Source of origin	Histopathology
<i>Congenital or developmental</i>	
Benign	Developmental cysts
	Dermoid cysts
	Epidermoid cysts
	Tail gut cysts
	Enteric (rectal) duplication
	Anterior sacral meningocele
	Teratoma
Malignant	Adrenal rest tumors
	Chordoma
	Teratocarcinoma
<i>Inflammatory</i>	Granulomas (foreign body)
	Perineal/pelviorectal abscess or fistula
<i>Neurogenic</i>	
Benign	Neurofibroma
	Neurolemmoma (schwannoma)
	Ganglioneuroma
Malignant	Ependymoma
	Ganglioneuroblastoma
	Neurofibrosarcoma
<i>Osseous</i>	
Benign	Osteoma Sacral bone cyst
	Osteoblastoma
	Osteogenic sarcoma
	Giant cell tumor
	Ewing's tumor
Malignant	Chondromyxosarcoma
	Osteogenic sarcoma
	Myeloma
<i>Miscellaneous</i>	
Benign	Lipoma
	Fibroma
	Leiomyoma
	Hemangioma
	Endothelioma
	Desmoid tumor
	Lymphangioma
	Ectopic kidney
	Fibrosarcoma
	Liposarcoma
	Leiomyosarcoma
	Metastatic disease
Malignant	

equal in both sexes. The most common lesions are cystic, benign, asymptomatic, and found incidentally. These lesions most often present with rectal fullness, painful defecation, or dysuria.³

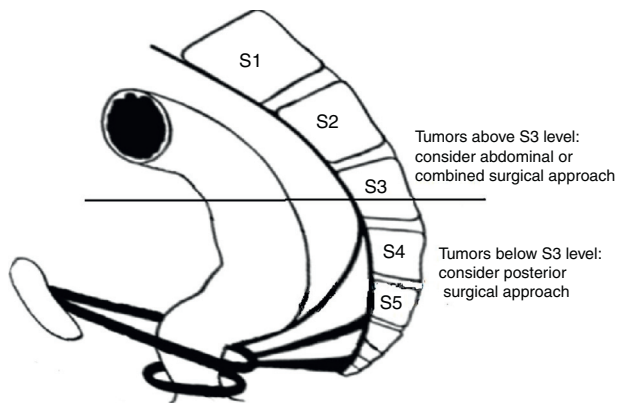


Fig. 2 – Anatomic delineation in respect to surgical approach.

Malignancy has been reported at a range of 9–45% of all pre-sacral tumors.⁹ The most common malignant pre-sacral tumors are Chondromas. They are slow growing cancers, usually asymptomatic, but symptoms may present later in the course with invasion into neurologic tissues. These tumors metastasize to bone, liver and lung in 20% of cases.⁸

Besides physical and rectal examinations, the standards methods of evaluation are CT scans and MRIs. A CT scan can determine whether the lesion is cystic or solid and whether there is any bone involvement. An MRI can provide more information regarding spinal involvement, but more importantly, it is able to give an estimation of the histology of the tumor. Transrectal ultrasound and angiography may also have a role in the workup.^{10,11}

The appropriate surgical approach for pre-sacral tumors is ascertained by pre-operative diagnosis and the demonstration of anatomic conditions such as location, size and involvement of adjacent structures.¹² The common surgical approaches include a) anterior trans-abdominal, b) posterior-perineal, and c) the combined approach. Small and low lying lesions below S3 can be removed via the posterior approach, either trans-sacral or para-sacral. Tumors above the level of S3 can be resected via the anterior trans-abdominal or the combined approach depending on the need for bone resection. Fig. 2 illustrates the anatomy associated with the various surgical approaches.

In general, benign lesions should be removed completely, usually with limited dissection. Malignant tumors require radical resection, sometimes with extensive excision of pelvic structures including the sacrum in order to achieve negative surgical margins. One of the most important prognostic factors are negative surgical margins. If wide margins are not achieved, one can expect high recurrence rates and poorer survival. A study from Tel Aviv Medical Center showed that after resection of malignant pre-sacral tumors, most of the recurrent tumors were incompletely resected and 50% of these patients died of their disease.⁶

The overall survival for benign pre-sacral lesions is nearly 100%, with a lower recurrence rate. For malignant lesions, the overall survival is 74% and the 10-year survival rate is about 32%. The rate of recurrence in such cases is high, reaching as high as 75% in some reports.^{10,13}

Discussion

Many controversies exist in the literature concerning pre-operative biopsies, neoadjuvant therapy, the necessity of surgery and the role of minimally invasive surgeries with regard to the diagnosis and treatment of presacral tumors.

Pre-operative biopsy

The existing paradigm regarding pre-operative biopsy is that it is not recommended because of the risk of septic complications and tumor seeding. Data from the Mayo clinic, the largest reported series of all tumors between 1960 and 1979, supports this recommendation.⁵ The authors of this series reported higher recurrence rates in patients that had pre-operative biopsy as opposed to those who did not. On the other hand, in a case series from Memorial Sloan Kettering Cancer Center (MSKCC) of 27 patients who had a pre-operative biopsy, 12 via the open approach and 15 via needle biopsy, none of the patients experienced complications and the pathology results were highly accurate in detecting malignancy.¹⁴ A retrospective analysis conducted by the Mayo clinic using all their cases in the last 20 years provides further evidence of the relative safety of performing a pre-operative biopsy. In this series, they only had 2 hematomas out of 76 biopsies. They also showed that pre-operative biopsy can guide the surgical approach and avoid extensive resections in patients with a benign pathology. They showed that the pre-operative biopsy was in concordance with the final pathologies at a higher rate than those resulting from the various imaging techniques.¹⁵

In cases where a tumor is resectable, it may seem like a pre-operative biopsy is not required. But, in the case of a similar lesion like neuro-fibroma and neuro-fibro-sarcoma, a pre-operative biopsy is needed to distinguish between them. So this leads to the question: Should we biopsy all tumors? All solid tumors?

Merchea et al. from the Mayo clinic provides an answer. They suggest that a pre-operative biopsy in non-cystic lesions should be considered, if there is any doubt regarding the precise diagnosis and if the biopsy can change the surgery or guide the management.²⁹ It seems that many tumors meet at least one of these criteria. Given this recommendation, we see an increasing tendency in performing pre-operative biopsies in pre-sacral lesions.

Neoadjuvant therapy

Neoadjuvant therapy has many known benefits including treating micro-metastasis as well as down-sizing and down-staging the tumor. Some pre-sacral tumors, like osteogenic sarcoma and neurofibrosarcoma, are sensitive to chemotherapy.¹⁶ Some tumors can even reach complete response. But unfortunately, chordomas repond poorly to chemotherapy. However, photon radiation therapy and carbon-ion radiation therapy has led to some positive results for the treatment of pre-sacral chordomas, but these therapies are very uncommon and may not be available everywhere.^{17,18}

The necessity of surgery

If you have a small cyst that is benign and asymptomatic and is located behind the rectum, is it definitely indicated to resect it? There are no reports analyzing conservative management of pre-sacral benign cystic lesions, perhaps because of its rarity. Paradoxically, the only report of a conservative approach was more than 50 years ago from the Mayo Clinic and it was the result of a poor surgical outcome and not because of the benign nature of the lesion.^{19,20} Many feel that all presacral lesions, even small benign cysts, should be removed for several reasons: cysts can become infected, have a malignant transformation, or they can enlarge and make the surgery more complicated.

The role of minimally invasive surgical approaches

In addition to the advantages of laparoscopy in general, the literature reports several specific advantages of minimally invasive surgery (MIS) in pre-sacral tumors in terms of safety, visualization of the pre-sacral space and completeness of the resection.^{21,22} Laparoscopy may be an alternative to the anterior abdominal approach and in some cases it can replace the combined approach.^{23,24} However, most presacral tumors are small lesions and are both cystic and benign. Therefore, there is not sufficient evidence to support laparoscopic resection of malignant pre-sacral lesions.

There are several reports on the use of robotic techniques for pre-sacral tumors.²⁵ This can sometimes replace the posterior approach, such as the Transanal Endoscopic Microsurgery (TEM), by entering the pre-sacral space through the posterior wall of the rectum. TEM has many advantages that can facilitate the excision of the lesion in almost any place retro-rectally. There are several series of TEM excision of retro-rectal pre-sacral cysts with excellent outcomes and complete excision of the lesions.^{26,27} A recent report from Rambam Medical Center in Israel reported the successful and non-complicated resection of four pre-sacral tumors using TEM.²⁸

There are also disadvantages to using TEM for the resection of pre-sacral tumors. First, infections may be introduced when entering the pre-sacral space through the rectum. Second, and more importantly, the use of TEM for the resection of presacral tumors comes with a risk of sacral bleeding.

Conclusion

In conclusion, pre-sacral tumors are quite rare. It seems that there is an indication for a pre-operative biopsy whenever it can influence the management. Minimally invasive surgery gains more acceptances recently for resection of benign pre-sacral lesions. Though for malignant lesions, neoadjuvant therapy should be considered, so negative margins can be assured. This can be achieved by an experienced team at a referral center that has sufficient numbers of patients with presacral tumors to gain the experience required to safely treat these patients.

Conflicts of interest

The authors declare no conflicts of interest.

REFERENCES

1. Wittaker LD, Pemberton JD. Tumors ventral to the sacrum. *Ann Surg*. 1938;1:96–106.
2. Uhlig BE, Roderick LJ. Presacral tumors and cysts in adults. *Dis Colon Rectum*. 1975;18:581–96.
3. Spencer RJ, Jackman RJ. Surgical management of precoccygeal cysts. *Surg Gynecol Obstet*. 1962;115:449–52.
4. Jao SW, Beart RW Jr, Spencer RJ, Reiman HM, Ilstrup DM. Retrorectal tumors. Mayo Clinic experience, 1960–1979. *Dis Colon Rectum*. 1985;28:644–52.
5. Lev-Chelouche D, Gutman M, Goldman G, Even-Sapir E, Miller I, Issakov J, et al. Presacra tumors: a practical classification and treatment of a unique and heterogeneous group of diseases. *Surgery*. 2003;133:473–8.
6. Losanoff JE, Sauter ER. Retrorectal cysts. *J Am Coll Surg*. 2003;197:879–80.
7. Dozise EJ, Jacofsky DJ, Dozois RR. Presacral tumors. *The ASCRS textbook of colon and rectal surgery*. New York: Springer; 2007. p. 501–14.
8. Woodfield JC, Chalmers AG, Phillips N, Sagar PM. Algorithms for the surgical management of retrorectal tumours. *Br J Surg*. 2008;95:214–21.
9. Hobson KG, Ghaemmaghami V, Roe JP, Goodnight JE, Khatri VP. Tumors of the retrorectal space. *Dis Colon Rectum*. 2005;48:1964–74.
10. Pappardo G, Frattaroli FM, Casciani E, Moles N, Mascagni D, Spoletini D, et al. Retrorectal tumors: the choice of surgical approach based on a new classification. *Am Surg*. 2009;75:240–8.
11. Coco C, Manno A, Mattana C, Verbo A, Sermoneta D, Franceschini G, et al. Congenital tumors of the retrorectal space in the adult: report of two cases and review of the literature. *Tumori*. 2008;94:602–7.
12. Szylo K, Lesnik. Sacrococcygeal teratoma — case report and review of the literature. *Am J Case Rep*. 2013;14:1–5.
13. McMaster ML, Goldstein AM, Bromley CM, Ishibe N, Parry DM. Chordoma: incidence and survival patterns in the United States, 1973–1995. *Cancer Causes Control*. 2001;12:1–11.
14. Cody HS, Marcove RC, Quan SH. Malignant retrorectal tumors: 28 years' experience at Memorial Sloan-Kettering Cancer Center. *Dis Colon Rectum*. 1981;24:501–6.
15. Yarram SG, Nghiem HV, Higgins E, Fox G, Nan B, Francis IR. Evaluation of imaging-guided core biopsy of pelvic masses. *Am J Roentgenol*. 2007;188:1208–11.
16. Stewart RJ, Humphreys WG, Parks TG. The presentation and management of presacral tumours. *Br J Surg*. 1986;73:153–5.
17. Catton C, O'Sullivan B, Bell R, Laperriere N, Cummings B, Fornasier V, et al. Chordoma: long-term follow-up after radical photon irradiation. *Radiother Oncol*. 1996;41:67–72.
18. Zhang H, Yoshikawa K, Tamura K, Sagou K, Tian M, Suhara T, et al. Carbon-11-methionine positron emission tomography imaging of chordoma. *Skeletal Radiol*. 2004;33:524–30.
19. MacCarty CS, Waugh JM, Coventry MB, Cope WF Jr. Surgical treatment of sacral and presacral tumors other than sacrococcygeal chordoma. *J Neurosurg*. 1965;22:458–64.
20. Waldhausen JA, Kolman JW, Vellios F, Battersby JS. Sacrococcygeal teratoma. *Surgery*. 1963;54:933–49.
21. Bax NM, van der Zee DC. The laparoscopic approach to sacrococcygeal teratomas. *Surg Endosc*. 2004;18:128–30.

22. Konstantinidis K, Theodoropoulos GE, Sambalis G, Georgiou M, Vorias M, Anastassakou K, et al. Laparoscopic resection of presacral schwannomas. *Surg Laparosc Endosc Percutan Techn.* 2005;15:302–4.
23. Paul PG, Pravinkumar T, Sheetal B. Sacrococcygeal neurofibroma: rare cause for chronic pelvic pain. *J Minim Invas Gynecol.* 2012;19:517–20.
24. Nedelcu M, Andreica A, Skalli M, Pirlett I, Françoise G, Nocca D, et al. Laparoscopic approach for retrorectal tumors. *Surg Endosc.* 2013;27:4177–83.
25. Agorastos S, Alex A, Feldman J, Kuncewitch M, Deutsch G, Siskind E, et al. Robotic resection of retro-rectal tumor: an alternative to the Kraske procedure. *J Solid Tumors.* 2013;3:13–6.
26. Zoller S, Joos A, Dinter D, Back W, Horisberger K, Post S, et al. Retrorectal tumors: excision by transanal endoscopic microsurgery. *Rev Espanola Enfermedades Digest.* 2007;9:547–50.
27. Serra Aracil X, Gomez Diaz C, Bombardo J, Mora Lopez L, Alcantara Moral M, Ayguavives I, et al. Surgical excision of retrorectal tumour using transanal endoscopic microsurgery colorectal disease. 2010;6:594–5.
28. Duek SD, Kluger Y, Grunner S, Weinbroum AA, Khoury W. Transanal endoscopic microsurgery for the resection of submucosal and retrorectal tumors. *surgical laparoscopy. Endosc Percutan Techn.* 2013;1:66–8.
29. Merchea A, Larson DW, Hubner M, Wenger DE, Rose PS, Dozois EJ. The value of preoperative biopsy in the management of solid presacral tumors. *Dis Colon Rectum.* 2013;56: 756–60.