



Journal of Coloproctology

www.jcol.org.br



Case report

Preoperative embolization of a cavernous hemangioma of the rectum

Raphael Gurgel de Carvalho^a, Marley Ribeiro Feitosa^{a,*}, Gustavo Urbano^a,
Vivian Regina Guzela^a, Edwaldo Edner Joviliano^b, Omar Féres^a,
Jose Joaquim Ribeiro da Rocha^{a,☆}

^aDivision of Coloproctology, Department of Surgery and Anatomy, Faculdade de Medicina de Ribeirão Preto, Universidade de São Paulo, Ribeirão Preto, SP, Brazil

^bDivision of Vascular and Endovascular Surgery, Department of Surgery and Anatomy, Faculdade de Medicina de Ribeirão Preto, Universidade de São Paulo, Ribeirão Preto, SP, Brazil

ARTICLE INFO

Article history:

Received 11 December 2013

Accepted 13 December 2013

Keywords:

Cavernous hemangioma
Gastrointestinal hemorrhage
Therapeutic embolization

Palavras-chave:

Hemangioma cavernoso
Hemorragia gastrointestinal
Embolização terapêutica

ABSTRACT

Colorectal cavernous hemangioma is a rare benign vascular neoplasia that may be found in any segment of the colon and cause recurrent and painless rectal bleeding. Standard treatment of rectal hemangioma consists of resection of the affected segment followed by coloanal anastomosis. Massive bleeding during the operation is the most feared complication, especially during extensive resection or reoperation. The authors describe a preoperative embolization of a rectal hemangioma with Onyx-18[®] and microspheres, in a 49-year-old patient with successful prevention of uncontrolled hemorrhage during surgery.

© 2014 Sociedade Brasileira de Coloproctologia. Published by Elsevier Editora Ltda.

Este é um artigo Open Access sob a licença de [CC BY-NC-ND](https://creativecommons.org/licenses/by-nc-nd/4.0/)

Embolização pré-operatória do hemangioma cavernoso do reto

RESUMO

O hemangioma colorretal cavernoso é uma neoplasia vascular benigna rara, que pode comprometer qualquer segmento do cólon e causar sangramento retal indolor recorrente. O tratamento habitual da doença retal inclui ressecção do segmento afetado seguido de anastomose coloanal. Sangramento retal no intra-operatório é uma complicação temível especialmente durante ressecções extensas ou reoperações. Os autores descrevem a embolização pré-operatória com microesferas e Onyx-18[®] de um hemangioma retal em um paciente de 49 anos, com controle satisfatório de hemorragia maciça durante o ato cirúrgico.

© 2014 Sociedade Brasileira de Coloproctologia. Publicado por Elsevier Editora Ltda.

Este é um artigo Open Access sob a licença de [CC BY-NC-ND](https://creativecommons.org/licenses/by-nc-nd/4.0/)

* Surgery performed at the Department of Surgery and Anatomy, of Ribeirão Preto Medical School, University of São Paulo (USP).

☆ Corresponding author.

E-mail: marleyfeitosa@yahoo.com.br (M. R. Feitosa).

2237-9363 © 2014 Sociedade Brasileira de Coloproctologia. Published by Elsevier Editora Ltda.

Este é um artigo Open Access sob a licença de [CC BY-NC-ND](https://creativecommons.org/licenses/by-nc-nd/4.0/) <http://dx.doi.org/10.1016/j.jcol.2013.12.008>

Introduction

Colorectal cavernous hemangioma is a rare congenital benign neoplasia first described in 1839 by Phillips.¹ One of the largest report of cases was published in 2010 and included 17 patients.² This vascular condition can compromise all segments of the colon, jejunum and ileum. The rectum and sigmoid colon are the most common affected sites (50%).^{3,4} The most common symptom is episodic and painless rectal bleeding. It may appear early in life and lead to anemia. The symptoms are frequently ignored or misdiagnosed as hemorrhoids, and treated as such.^{2,5,6} Our objective is to report a case of a diffuse cavernous hemangioma of the rectosigmoid and to describe a novel approach consisting of preoperative use of arterial embolization of nurturing vessels, in order to prevent complications as massive hemorrhages and multiple blood transfusions.

Case report

A 49-year-old male patient arrived to the emergency department with asthenia, significant rectal bleeding, palpitations and effort dyspnea. Physical examination revealed a pale skin and no signs of hemodynamic instability were noted. His abdomen was normal and rectal examination evidenced a spongy rectal mucosa, with a nodule-like sensation. Initial hemoglobin was 4.9 mg/dl. The patient's medical history included numerous bleeding episodes for 40 years but no medical care was sought.

After a blood transfusion, the patient was submitted to a colonoscopy, which revealed diffuse, elevated, red-wine nodules, extending from the sigmoid colon (20 cm from the anal verge) to the lower rectum (Fig. 1). An angiotomography evidenced a diffuse vascular formation affecting the rectosigmoid and perirectal fat (Fig. 2).

The patient was submitted to a selective embolization of the distal branches of the hipogastric vessels. The proce-

dure failed in controlling the bleeding episodes and a rector-sigmoidectomy was indicated.

Endovascular embolization of arterial vessels of the hemangioma with Onyx-18[®] and microspheres was performed before the surgery (Fig. 3). The patient was submitted to an open anterior rector-sigmoidectomy with col-anal anastomosis and protective colostomy. No significant bleeding and no episodes of hemodynamic instability were noted during the operation. The patient left the operating room with hemoglobin levels of 10.9 mg/dl.

Recovery was successful and the patient left the hospital after seven days. There was no recurrence of rectal bleeding. Post-operative colonoscopy evidenced a normal colon. Colostomy closure was carried out two months after the surgery. Fecal incontinence was not noted.

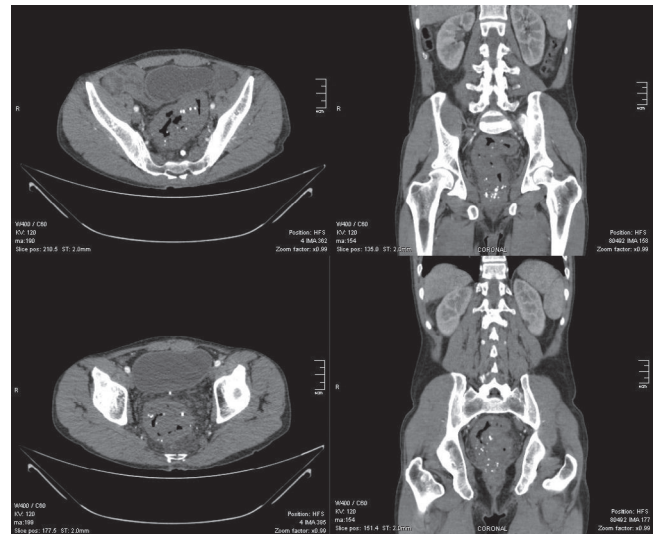


Fig 2 – Angiotomography evidencing rectosigmoid and perirectal fat thickening with multiple areas of calcification.

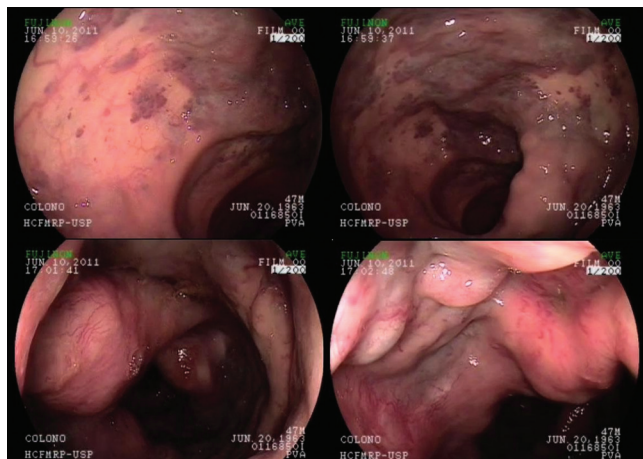


Fig. 1 – Colonoscopy evidencing elevated red-wine nodules extending from the sigmoid colon to the lower rectum. Notice the coexistence of normal and affected areas.

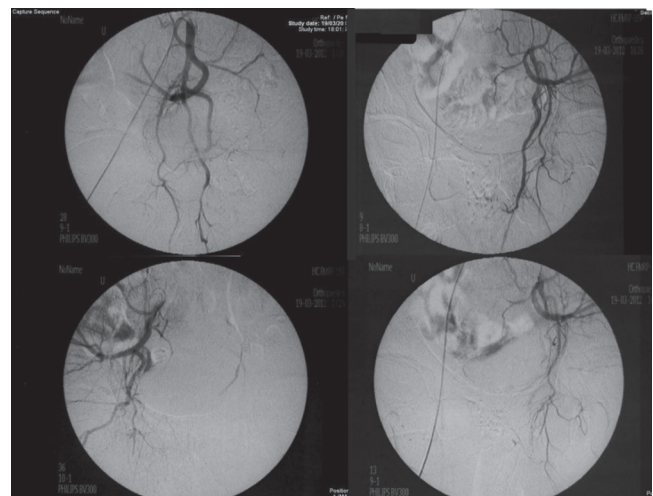


Fig 3 – Embolization of left and right hipogastric vessels prior to surgery.

Discussion

The cavernous hemangioma of the rectum is a very uncommon cause of intestinal bleeding with sparse data on literature. The disease is a vascular malformation histologically characterized by dilated and tortuous blood vessels, with thin walls and scarce stromal tissue, which can affect all layers of the intestinal tract including perirectal fat and adjacent organs.^{2,6}

Due to its uncommonness many patients are misdiagnosed with other colorectal diseases such as hemorrhoids, inflammatory bowel disease and malignant neoplasia. This lack of awareness of the clinical features of the condition may lead to late diagnosis and delay of proper treatment.^{2,5,6} A recent report found a mean delay time of 17 years between initial symptoms and final diagnosis.²

Prompt diagnosis of rectal hemangioma is very important because of its tendency to cause massive rectal hemorrhage. Classical findings include painless rectal bleeding beginning early in childhood associated to anemia. Other sites may be affected such as skin, mouth, tongue and lips. Rectal examination may reveal elevated nodules with spongy mucosa. Hard small nodules may correspond to calcification of intravascular thrombi. Colonoscopy plays an important role in evaluating the extension of the disease and helps surgery planning.

Typical endoscopic findings include tortuous dilated red-vein blood vessels, with poorly defined margins and variable extension. Healthy mucosa can be seen in between affected areas. Submucosal nodules may be misdiagnosed as polyps. Thrombosis may lead to ulceration mimicking an ulcerative colitis. The biopsy of lesions increases the risk of important bleeding and should be avoided. Angiotomography and angioresonance are useful to evaluate extracolonic extension of the disease including liver and spleen. A plain radiography may reveal sites of calcification in the pelvis. Routine arteriography is not advised because it's an invasive procedure and provides little data.

Standard treatment includes removal of the affected segment. Alternatives such as radioablation therapy, sclerosis, embolization and even surgical ligation of the inferior mesenteric artery offer poor results with high recurrence rates.^{2,5-7} A rectosigmoidectomy was originally performed through abdominoperineal amputation of the rectum and part of the sigmoid. Nowadays it is performed by open or laparoscopic anterior rectosigmoidectomy, followed by coloanal anastomosis with better results.²⁻⁸ Massive bleeding during the operation is the most feared complication especially if there is a pelvic extension of the disease, or during extensive resection and reoperation. A recent review from a Chinese group reported losses up to 2000ml of blood during surgery with transfusion needs up to 3000ml.²

Preoperative embolization has already been described for other surgeries⁹⁻¹¹ but this is the first report in a rectal heman-

gioma. Embolization was conducted one day prior to surgery using Onyx-18[®] and microspheres, targeting hipogastric and superior rectal arteries. The main goal of the procedure was to reduce the blood flow to the rectosigmoid and perirectal fat tissue in order to avoid intraoperative bleeding.

Conclusion

Further investigation is necessary concerning the use of this auxiliary therapy before becoming a routine. Nevertheless the authors consider the procedure an important tool to reduce intraoperative bleeding, especially in those cases of extensive lesions.

Conflicts of interest

The authors declare no conflicts of interest.

REFERENCES

1. Phillips B. Surgical cases. *London Med Gaz.* 1839; 23:514-517.
2. Wang HT, Gao XH, Fu CG, Wang L, Meng RG, Liu LJ. Diagnosis and Treatment of Diffuse Cavernous Hemangioma of the Rectum: Report of 17 Cases. *World J Surg* (2010) 34:2477-2486.
3. Condon RE, Loyd RD. Haemangioma of the colon. *Am J Surg* 1968; 115:720-3
4. Allred HW, Spencer RJ. Haemangioma of the colon, rectum and anus. *Mayo Clin Proc* 1974; 49:739-41.
5. Amarapurkar D, Jadliwala M, Punamiya S, Jhaver P, Chitale A, Amarapurkar A. Cavernous Hemangiomas of the Rectum: Report of Three Cases. *Am J Gastroenterol*, 1998 Aug; 93(8): 1357-9.
6. Coy CSR, Machado MM, Góes JRN, Fagundes JJ, Júnior PT, Ayrizono ML, et al. Hemangioma Cavernoso Difuso Retal - Relato De Caso. *Rev Bras Cir*, 1995; 15(4): 187-189.
7. Corbally MT, McMullin JP. Diffuse Cavernous Hemangioma of the Rectosigmoid and Low Anterior Resection Using the Autostapler. *J Pediatr Surg.* 1988 Nov; 23(11): 1032-3.
8. Leal RF, Ayrizono MLS, Silva PVVT, Oliveira PSP, Fagundes JJ, Coy CSR. Laparoscopic-assisted bowel resection with construction of a colonic reservoir for cavernous hemangioma of the rectum: report of two cases. *Tech Coloproctol* (2011) 15:205-20.
9. Wu Z, Zhou J, Pankaj P, Peng B. Comparative treatment and literature review for laparoscopic splenectomy alone versus preoperative splenic artery embolization splenectomy. *Surg Endosc.* 2012 May 12.
10. Power AH, Bower TC, Kasperbauer J, Link MJ, Oderich G, Cloft H, et al. Impact of preoperative embolization on outcomes of carotid body tumor resections. *J Vasc Surg.* 2012 Jun 23.
11. Kayan M, Cetin M, Aktaş AR, Yılmaz O, Ceylan E, Eroğlu HE. Preoperative arterial embolization of symptomatic giant hemangioma of the liver. *Prague Med Rep.* 2012;113(2):166-71.