



# Journal of Coloproctology

www.jcol.org.br



## Technical Note

# Human fibrinogen and thrombin patch for extraluminal protection of intestinal anastomosis

Paulo Gustavo Kotze<sup>a,\*</sup>, Ivan Folchini de Barcelos<sup>a</sup>, Renato Vismara Ropelato<sup>a</sup>,  
Claudio Saddy Rodrigues Coy<sup>b</sup>

<sup>a</sup>Colorectal Surgery Unit, Cajuru University Hospital, Catholic University of Paraná, Curitiba, PR, Brazil

<sup>b</sup>Colorectal Surgery Unit, Campinas State University (UNICAMP), Campinas, SP, Brazil

### ARTICLE INFO

#### Article history:

Received 15 July 2013

Accepted 2 August 2013

#### Keywords:

Anastomosis, surgical

Colorectal surgery

Dehiscence, surgical wound

### ABSTRACT

In spite of recent advances regarding equipment and surgical techniques in colorectal surgery, rates of anastomotic dehiscence (AD) have remained stable throughout the years. The development of products to protect anastomosis aiming the reduction of AD rates has shown to be promising. Human fibrinogen and thrombin patch (HFTP - Tachosil®) have been used in experimental studies in animals and small case series in humans, with promising results. In this study, the authors describe the technique of HFTP use in details, aiming the protection of colorectal anastomosis, and retrospectively demonstrate the preliminary results in a pilot case series. HFTP was used in 4 patients submitted to conventional surgery. The procedures performed were: left colon resection, segmental colectomy (both for colorectal cancer), enteral anastomosis for fistula closure and right ileocelectomy. Anastomotic healing and absence of complications were observed in 3 patients, and the patient submitted to right ileocelectomy developed AD and died after reoperation. The use of HFTP is safe and can be indicated in selected cases. However, AD can occur even after the use of this strategy. Randomized controlled trials with larger samples of patients are needed in order to properly define the real benefits of this strategy in dehiscence prevention

© 2013 Elsevier Editora Ltda. Este é um artigo Open Access sob a licença de [CC BY-NC-ND](#)

## Membrana de fibrinogênio e trombina humanos para proteção extraluminal de anastomoses intestinais

### RESUMO

Apesar dos avanços em equipamentos e técnica cirúrgica na cirurgia colorretal, os índices de deiscência de anastomose (DA) tem permanecido estáveis nos últimos anos. O desenvolvimento de produtos que visam proteção das anastomoses para redução das taxas de DA tem se mostrado promissor. A membrana de fibrinogênio e trombina humanos (MFTH) vem sendo utilizada em estudos experimentais e em pequenas séries de casos em humanos, com resultados promissores. Neste artigo os autores detalham a descrição técnica da utilização da MFTH na proteção de anastomoses colorretais, e demonstram os resultados preliminares em uma série de casos inicial, de forma retrospectiva. A MFTH foi utilizada

#### Palavras-chave:

Anastomose cirúrgica

Cirurgia colorretal

Deiscência da ferida operatória

\* Corresponding author.

E-mail: [pgkotze@hotmail.com](mailto:pgkotze@hotmail.com) (P.G. Kotze)

2237-9363 © 2013 Elsevier Editora Ltda. Este é um artigo Open Access sob a licença de [CC BY-NC-ND](#)

<http://dx.doi.org/10.1016/j.jcol.2013.08.004>

em 4 pacientes para proteção das anastomoses, todos operados por via de acesso convencional. Os procedimentos realizados foram: retossigmoidectomia abdominal, colectomia segmentar, enteroanastomose para fechamento de fístula enteral e ileocolectomia direita. Observou-se cicatrização das anastomoses em 3 casos, e DA com necessidade de reoperação e óbito no paciente submetido a ileocolectomia direita. A utilização da MFTH para proteção de anastomoses colorretais é segura, e pode ser utilizada em casos selecionados. DA pode ocorrer mesmo com a utilização da membrana. Aguarda-se estudos randomizados e controlados com maior amostragem de pacientes para se avaliar o real papel dessa estratégia na prevenção da deiscência.

© 2013 Elsevier Editora Ltda. Este é um artigo Open Access sob a licença de [CC BY-NC-ND](#)

## Introduction

Although in recent years surgeons have enjoyed greater success in performing intestinal anastomosis when compared to centuries ago, the results have never been perfect.<sup>1</sup> Anastomotic dehiscence (AD) is the most feared complication in intestinal surgical procedures and can cause serious consequences to patients, from reoperations to need for stoma creation, pelvic sepsis and deaths from various causes.<sup>2</sup>

In colorectal operations, depending on the location of the anastomosis, the incidence of dehiscence may vary from 1 to 24%.<sup>2</sup> When symptomatic, they are associated with mortality in 6 to 22% of cases.<sup>3</sup>

The integrity of the anastomosis results from a complex interaction between the surgeon, the patient and the underlying disease.<sup>1</sup> Although the accurate prediction of risk is impossible, certain factors related to the patient, such as age, male gender, smoking, hypoalbuminemia, corticosteroid use, ASA (American Society of Anesthesiology) statuses III and IV are related to AD. Elements related to the surgical procedure itself (tension at the anastomosis site, blood supply, prolonged surgery) and the intestinal condition (inflammatory disease, distal neoplasia, metastases, peritonitis) also play a key role for successful healing of anastomoses.<sup>1,4,5</sup>

Stapled anastomoses have gained more room in the last 30 years, with the introduction of new disposable staplers. Even with good acceptance in the current scenario, recent studies have failed to demonstrate the superiority of this technique when compared with hand-sewn anastomosis in colorectal surgeries.<sup>6-9</sup> Although some studies have reported a higher rate of stenosis,<sup>7</sup> low anastomoses performed by stapling seem to technically facilitate the procedure and reduce surgical time, especially in patients with a narrow pelvis. The decision regarding the technique should be based on the surgeon's expertise, clinical circumstances and the availability of staplers.<sup>7</sup>

Several materials have been proposed to obtain internal or external anastomosis reinforcement, aiming to reduce the risk of dehiscence and/or minimize its consequences. Intraluminal sealants,<sup>5,10</sup> biodegradable material compounds with barrier function, aim to prevent the contact of the fecal contents with the anastomosis, thereby avoiding the extravasation of fecal matter in the case of AD.<sup>5,11</sup> A prospective, multicenter, randomized controlled trial is in progress to evaluate the effectiveness of this device.<sup>11</sup>

Extraluminal sealants function as an external coating of the anastomosis and have been proposed aiming to fill the gaps between the staples/stitches, reduce bleeding and the rate of AD (extravasation).<sup>10</sup> This method can be particularly valuable for anastomosis of high risk, as in the case of some degree of AD, the defect would be sealed by the coated material, thereby preventing the clinical outcome.<sup>12</sup> Included in this group are multiple devices, such as fibrin glue, expandable polytetrafluoroethylene (ePTFE), oxidized regenerated cellulose (Curacel®), platelet-rich plasma, the omentum, hyaluronic acid/carboxymethyl cellulose and collagen matrix-bound coagulation factors, also called human fibrinogen and thrombin patch (HFTP - TachoSil®).<sup>10</sup>

Most studies performed with these materials are experimental models in animals and have not shown convincing results.<sup>12,13</sup> Evidence of efficacy and safety through prospective, controlled and randomized trials are scarce.<sup>10,12,13</sup> Fibrin sealants are the most often studied of these materials, showing positive results in humans, although without statistical significance.<sup>14</sup>

The HFTP (TachoSil®) is an equine collagen sponge coated with human thrombin and fibrinogen, primarily developed for secondary hemostasis. Thrombin converts fibrinogen into fibrin, thereby creating a fibrin clot. This clot maintains the collagen sponge firmly adhered to the tissue, which provides an extra layer of sealing.<sup>12</sup> Its usefulness, efficacy and safety have been demonstrated in some studies, for different types of procedures, from liver and heart surgery and transplants to abdominal and urological procedures.<sup>15</sup>

When used to protect high-risk intestinal anastomoses, it seems to have a beneficial effect in the prevention of AD, although most of these results were obtained from experimental studies.<sup>16,17</sup>

Clinical data on the use of HFTP - Tachosil® in these anastomoses is limited. In one of the few studies carried out in humans, De Stefano *et al.*,<sup>18</sup> in a nonrandomized trial, described the use of this device in 24 patients undergoing conventional colorectal operations. The use of the product was considered effective as a sealant of anastomoses in these patients, assessed by the shorter hospital stay compared to the control group (7.2 × 9.3 days).

In spite of advances in surgical technology and all anastomosis creation and protection mechanisms, the occurrence of AD after procedures in the colon and especially the rectum<sup>9</sup> continues to show unacceptably high frequencies.<sup>2</sup> For this reason, it is necessary to develop new tech-

niques, products and studies that demonstrate the real benefit of the available devices, as the currently endorsed mechanisms have not been able to reduce this important complication.

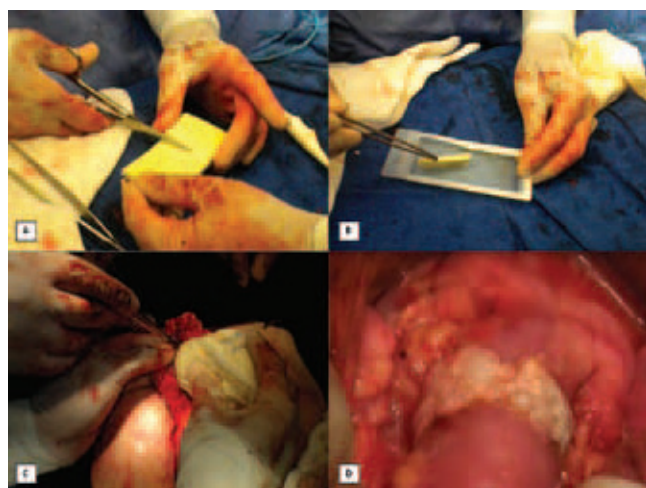
The aim of this article was to describe in details the technique of HFTP - TachoSil® use as an extraluminal protective device in intestinal anastomoses, showing preliminary results in four patients submitted to surgical procedures, with varying diagnoses and clinical conditions.

## Technical description

To use HFTP as an extraluminal protection device in intestinal anastomoses, the surgical steps to perform the latter should occur without any changes in the usual technical standards in their respective topographies. The anastomoses can be performed manually or mechanically, according to the surgeon's experience and preference and the local conditions of the segments to be anastomosed. This protection strategy can be used in both anastomoses performed through conventional or laparoscopic surgery.

Thereafter, the device is removed from its sterile packaging and sectioned into pieces of determined sizes according to the type of anastomosis to be protected (Fig. 1A). The original size of the product is 9.5 × 4.8 cm, with a rectangular aspect. The active surface of the product, which triggers the coagulation that results in the sealing of the anastomotic site, has a yellowish color due to its riboflavin coverage used only as a marker.

On the back table, the membrane fragments are washed in a container with approximately 20 mL of isotonic saline solution at 0.9% for several seconds (Fig. 1B). From this point on, with the active yellowish surface in contact with the anastomosed segment, the membrane segments are adapted around



**Fig. 1 – Technical description of HFTP use for intestinal anastomosis protection. A, The membrane is cut at varying sizes to better fit the anastomotic site. B, Exposure to isotonic saline solution to trigger the membrane's clotting properties. C, Compression with dressing protected by surgical glove for 3-5 minutes. D, Final appearance of the anastomosis protected by the membrane.**

the anastomosis and gently compressed with gauze wrapped in a surgical glove for 3-5 minutes (Fig. 1C). There can be overlapping of the product segments without any detrimental effects. After this time, the soft compression is removed and a firm clot adhered to the applied segment can be observed, and then the anastomosis surrounded by the product is reviewed. One should emphasize the need for coverage of about 1 to 2 cm on each side of the anastomosis for proper adhesion of the membrane to the intestine and sealing of the sutured segment (Fig. 1D).

All types of anastomoses of the small and large intestine (entero-enteric, entero-colic, colo-colic, ileo-rectal and colorectal) can be protected with HFTP.

## Preliminary results

According to the previously described technical principles, four patients that underwent intestinal anastomoses were submitted to the use of HFTP for extraluminal reinforcement and comprised the preliminary sample of this technical description study. Two female patients were operated for colorectal neoplasms (left colon) and underwent conventional colectomy. One male patient was operated for an anastomotic fistula secondary to right ileocelectomy due to previous complicated appendectomy, being submitted to a new ileocolic resection, also conventionally. Finally, a female patient with enteral fistula and previous peritoneostomy underwent enteroanastomosis for fistula closure. The details of each patient are given in Table 1 and in Figs. 2, 3 and 4.

As it can be observed, two patients underwent hand-sewn anastomosis and two were submitted to stapled anastomoses. Patient 1 underwent high colorectal stapled anastomosis at the level of the sacral promontory and HFTP was applied after the use of the stapler, without removing the latter. This technical detail allows better fitting when applying the device. The stapler was removed only after the complete adhesion of the membrane. Patient 2 underwent a colo-colic end-to-end hand-sewn anastomosis, and the membrane was applied without difficulty (Fig. 2). Patient 3 underwent an entero-enteral anastomosis in an area of enteral fistula secondary to previous complex abdominal surgery. After primary suture with 3.0 polypropylene yarn, HFTP was applied with a closed bandage over the fistula (Fig. 3). These first 3 patients recovered uneventfully postoperatively without any general complications or complications at the anastomotic site.

Patient 4 received the HFTP after an ileo-transverse anastomosis performed by the side-to-side technique with a 100-mm linear stapler. Although the technical conditions of the anastomosis were the best possible (Fig. 4), the patient developed AD and abdominal abscess, underwent reoperation with externalization of the two anastomotic mouths on the right flank (Mikulicz stoma) and died due to acute bacterial endocarditis and heart failure.

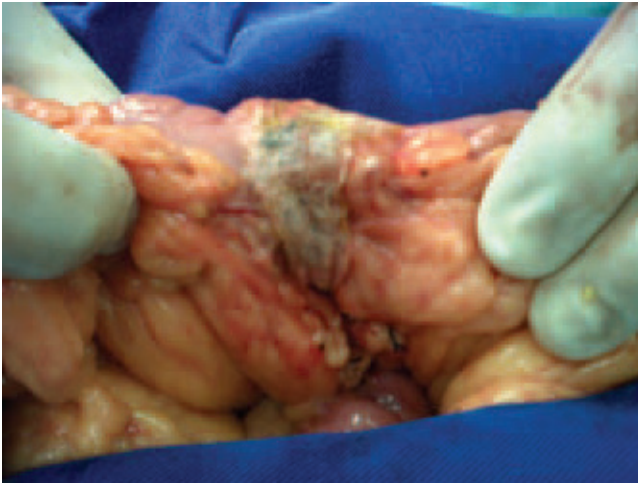
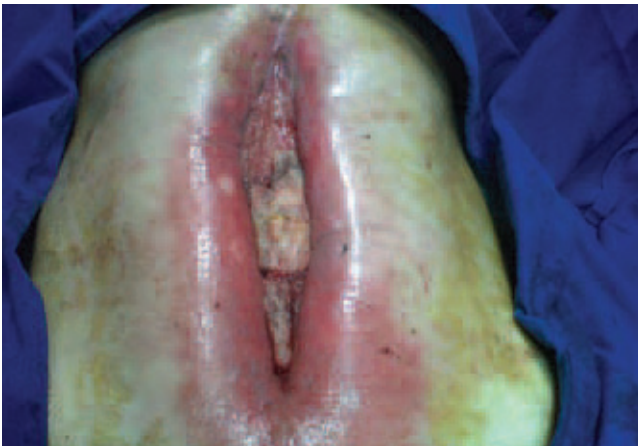## Discussion

In the year 2013, the anastomoses performed on the small intestine, colon and especially on the rectum still show sig-

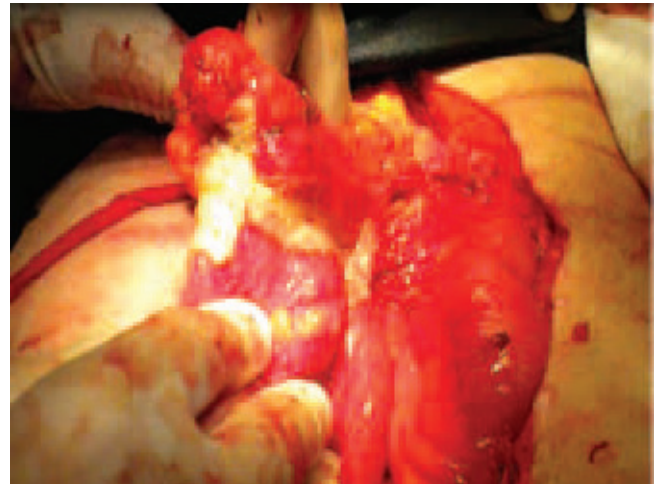**Table 1 – Baseline characteristics of the four patients submitted to procedures with intestinal anastomoses and extra-luminal use of HFTP - TachoSil®.**

Patient	Gender	Age (years)	Procedure	Type of anastomosis	Diagnosis	Postoperative complications
#1	F	59	Anterior rectal resection	Stapled	Neoplasia	No
#2	F	67	Left segmental colectomy	Hand-sewn	Neoplasia	No
#3	F	43	Enteroanastomosis	Hand-sewn	Enteral fistula with peritoneotomy	No
#4	M	41	Right ileocelectomy	Stapled	Enteral fistula	Yes (anastomosis dehiscence)

F, female; M, male.

**Fig. 2 – Final aspect of the anastomosis in patient 2 after protection with HFTP.****Fig. 3 – Final aspect of patient 3 after enteroanastomosis for enteric fistula closure in peritoneotomy area with HFTP protection.**

nificant rates of dehiscence. In recent years, developments in the field of colorectal surgery were mainly concentrated in staplers and disposable equipment mainly for laparoscopic techniques. Despite significant advances in this area, AD is found in a significant proportion of patients. Its consequences include reoperations, longer hospital stay and consequent increase in treatment costs, as well as the possibility of mortal-

**Fig. 4 – Final aspect of the functional termino-terminal ileo-transverse anastomosis in patient 4. In spite of the perfect technical condition and adequate protection with HFTP membrane, there was evolution to anastomotic dehiscence and death.**

ity.<sup>1</sup> Therefore, any technology or device aimed at reducing AD will have an impact on the outcome after these procedures.

Colorectal anastomoses by compression (Valtrac™ ring, magnetic rings, AKA-2™, endoluminal compression ring – endoCAR™, anastomotic compression clip – CAR) have also been studied and although they appear to be safe, they do not show superiority to hand-sewn or stapled anastomosis when AD rates are compared.<sup>9</sup>

Products designed to seal anastomotic sites are classified as intraluminal and extraluminal. HFTP (TachoSil®) is among the latter, used for secondary hemostasis mainly in liver surgery. In recent years, some publications have demonstrated the safety and feasibility of using this device in digestive anastomoses.

Pantelis et al.<sup>16</sup> evaluated the use of HFTP in rats for high-risk anastomoses (with only 4 separated absorbable suture points), compared to traditional anastomoses (with 8 separate absorbable suture points). The experiment showed that the use of the product in high-risk anastomoses resulted in lower mortality and dehiscence rates when compared to anastomotic procedures without the sealing mechanism.

Parker et al.<sup>10</sup> described the feasibility of applying HFTP in 24 patients undergoing anterior resection of the rectum. The product was well tolerated in procedures performed by lapa-

roscopic and conventional techniques, with no significant adverse effects. According to the authors, the use of HFTP seems to be facilitated by the use of circular staplers, except in male patients with a narrow pelvis. In our initial series of cases, the membrane was used only in conventional procedures, despite the possibility of using it with the laparoscopic approach.

The use of products for anastomosis protection may also be indicated in attempts to close enteral fistulae. There are scarce data in the literature regarding this indication, but the rational use of this strategy in high-risk patients with bad nutritional status represents the possibility of future studies. In our preliminary series of 4 patients, we used the HFTP in a patient with enteral fistula and peritoneotomy with good results.

Evidently, the use of products and devices such as HFTP does not replace adequate surgical technique and the basic principles for AD prevention, such as adequate blood supply in the anastomosed segment, no tension and good local conditions. Furthermore, the use of these alternative techniques is no guarantee of a healed anastomosis, as seen in patient 4 of this preliminary series. Even with the use of HFTP, dehiscence can occur, with consequent mortality.

The cost of these devices must also be considered. The routine use of products such as HFTP is not recommended, as anastomoses on the small and large intestine have been performed over the past 50 years with high success rates.

However, it is believed that patients with elevated risk of AD, such as those with deficient nutritional status, prior radiotherapy in the case of the anastomoses on the rectum and inflammatory bowel disease with previous use of corticoids, for instance, can benefit from this type of strategy here described. Randomized and controlled studies, with significant sample of patients, are required for more extensive conclusions regarding the actual role of anastomosis protection devices such as the HFTP.

---

## Conflicts of interest

The authors declare no conflicts of interest.

## REFERENCES

- Davis B, Rivadeneira DE. Complications of Colorectal Anastomoses. *Surg Clin N Am* 93 (2013) 61-87.
- Shogan BD, Carlisle EM, Alverdy JC, Umanskiy K. Do We Really Know Why Colorectal Anastomoses Leak? *J Gastrointest Surg*. 2013 May 21 [Epub ahead of print]
- Caulfield H, Hyman NH. Anastomotic Leak After Low Anterior Resection. *JAMA Surg*. 2013;148(2):177-182
- Slieker JC, Daams F, Mulder IM, Jeekel J, Lange JF. Systematic review of the technique of colorectal anastomosis. *JAMA Surg*. 2013 Feb;148(2):190-201.
- Daams F, Luyer M, Lange JF. Colorectal anastomotic leakage: Aspects of prevention, detection and treatment *World J Gastroenterol* 2013 April 21; 19(15): 2293-2297.
- Neutzling CB, Lustosa SA, Proenca IM, et al. Stapled versus hand-sewn methods for colorectal anastomosis surgery. *Cochrane Database Syst Rev* 2012;(2):CD003144.
- Lustosa SA, Matos D, Atallah AN, Castro AA. Stapled versus handsewn methods for colorectal anastomosis surgery. *Cochrane Database Syst Rev* 2001; (3): CD003144
- MacRae HM, McLeod RS. Handsewn vs. stapled anastomoses in colon and rectal surgery: a meta-analysis. *Dis Colon Rectum* 1998; 41: 180-189.
- Ho YH, Ashour MAT. Techniques for colorectal anastomosis. *World J Gastroenterol* 2010 April 7; 16(13): 1610-1621.
- Parker MC, Pohlen U, Borel Rinkes IHM, Delvin T. The application of TachoSil® for sealing colorectal anastomosis: a feasibility study. *Colorectal Disease* 2013;15(2):252-257.
- Bakker IS, Morks AN, Hoedemaker HOC, Burgerhof JGM, Leuvenink HG, Ploeg RJ, Havenga K. The C-seal trial: colorectal anastomosis protected by a biodegradable drain fixed to the anastomosis by a circular stapler, a multi-center randomized controlled trial. *BMC Surg*. 2012; 12: 23.
- Pommegaard HC, Achiam MP, Rosenberg J. External coating of colonic anastomoses: a systematic review. *Int J Colorectal Dis* 2012; 27:1247-1258.
- Vakalopoulos KA, Daams F, Wu Z, Timmermans L, Jeekel JJ, Kleinrensink GJ, Ham AVD, Lange JF. Tissue adhesives in gastrointestinal anastomosis: a systematic review. *Journal IF Surg Res* 2013; 180:290-300.
- Huh JW, Kim HR, Kim YJ. Anastomotic leakage after laparoscopic resection of rectal cancer: the impact of fibrin glue. *Am J Surg* 2010; 199(4):435-441.
- Rickenbacher A, Breitenstein S, Lesurtel M, Frilling A. Efficacy of TachoSil a fibrin-based haemostat in different fields of surgery - a systematic review. *Expert Opin Biol Ther* 2009; 9: 897-907.
- Pantelis D, Beissel A, Kahl P, Wehner S, Vilz TO, Kalf JC. The effect of sealing with a fixed combination of collagen matrixbound coagulation factors on the healing of colonic anastomoses in experimental high-risk mice models. *Langenbecks Arch Surg* 2010; 395(8):1039-1048.
- Nordentoft T, Rømer J, Sørensen M. Sealing of gastrointestinal anastomoses with a fibrin glue-coated collagen patch: a safety study. *J Invest Surg* 2007; 20: 363-9.
- De Stefano A, Bettarini F, Di Mare G, Neri A. Enteric anastomosis and Tachosil. *Minerva Chir* 2011; 66:183-8.