



Journal of Coloproctology

www.jcol.org.br



Review article

Cylindrical abdominoperineal resection rationale, technique and controversies

Patricio B. Lynn^a, Angelita Habr-Gama^a, Rodrigo O. Perez^{a,b,*}, Esteban Grzona^c, Charles Sabbagh^d, Joaquim J. Gama-Rodrigues^a

^aAngelita & Joaquim Gama Institute, São Paulo, SP, Brazil

^bUniversity of São Paulo School of Medicine, Gastroenterology Department, Colorectal Surgery Division, São Paulo, SP, Brazil

^cHospital Alemán de Buenos Aires, Surgery Division, Buenos Aires, Argentina

^dService de Chirurgie Viscérale et Digestive, Hôpital Nord, CHU d'Amiens, place Victor-Pauchet, France

ARTICLE INFO

Article history:

Received 31 July 2013

Accepted 15 August 2013

Keywords:

Rectal cancer

Total mesorectal excision

Abdominoperineal excision

Extralevator

Abdominoperineal excision

Cilíndric abdominoperineal excision

ABSTRACT

Surgery remains the cornerstone in rectal cancer treatment. Abdominoperineal excision (APE), described more than 100 years ago, remains as an important procedure for the treatment of selected advanced distal tumors with direct invasion of the anal sphincter or pre-operative fecal incontinence. Historically, oncological outcomes of patients undergoing APE have been worse when compared to sphincter preserving operations. More recently, it has been suggested that patients undergoing APE for distal rectal cancer are more likely to have positive circumferential resection margins and intraoperative perforation, known surrogate markers for local recurrence. Recently, an alternative approach known as “Extralevator Abdominoperineal Excision” has been described in an effort to improve rates of circumferential margin positivity possibly resulting in better oncological outcomes compared to the standard procedure. The objective of this paper is to provide a technical description and compare available data of both Extralevator and Standard abdominal perineal excision techniques.

© 2013 Elsevier Editora Ltda. Este é um artigo Open Access sob a licença de [CC BY-NC-ND](#)

Amputação abdominoperineal cilíndrica racional, técnica e controvérsias

RESUMO

Um dos pilares mais importantes no tratamento do câncer de reto ainda é a ressecção cirúrgica. A amputação de reto, ou excisão abdomino-perineal do reto (APE), descrita há mais de 100 anos, continua sendo um procedimento importante para o tratamento de tumores retais distais que invadem o aparelho esfíncteriano ou em casos de incontinência pré-operatória. Entretanto, os resultados oncológicos dos pacientes submetidos à APE são piores quando comparados com os pacientes submetidos a procedimentos com preservação esfíncteriana. Recentemente, foi sugerido que os pacientes submetidos à APE por câncer de reto distal apresentam mais frequentemente margem radial positiva, assim como perfuração intraoperatória do tumor, fatos reconhecidamente associados à recidiva local.

Palavras-chave:

Câncer de reto

Excisão total do mesorreto

Amputação abdominoperineal

Amputação abdominoperineal

extralevador

Amputação cilíndrica

* Corresponding author.

E-mail: Rodrigo.operez@gmail.com (R.O. Perez)

2237-9363 © 2013 Elsevier Editora Ltda. Este é um artigo Open Access sob a licença de [CC BY-NC-ND](#)

<http://dx.doi.org/10.1016/j.jcol.2013.08.003>

Uma nova técnica cirúrgica conhecida como “Amputação de reto extraelevador ou cilíndrica” tem sido descrita em um esforço para reduzir as taxas de margem radial positivas, sugerindo melhores resultados oncológicos quando comparada com o procedimento convencional. O objetivo deste trabalho é descrever a técnica deste procedimento e comparar seus resultados com os obtidos com a técnica convencional de acordo com a evidência disponível.

© 2013 Elsevier Editora Ltda. Este é um artigo Open Access sob a licença de [CC BY-NC-ND](#)

Introduction

Abdominoperineal excision (APE) was considered for many years as the “gold standard” for most distal and mid-rectal cancers. This operation, first described by Miles in 1908, remained unmodified until a few years ago.¹ On the other hand, treatment of rectal cancer underwent significant changes since original Miles’ description. Total mesorectal excision (TME) has become the “oncological standard of care” for patients with mid and distal rectal cancers² and sphincter preservation is now performed in a significant proportion of cases. In fact, the exact reasons for this increase in sphincter preservation rates such as the use of neoadjuvant treatment strategies, incorporation of surgical staplers into routine clinical practice and the acceptance of progressively shorter distal margins are still a matter of controversy.³

Nevertheless there is still a place for APE as it is necessary for advanced tumors of the distal rectum, particularly in the presence of direct anal sphincter involvement.⁴ Noteworthy, whereas oncological outcomes from sphincter preserving surgery have improved during the last years, APE results continue to be poor. Many studies have reported worse oncological outcomes associated with APE when compared to sphincter preserving procedures.⁵⁻⁹ Possible reasons for these findings may include worse intrinsic biological behavior associated with more distal rectal tumors and a potential selection bias of more advanced disease being more frequently managed by APE. However, technical difficulties regarding this operation resulting in a considerably higher rate of intraoperative specimen perforation and/or positive circumferential resection margins could be associated with this unfavorable outcome.^{6,8} In fact, CRM positivity and intraoperative perforation of the specimen are well-established surrogate markers for local recurrence in rectal cancer.¹⁰

It seems that surgeons are dealing with a surgery not only with questionable oncological outcomes, but also associated with considerable morbidity rates¹¹ and a significant negative impact on quality of life related to body image.¹²

Recent descriptions of modifications to standard APE, now known as the Extralevator Abdominoperineal Excision (ELAPE), aim to improve oncological appropriateness of the procedure by decreasing the risk of intraoperative tumor perforation and positive circumferential resection margins.¹³ Even though the expression “extralevator” may not be entirely appropriate, since the levator muscles are eventually transected (and not entirely resected), the term has gained widespread recognition (under “ELAPE”). In this setting, perhaps the name “Cylindrical APE” (CAPE) may be more appropriate. Regardless of the appropriate nomenclature, the aim of this report is to

describe the technique of the CAPE and review current data comparing it to the reported outcomes with the standard technique.

Rationale for CAPE

APE is associated with worse local recurrence and overall survival rates when compared to low anterior resection (LAR). Differences in local recurrence rates are quite significant, ranging from 15-33% for APE and 1-13% for LAR. In addition, 5-year overall survival rates after APE are within 38-60% and 57-76% for AR.^{5,6,8,9,14} These differences were also observed after the introduction and standardization of TME.

One of the first possible explanations for this finding was that APE was performed in more intrinsically aggressive cases (selection bias).⁵ However, the observation of increased positive circumferential resection margins after APE (41% vs. 12%) called into question the former argument and raised considerable concern regarding the appropriateness of the procedure.¹⁴

Two large prospective European trials confirmed the worse outcomes of patients undergoing APE. Both trials also found that positive circumferential margin and intraoperative tumor perforation were independent predictors of worse oncological outcome.^{8,15}

Another report of data from the Dutch TME trial, where 190 standard APE surgical specimens were analyzed, found that dissection through muscular, submucosa or even mucosal layers were present in more than one third of the cases.⁹ Surprisingly, APE was associated with significantly increased CRM positivity even among pT2 cancers, which clearly reflects incomplete resection.⁹ Supporting this data, a recent systematic review of published data on APE specimen audits revealed that APE was significantly associated with positive CRM and intraoperative perforation.¹⁶

In this setting, the need for an improvement in surgical technique in APE became evident. CAPE aims to improve circumferential resection margins transecting the levator muscles away from the rectum leaving a muscle cuff attached to the specimen, assuring proper circumferential margins and avoiding “waisting” of the surgical specimen precisely in the area where the tumor is located.

CAPE: Surgical technique

The abdominal part of the operation is performed according to the principles of total mesorectal excision (TME), meaning that dissection should be carried outside the mesorectal fascia. Importantly, dissection is stopped before reaching the

levator muscles in order to avoid “waisting” of the specimen that usually occurs at the level of the anorectal ring, very close to tumor location. The limits of the dissection are precise: upper third of the coccyx in the posterior part of the dissection, the seminal vesicles or uterine cervix in the anterior part and laterally at the level of the hypogastric plexuses.

Once these limits are reached, dissection is stopped and a surgical lap or gauze is left in the recently created retrorectal space in order to guide the perineal dissection. A silicone drain is usually left in the pelvis being exteriorized through the abdomen. The sigmoid colon is transected, an end-colostomy is created and the abdomen is closed before repositioning of the patient in a jack-knife position with legs apart (Fig. 1).

New drapes are placed and the anus is closed with a purse-string suture. A tear-shape incision is then performed with the tip of the incision at the level of the coccyx (Fig. 2).

Dissection proceeds externally to the subcutaneous portion of the external anal sphincter avoiding the reach of the ischioanal fat (Fig. 3), considering that tumor invasion of the ischioanal space is a rare event.

Dissection continues until the levator muscles are reached from below, identifying their attachments to the lateral wall

of the pelvis. Pelvic cavity is reached through a coccyx disarticulation transecting the pre-sacral fascia (Fig. 4).

In this step of the procedure, the lap/gauze placed in the retrorectal space is reached and removed.

The coccyx can be occasionally preserved. However, *en bloc* resection offers a larger working space and considerably facilitates identification of the abdominal plane of dissection and specimen extraction. Levator muscles are transected with electrocautery close to their lateral bony insertion/attachments (Fig. 5), allowing for a muscular cuff to be easily seen in the resected specimen.

After muscle transection is completed, the rectum is carefully everted anteriorly from the pelvic cavity through the perineal wound. This eversion of the specimen allows excellent visualization of the anterior rectal wall, vagina or seminal vesicles/prostate.

At this point of the procedure, perineal and anterior pelvic dissections are joined. Neurovascular bundles are exposed in the lateral walls of the pelvis and posterior prostate aspect.

Resection of the vagina (Fig. 6) or Denonvillier's fascia is considerably facilitated by the excellent view provided. Finally, the resection is completed with the division of the pelvic diaphragm muscles.

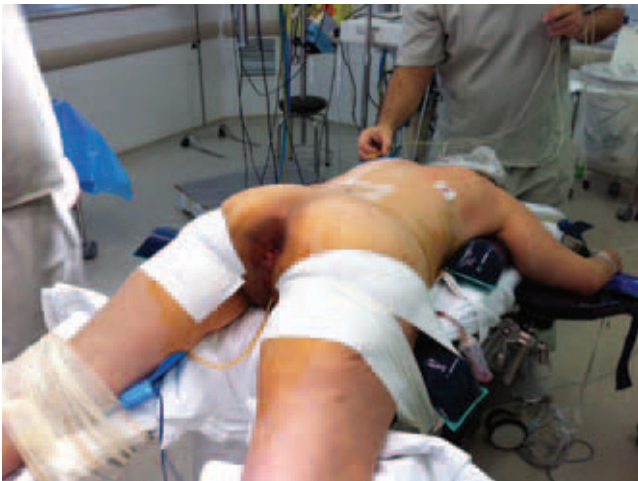

Fig. 1 – Patient in jack-knife position.

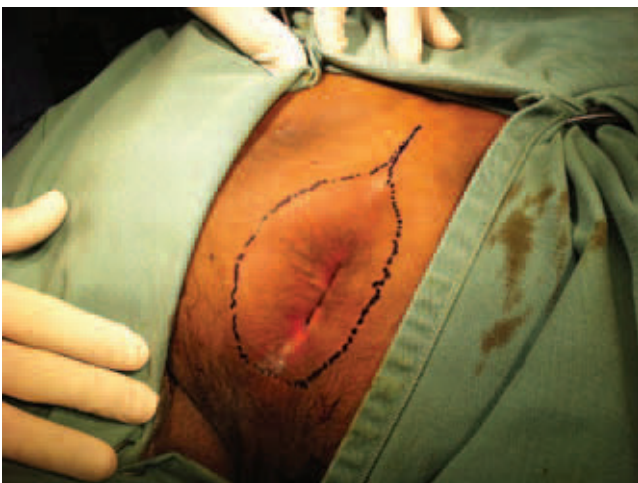

Fig. 2 – Anal closure and planning of the perineal incision.

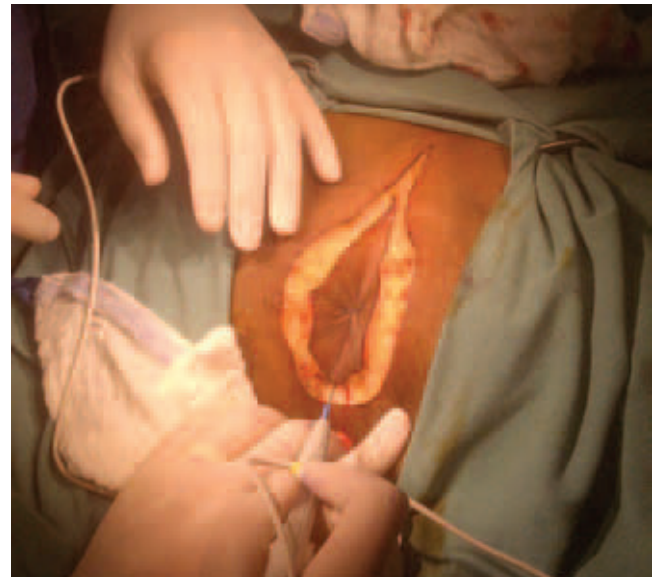


Fig. 3 – Incision and dissection of the subcutaneous plane.

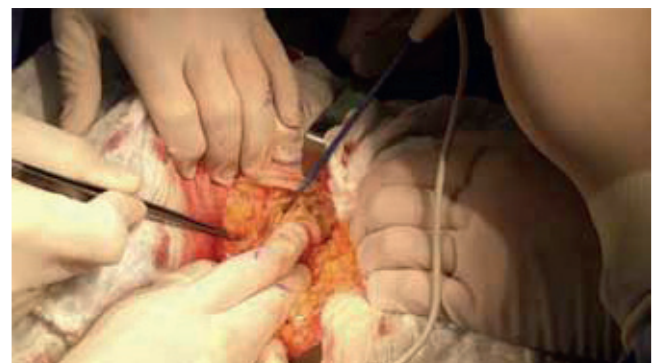

Fig. 4 – Coccygeal dissection and resection.

The final part of the procedure is the closure of the perineal defect (Fig. 7). After closing the pelvic floor, the previously placed drain is re-positioned so that pelvis and abdomen are drained with the same drain.

There are several options for closure of the perineal defect. Some authors have suggested the use of muscular grafts, especially in irradiated patients. Nevertheless, the use of simple closure with or without omental flap and/or biological meshes are valid options that have been reported with acceptable outcomes in selected cases, particularly in smaller perineal defects. After skin closure, wound length is not significantly different when compared to standard APE.¹⁷

Final specimen shows no “waisting” at the level of the anorectal ring. Instead, a cuff of extralevator muscles can be seen attached to the rectum (Fig. 8 and 9).

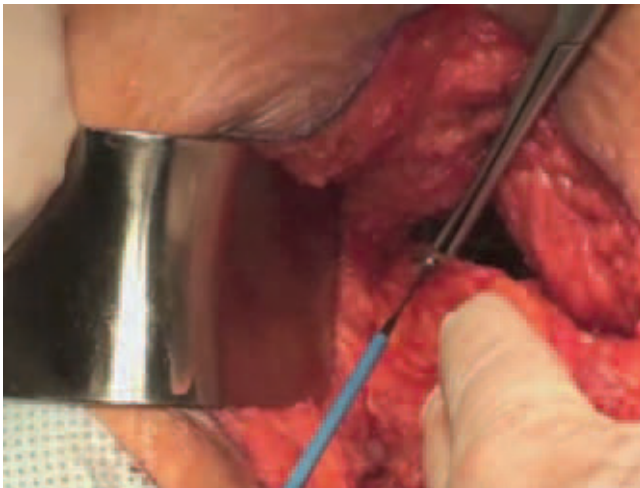


Fig. 5 – Transection of levator muscles under direct visualization.

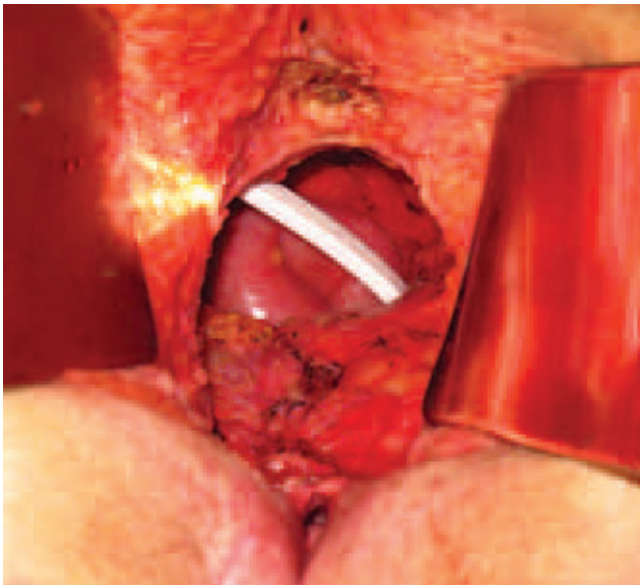


Fig. 6 – Perineal view after CAPE and closure of the posterior vaginal wall.

Controversies and results

Indications for CAPE are the same of APE: tumors with direct invasion of the anal sphincter, distal rectal lesions in incontinent patients and impossibility to achieve a safe distal margin with a sphincter sparing technique. However, there is still controversy whether CAPE should replace standard APE or should be considered as an alternative approach for selected patients.

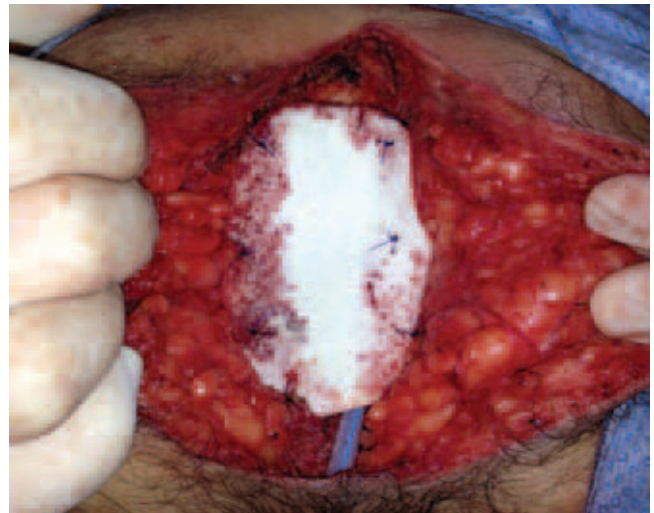


Fig. 7 – Perineal defect repair using a biological mesh after CAPE.

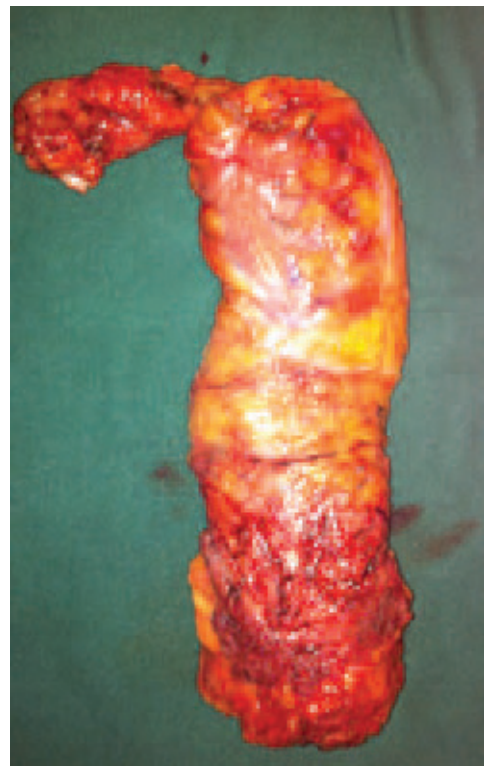

Fig. 8 – Specimen after CAPE with no “waisting” near the anorectal ring.

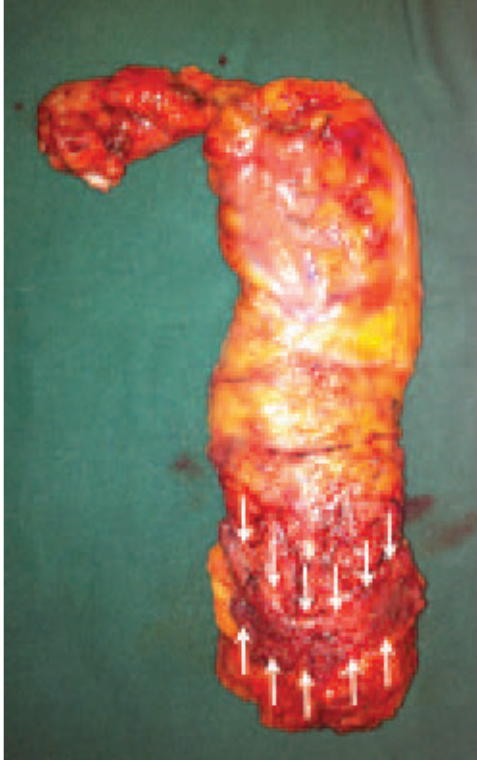


Fig. 9 – Specimen with indication of significant amount of levator muscles attached (white arrows).

The decision of performing a CAPE must be taken preoperatively based on staging information provided by imaging modalities. In this setting, MRI has proven to be efficient in differentiating those tumors amenable to be treated with surgery through excision of the mesorectal plane from those requiring dissection through the “extralevator plane”.¹⁸

In the seminal multicentric study with 300 abdominoperineal excisions (176 CAPEs & 124 APEs) CAPE was compared to standard APE. CAPE was significantly associated with less positive circumferential margin rate (20% vs. 49% $p = 0.001$). Additionally, intraoperative perforation rates were also less frequent (8 vs. 28% $p = 0.001$). Finally, the authors also measured the amount of tissue resected around the distal centimeters of the specimen and CAPE was superior to APE (median resection area 2120 mm² for CAPE vs. 1259 mm² for APE; $p < 0.001$).¹⁹

However, there are a few problems with this particular study. First, intrinsic limitations of a non-randomized study may have accounted, in some extent, for the significant differences observed between CAPE and APE. Also, the considerably high rate of positive CRM (49%) among patients undergoing standard APE has been questioned as not being a proper control group. In fact, recent studies of standard APE in specialized centers have reported much lower rates of CRM positivity.²⁰ Even though these rates were not compared to CAPE, the CRM positivity rate of 15% seemed to compare favorably to the previously reported 20% with CAPE in the original multicenter study.²⁰

More recently, a revision of more than 5000 patients resulted in significant differences in CRM positivity and intra-

operative perforation rates between CAPE and standard APE (9.6% vs. 15.4% $p = 0.022$ and 4.1% vs. 10.4% $p = 0.004$ respectively). CRM positivity rates of CAPE in this report reached < 10% while standard APE remained in the 15% range. Also with a median follow-up of 68 months, local recurrence rates were lower for CAPE (6.6% vs. 11.9%; $p < 0.001$). Curiously, in this particular study, the performance of the procedure in the Lloyd-Davies was a significant predictor of CRM positivity and intraoperative perforation. Again, even though groups (CAPE and standard APE) are not perfectly comparable, CAPE seems to be associated with CRM positivity < 10% comparing favorably with the rates for standard APE.²¹

In a retrospective study from a single institution comparing standard APE in the supine vs. jack-knife position, both approaches resulted in similar pathological findings and postoperative morbidity rates. The CRM positivity was considerably lower (even though not statistically significant) in the group of patients operated in jack-knife position (2.3 vs. 8.5%).²² Unfortunately, patients in the supine position were more frequently managed with neoadjuvant CRT, making it impossible to draw definitive conclusions.

In another Swedish report of a single institution with 79 patients undergoing CAPE vs. the same number of standard APEs, positive radial margin rates (17% vs. 20%), intraoperative rectal perforation (13% vs. 10%) and local recurrence (7% in each group) were similar with both techniques. Again these numbers should be considered with caution since authors admit that the pathological protocol for specimen analysis changed during the study period and may have accounted for differences in CRM assessment. Furthermore, the CAPE group presented a significantly shorter follow-up (probably related to the more recent cases in their experience), suggesting that a learning curve effect could have affected results of CAPE when compared to standard APE (with an already long-lasting surgical experience).²³

Despite the potential benefits of CAPE in terms of CRM positivity and intraoperative perforations, the procedure seems to be associated with higher morbidity related to healing of the perineal wound. In fact, in the aforementioned multicentric study, perineal wound complications were significantly more frequent than in the standard APE group (38 vs. 20% $p = 0.019$).¹⁹ Indeed, this is expected due to the greater amount of perirectal tissue being resected. In a recent retrospective single center series with 30 patients, almost half of the patients (46%) presented perineal complications. Noteworthy, all the complications were managed conservatively.²⁴ There is also a retrospective review where CAPE and APE patients presented a similar rate of perineal complications (23.2% vs. 26.1% $p = 0.183$).²¹ Despite being a potentially more morbid procedure, early reports have shown that, when using specific quality of life questionnaires, APE and CAPE patients presented similar results.²⁵

Finally, there is an issue usually not considered in most of the studies due to its subjectivity. Visualization of the surgical field (perineum) and surgeon’s ergonomics is definitely one of the major advantages of CAPE performed in jack-knife position. In the standard APE approach, the surgeon works in a limited space between the patient’s legs, being most of the times, if not always, the only one seeing what is going on deep inside the perineum whereas the assistant is retracting

tissues in an uncomfortable position. Under these circumstances, dissection of the anterior rectal wall becomes a real surgical challenge even for a highly experienced surgeon.

On the contrary, in jack-knife position, everyone in the surgical field (surgeon, assistants and even residents in the room) have excellent view and, therefore, they are able to actively participate of the procedure. Even though this approach demands additional time for repositioning the patient, the benefits in surgical field visualization probably allows a faster perineal phase of the operation.

Finally, it should be noted that the abdominal phase of the operation may be performed by open or minimally invasive approach. Considering that pelvic dissection does not go down to the level of the levator muscles (saving technically demanding and time consuming maneuvers) and that there is no need to mobilize the splenic flexure or to open the abdomen, since the specimen is extracted through the perineum, the laparoscopic approach for CAPR may combine the "best of both worlds".²⁶

In conclusion, CAPE may offer significant advantages over standard APE in terms of CRM positivity and intraoperative perforation even though the lack of randomized studies may limit definitive conclusions. Improved exposure and visualization of the surgical field associated with the jack-knife position may also account for some of these advantages. This useful surgical approach should definitely be incorporated in the armamentarium of colorectal surgeons dealing with rectal cancer patients and may, in the near future, replace standard APE approach for the management of selected and perhaps the majority of rectal cancer patients requiring resection of distal portion of the rectum and anus.

Conflicts of interest

The authors declare no conflicts of interest.

REFERENCES

- Campos FG, Habr-Gama A, Nahas SC, Perez RO. Abdominoperineal excision: evolution of a centenary operation. *Dis. Colon Rectum*. 2012. pp. 844-53.
- Heald RJ, Ryall RD. Recurrence and survival after total mesorectal excision for rectal cancer. *Lancet*. 1986 Jun 28;1(8496):1479-82.
- Rullier E, Laurent C, Bretagnol F, Rullier A, Vendrely V, Zerbib F. Sphincter-saving resection for all rectal carcinomas: the end of the 2-cm distal rule. *Ann. Surg*. 2005 Mar;241(3):465-9.
- Kapiteijn E, Marijnen CA, Nagtegaal ID, Putter H, Steup WH, Wiggers T, et al. Preoperative radiotherapy combined with total mesorectal excision for resectable rectal cancer. *N. Engl. J. Med*. 2001 Aug 30;345(9):638-46.
- Heald RJ, Smedh RK, Kald A, Sexton R, Moran BJ. Abdominoperineal excision of the rectum--an endangered operation. *Norman Nigro Lectureship. Diseases of the colon and rectum*. 1997 Jul;40(7):747-51.
- Law WL, Chu KW. Abdominoperineal resection is associated with poor oncological outcome. *Br J Surg*. 2004 Nov;91(11):1493-9.
- Marr R, Birbeck K, Garvican J, Macklin CP, Tiffin NJ, Parsons WJ, et al. The Modern Abdominoperineal Excision. *Ann. Surg*. 2005 Jul;242(1):74-82.
- Wibe A, Møller B, Norstein J, Carlsen E, Wiig JN, Heald RJ, et al. A national strategic change in treatment policy for rectal cancer--implementation of total mesorectal excision as routine treatment in Norway. A national audit. *Diseases of the colon and rectum*. 2002 Jul;45(7):857-66.
- Nagtegaal ID, van de Velde CJH, Marijnen CAM, van Krieken JHJM, Quirke P, Dutch Colorectal Cancer Group, et al. Low rectal cancer: a call for a change of approach in abdominoperineal resection. *J. Clin. Oncol*. [Internet]. 2005 Dec 20;23(36):9257-64. Available from: <http://eutils.ncbi.nlm.nih.gov/entrez/eutils/elink.fcgi?dbfrom=pubmed&id=16361623&retmode=ref&cmd=prlinks>
- Nagtegaal ID, Marijnen CAM, Kranenbarg EK, van de Velde CJH, van Krieken JHJM, Pathology Review Committee, et al. Circumferential margin involvement is still an important predictor of local recurrence in rectal carcinoma: not one millimeter but two millimeters is the limit. *Am. J. Surg. Pathol*. 2002 Mar;26(3):350-7.
- Pemberton JH. How to treat the persistent perineal sinus after rectal excision. *Colorectal Dis*. 2003 Sep;5(5):486-9.
- Gervaz P, Bucher P, Konrad B, Morel P, Beyeler S, Lataillade L, et al. A Prospective longitudinal evaluation of quality of life after abdominoperineal resection. *J Surg Oncol*. 2008 Jan 1;97(1):14-9.
- Holm T, Ljung A, Häggmark T, Jurell G, Lagergren J. Extended abdominoperineal resection with gluteus maximus flap reconstruction of the pelvic floor for rectal cancer. *Br J Surg*. 2007 Feb;94(2):232-8.
- Marr R, Birbeck K, Garvican J, Macklin CP, Tiffin NJ, Parsons WJ, et al. The modern abdominoperineal excision: the next challenge after total mesorectal excision. *Ann. Surg*. 2005 Jul;242(1):74-82.
- Nagtegaal ID, Quirke P. What is the role for the circumferential margin in the modern treatment of rectal cancer? *J. Clin. Oncol*. 2008 Jan 10;26(2):303-12.
- How P, Shihab O, Tekkis P, Brown G, Quirke P, Heald R, et al. A systematic review of cancer related patient outcomes after anterior resection and abdominoperineal excision for rectal cancer in the total mesorectal excision era. *Surg Oncol*. 2011 Dec;20(4):e149-55.
- Shihab OC, Heald RJ, Holm T, How PD, Brown G, Quirke P, et al. A Pictorial Description of Extralevator Abdominoperineal Excision for Low Rectal Cancer. *Colorectal Disease*. 2012 Jul;no-no.
- Shihab OC, How P, West N, George C, Patel U, Quirke P, et al. Can a novel MRI staging system for low rectal cancer aid surgical planning? *Diseases of the colon and rectum*. 2011 Oct;54(10):1260-4.
- West NP, Anderin C, Smith KJE, Holm T, Quirke P, European Extralevator Abdominoperineal Excision Study Group. Multicentre experience with extralevator abdominoperineal excision for low rectal cancer. *Br J Surg* [Internet]. 2010 Feb 23;97(4):588-99. Available from: <http://eutils.ncbi.nlm.nih.gov/entrez/eutils/elink.fcgi?dbfrom=pubmed&id=20186891&retmode=ref&cmd=prlinks>
- Messenger DE, Cohen Z, Kirsch R, O'Connor BI, Victor JC, Huang H, et al. Favorable pathologic and long-term outcomes from the conventional approach to abdominoperineal resection. *Diseases of the colon and rectum*. 2011 Jul;54(7):793-802.
- Stelzner S, Koehler C, Stelzer J, Sims A, Witzigmann H. Extended abdominoperineal excision vs. standard abdominoperineal excision in rectal cancer—a systematic overview. *Int J Colorectal Dis*. 2011 May 21;26(10):1227-40.
- de Campos-Lobato LF, Stocchi L, Dietz DW, Lavery IC, Fazio VW, Kalady MF. Prone or Lithotomy Positioning During an Abdominoperineal Resection for Rectal Cancer Results in Comparable Oncologic Outcomes. *Diseases of the colon and rectum*. 2011 Aug;54(8):939-46.

23. Asplund D, Haglind E, Angenete E. Outcome of extralevator abdominoperineal excision compared with standard surgery. Results from a single centre. *Colorectal Dis.* 2012 Jan 4.
24. Welsch T, Mategakis V, Contin P, Kulu Y, Büchler MW, Ulrich A. Results of extralevator abdominoperineal resection for low rectal cancer including quality of life and long-term wound complications. *Int J Colorectal Dis.* 2012 Nov 21;28(4):503-10.
25. Vaughan-Shaw PG, Cheung T, Knight JS, Nichols PH, Pilkington SA, Mirnezami AH. A prospective case-control study of extralevator abdominoperineal excision (ELAPE) of the rectum versus conventional laparoscopic and open abdominoperineal excision: comparative analysis of short-term outcomes and quality of life. *Tech Coloproctol.* 2012 Jul 10;16(5):355-62.
26. Singh B, Lloyd G, Nilsson PJ, Chaudhri S. Laparoscopic extralevator abdominal perineal excision of the rectum: the best of both worlds. *Tech Coloproctol.* 2011 Dec 15;16(1):73-5.