


Available online at [www.sciencedirect.com](http://www.sciencedirect.com)

ScienceDirect

journal homepage: [www.elsevier.com/locate/ijnt](http://www.elsevier.com/locate/ijnt)

## Original Article

# Brain morphometric changes and cognitive domain correlations in early mild to moderate traumatic brain injury



Ashok Munivenkatappa<sup>a</sup>, Indira D. Bhagavatula<sup>a,\*</sup>, Dhaval Shukla<sup>a</sup>,  
Neeraj Upadhyay<sup>a</sup>, Shobini L. Rao<sup>b</sup>, D.K. Subbakrishna<sup>c</sup>,  
Jamuna Rajeswaran<sup>b</sup>, Rose D. Thomas<sup>d</sup>

<sup>a</sup> Department of Neurosurgery, National Institute of Mental Health and Neurosciences, Bangalore, Karnataka, India

<sup>b</sup> Department of Clinical Psychology, National Institute of Mental Health and Neurosciences, Bangalore, Karnataka, India

<sup>c</sup> Department of Biostatistics, National Institute of Mental Health and Neurosciences, Bangalore, Karnataka, India

<sup>d</sup> Department of Neuroimaging and Interventional Radiology, National Institute of Mental Health and Neurosciences, Bangalore, Karnataka, India

## ARTICLE INFO

## Article history:

Received 16 July 2012

Accepted 23 October 2013

Available online 9 November 2013

## Keywords:

Traumatic brain injury

Brain measures

Volume and thickness

## ABSTRACT

**Background:** TBI is associated with whole brain volume and thickness loss based on validated volumetric methods using MRI images.

**Aims:** To look for early psychological and concussion symptoms correlation with volumetric data.

**Methods:** We used FreeSurfer software to identify significant clusters using minimum 2 thresholds, FDR 0.15 and simulation 0.01.

**Results:** There was no significant regions of 22 TBI patients (mean 27.7 years) compared to 20 (mean 27.1 years) age and gender match controls approximately 13 weeks of brain injury. Among TBI patients significant decrease in cortical volume and thickness was seen.

**Conclusion:** Few psychological domains showed significant clusters with weak correlation.

Copyright © 2013, Neurotrauma Society of India. All rights reserved.

## 1. Introduction

Approximately 21.6 million Indian populations sustain road injuries.<sup>1</sup> Most commonly head injuries are caused by road traffic accidents (RTAs), nearly 70–80% of these, sustained mild to moderate head injuries. After sustaining these injuries about 30%–80% is estimated to have somatic and/or neuropsychiatric symptoms, up to 2–4 months.<sup>2,3</sup> Various

protocols of magnetic resonance imaging (MRI) have produced quantitative evidence of diffuse and focal brain injury.<sup>4</sup> These compromised brain integrity has been linked to neuropsychological and functional outcome.<sup>5,6</sup>

FreeSurfer is an automated MRI brain imaging software for structural and functional brain mapping. It contains comprehensive tools, including; skull stripping, B1 bias field correction, brain segmentation, subjects brain registration

\* Corresponding author. Tel.: +91 8026995409.

E-mail address: [drindiradb@gmail.com](mailto:drindiradb@gmail.com) (I.D. Bhagavatula).

0973-0508/\$ – see front matter Copyright © 2013, Neurotrauma Society of India. All rights reserved.

<http://dx.doi.org/10.1016/j.ijnt.2013.10.006>

with stereotaxic atlas, reconstruction of white and gray matter, measuring and labeling volume and thickness of cortical and subcortical structures, and volume and surface based analysis.<sup>7</sup> Previous studies have used volumetric analysis software to describe traumatized brain volume and thickness changes that have potential relationship with neurocognitive outcomes and depressive symptoms.<sup>5,6,8</sup>

The purpose of the present study is to identify changes in total brain volume and thickness in mild to moderate head injured patients with neuropsychological domains and concussion symptoms using validated quantification and analysis software.

## 2. Methods

### 2.1. Subjects

Twenty-two right handed patients with mild to moderate brain injury (Males-17, females-5, mean age  $27.7 \pm 6.5$  years) were recruited as inpatients at National Institute of Mental and Neurosciences, Bangalore. Exclusion criteria included prior neuropsychiatric illness/symptoms, alcohol or drug dependence, past history of head injury, neuro infection, chronic neurological diseases, and any contraindication to MRI. All patients' clinical details were documented on standard proforma. Their admission Glasgow coma scale (GCS) ranged from 9 to 15, 13 patients had mild GCS scores 14–15 and 9 patients had moderate GCS score 13–9. No patients in

study group needed resuscitation. All patients were evaluated with CT scan and managed accordingly. The patients were followed up with mean duration of 13 weeks (6–26 weeks) for neurological, neuropsychological, and neuroimaging examinations. Summary of demographic characteristics of the subject groups Table 1. An informed consent was taken from all the patients and the study was performed under guidelines of institute's ethic's committee.

### 2.2. Healthy volunteers

Twenty healthy right handed normal subjects were selected to create a control group matched to age and gender to that of brain injured group. The controls were recruited from our institution and consisted of 16 men and 4 women with a mean age of 27.1 years ( $\pm 6.3$  years). They were scanned on the same scanner with the same MRI protocols as the brain injured patients but did not undergo neuropsychological examination.

### 2.3. MRI method

MRI scans were acquired in the Siemens 3T Magnetom Skyra Scanner. The T1-weighted Magnetization Preparation Rapid Acquisition Gradient Echo (MP-RAGE) sequence used for morphometric analysis provided excellent gray-white matter contrast. TR 1600 ms, TE 2.13 ms, Slice Thickness 0.9 mm, Slices per slab 176, FOV 240 mm, Voxel Size  $0.9 \times 0.9 \times 0.9$  mm, acquisition time 3 min 44 s.

**Table 1 – Summary of demographic characteristics, neuropsychological test and concussion symptoms of the subject groups.**

Age	Gender	GCS score	Duration	DSST	ANT	TT	AVLT total	AVLT LTPR	FTT RT	FTT LT	CFT copy	CFT DR	RPCSQ
38	M	6	6	28	12	5	5	95	30	28	50	15	2
26	M	12	12	3	10	20	5	80	5	3	15	20	0
19	F	23	23	67	5	20	30	90	90	67	95	60	2
29	M	14	14	12	20	10	5	30	80	12	20	25	1
21	M	10	10	9	5	30	5	5	5	9	95	5	2
36	F	12	12	19	5	30	5	5	40	19	50	50	6
22	M	14	14	12	5	10	5	5	5	12	15	15	1
22	M	10	10	15	25	30	5	15	25	15	5	5	0
26	M	12	12	9	60	30	30	10	30	9	5	5	2
33	M	12	12	38	30	20	30	40	20	38	40	25	1
22	M	10	10	0	25	40	40	40	5	0	0	0	0
30	F	8	8	7	40	20	15	10	50	7	50	30	5
19	M	12	12	91	9	20	5	40	5	91	30	40	2
40	M	24	24	13	70	10	20	15	40	13	95	60	5
20	M	11	11	18	5	5	5	5	5	18	5	5	4
24	M	12	12	33	5	60	95	15	30	33	30	20	0
25	M	14	14	27	10	25	40	20	50	27	95	70	4
30	M	10	10	61	30	70	40	10	50	61	34	25	2
37	F	24	24	3	5	50	20	95	15	3	95	10	6
25	M	7	7	97	95	30	60	15	40	97	5	10	0
35	M	9	14	0	5	5	5	95	5	5	5	5	4
32	F	15	26	66	10	50	15	5	25	50	50	15	4

GCS – Glasgow coma scale, DSST – digit symbol substitution test, ANT – animal naming test, TT – token test, AVLT – auditory verbal learning test, LTPR – long term percent retention, FTT – finger tapping test, RT – right hand, LT – left hand, CFT – complex figure test, DR – delayed recall, RPCSQ – Rivermade post-concussion symptom questionnaire.

#### 2.4. Neuropsychological assessment and concussion symptoms

On the day of the scan, patients underwent neuropsychological testing using an extensive battery of NIMHANS neuropsychology.<sup>9</sup> Tests for complex cognitive processes such as attention, executive functions, and memory were used. The Finger Tapping test (FTT) was used to measure motor speed where patient has to tap his index finger on tapping key mounted on box. The visuo constructive ability was tested using the Rey's Complex Figure Test (CFT). For visuomotor coordination, motor persistence, sustained attention and response speed digit symbol substitution test (DSST) was administered. The animal naming test (ANT) was administered for category fluency. The Auditory verbal learning test (AVLT) consists of words designating familiar objects like vehicles, tools, animals and body parts mainly for encoding and retrieval. Token test (TT) was administered for verbal comprehension. The test scores were compared with normal population scores matched for age, gender and education.<sup>9</sup> Patients' percentile scores less than 15 were considered significant.

Outcome of interest after head injury are improvement in functioning and quality of life, measures of activity and participation, measure of psychological and psychosocial adjustment.<sup>10</sup> Rivermade post-concussion symptoms questionnaire (RPCSQ) was used to assess the post-traumatic symptoms. The increase in scores signifies that head injury patient is suffering from more concussion symptoms. Summary of Neuropsychological test result and concussion symptoms is depicted in Table 1.

#### 2.5. MR image analysis

Automated measurements of brain volumes were performed using FreeSurfer version 5.1.0 software which is freely available on website (<http://surfer.nmr.mgh.harvard.edu/>). It was developed by Martinos center for biomedical imaging, Massachusetts, US. The work was done on a same operating system and up gradation of version and software were highly restricted. The raw data was converted into analyzable files format and anterior and posterior commissural fixation was done. Then further removal of non-brain tissue, bias field correction, automated Talairach transformation, segmentation of subcortical white matter and gray matter, and intensity normalization<sup>11–13</sup> was done using the automated scripts in FreeSurfer. We measured total cerebral, total gray and total white matter volume, and thickness involving the cerebral hemispheres as well as selected cortical structure gray matter volume and thickness. The dmean of total brain volume was calculated before statistical analysis.

#### 2.6. Statistical analysis

FreeSurfer Query, Design, Estimate, Contrast (qdec) was used for statistical analysis. We examined the use of volume and absolute change in volume among traumatic patients compared with controls with respect to age. The brain volume measures' association with cognitive tests and outcome among injured patients was also noted. The significant

threshold was adjusted (uncorrected) to minimum 2 (all vertices <0.01) and maximum 5 (all vertices <0.00001).<sup>6</sup> Multiple comparison corrections at a false discovery rate (FDR) of 0.15 and 0.05 were utilized.<sup>5,14</sup> The cluster wise correction for multiple comparisons was done by Monte Carlo simulation considering absolute value with *p*-value threshold of 0.01. The statistically significant cluster is reported in standard coordinate space (x,y,z) with *p*-value and confident intervals. The strength of the correlation between traumatic and normal volume measures was determined using the Spearman rank correlation coefficient (rs) using SPSS software (version 15.0).

### 3. Results

#### 3.1. Demographic and clinical characteristics

The median age at injury for this population was 29.5 years, all were right handed. Thirteen patients had mild head injury and nine patients had moderate head injury. The cause for majority of injuries was road traffic accident. MRI scan was done with median duration of 11.5 weeks with range 6–26, during which neuropsychological assessment was done. Neuropsychological test showed <15 percentile in; DSST in 9 (40.9%), ANT in 11 (50%), TT in 7 (31.8%), copy CFT in 7 (31.8%), delay CFT in 9 (40.9%), total AVLT in 11 (50%), and long term percent retention AVLT in 12 (54.4%) patients. Fourteen patients had two or more concussion symptoms (assessed by RPCSQ).

#### 3.2. Right and left hemisphere measures assessed with T1-weighted imaging among controls

The uncorrected clusters for both volume and thickness available at minimum threshold 2 (*p*-0.01) could not withstand for multiple comparisons corrections (FDR) at 0.15.

#### 3.3. Right and left hemisphere measures assessed with T1-weighted imaging among TBI

Among traumatic population, Spearman's rank order correlation was performed for all available brain region measures with age, using FDR correction at 0.15, Monte Carlo Z simulation of 0.01, absolute value. Thickness significant clusters were 4 in left (rs -0.826, *p* < 0.0001) and 5 in right (rs -0.917, *p* < 0.0001) hemisphere. Volume significant clusters were 2 in left (rs -0.728, *p* < 0.001) and 3 in right (rs -0.625, *p* < 0.006) hemisphere (Table 2, Fig. 1).

#### 3.4. Brain volume measures assessed with T1-weighted imaging compared between TBI and controls, and among mild and moderate TBI patients

The uncorrected clusters for both volume and thickness available at minimum threshold 2 (*p*-0.01) could not withstand for multiple comparison corrections (FDR) at 0.15.

**Table 2 – Right and left significant hemispheric cluster among TBI with respect to age.**

FDR – 0.05, Monte Carlo Z simulation – 0.01, absolute value

**Thickness**

Left ( <i>p</i> -value, CI)	Right ( <i>p</i> -value, CI)
Pars opercularis 0.0001, 0.00–0.0002	Inferior temporal 0.0001, 0.00–0.0002
Superior frontal 0.0001, 0.00–0.0002	Superior frontal 0.0001, 0.00–0.0002
Pars orbitalis 0.0001, 0.00–0.0002	Caudal middle frontal 0.0001, 0.00–0.0002
Middle temporal 0.008, 0.007–0.009	Pars triangularis 0.0001, 0.00–0.0002
	Medial orbitofrontal 0.0001, 0.00–0.0002
<b>Volume</b>	
Pars orbitalis 0.0001, 0.00–0.0002	Caudal middle frontal 0.0001, 0.00–0.0002
Superior parietal 0.006, 0.005–0.007	Superior frontal 0.0003, 0.0001–0.0005
	Pars orbitalis 0.0001, 0.00–0.0002

FDR – false discovery rate, CI – confident interval.

**3.5. Association of neuropsychological measures and concussion symptoms with volume measures in brain injured patients**

On performing Spearman's rank order correlation for all available brain region measures, by including neuropsychological domains, and outcome measures using FDR corrections at 0.15, there were significant variables for ANT ( $r_s$  0.171,  $p > 0.05$ ) and TT ( $r_s$  0.136,  $p > 0.05$ ) listed in Table 3, further on

Monte Carlo Z simulation of 0.01 absolute value, only one region was available for ANT (refer Table 3).

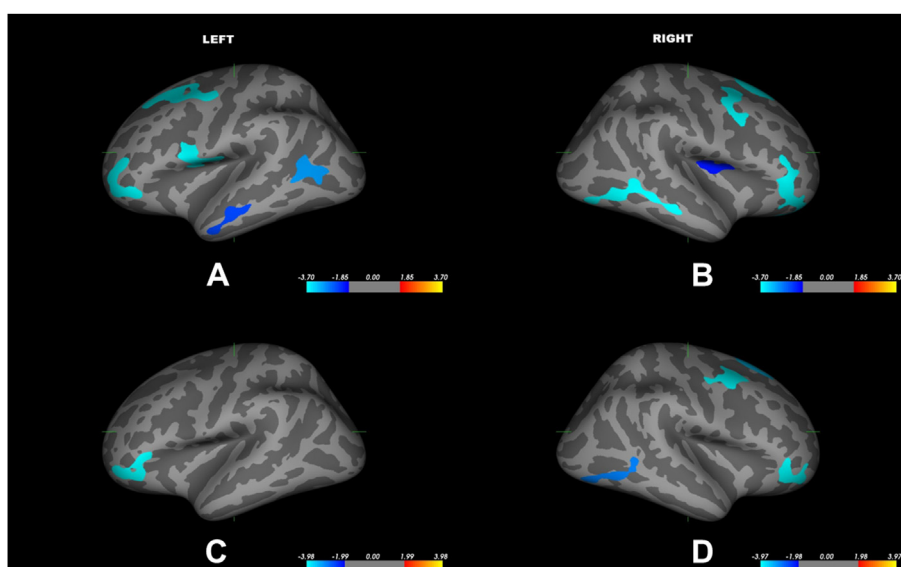
Interestingly the trend (uncorrected clusters) of decrease in brain thickness was seen in both hemispheres with increase in concussion symptoms (Fig. 2).

**4. Discussion**

The present study data showed that diffuse changes in cerebral gray matter can be observed after traumatic brain injury. These changes were found approximately three months after the injury. There was no significant decrease in gray matter concentration in the brain injured patients compared with age and sex matched controls. Both the current study and others show that changes in cerebral integrity related to traumatic brain injury occur in a variety of neuro anatomical regions including the frontal, parietal and temporal lobes.<sup>4,6</sup> Furthermore, this study emphasizes that brain measure changes during early period of post-injury can be weakly correlated with few cognitive domains.

The result of age and gender matched 20 healthy volunteer brain measures analyzed with aging, showed 23 clusters in left and 15 clusters in right with threshold 2 ( $p < 0.01$ ), no significant cluster survived with FDR 0.15. Our study data on healthy volunteers shows both volume and thickness decreases moderately with aging, but on multiple comparisons no regions survived.

Our study data shows that traumatic patient brain thickness decreases strongly with aging, using FDR 0.05, Monte Carlo Z simulation 0.01, showed significant clusters; 4 regions in left ( $r_s$  -0.826,  $p < 0.0001$ ) and 5 regions in right hemisphere ( $r_s$  -0.917,  $p < 0.0001$ ). Traumatic patient brain volume decreases moderately with aging, using FDR 0.05, Monte Carlo Z simulation 0.01, showed significant clusters; two



**Fig. 1 – Surface maps of cortical region thinning of traumatic patients with increase in age obtained after Monte Carlo Z simulation, 0.01, absolute value. On the inflated brain, dark gray regions represent gyri and lighter areas represent sulci. The figure A & B depicts significant clusters for thickness, in which A for left and B for right hemisphere, C & D depicts significant clusters for volume, in which C for left and D for right hemisphere.**

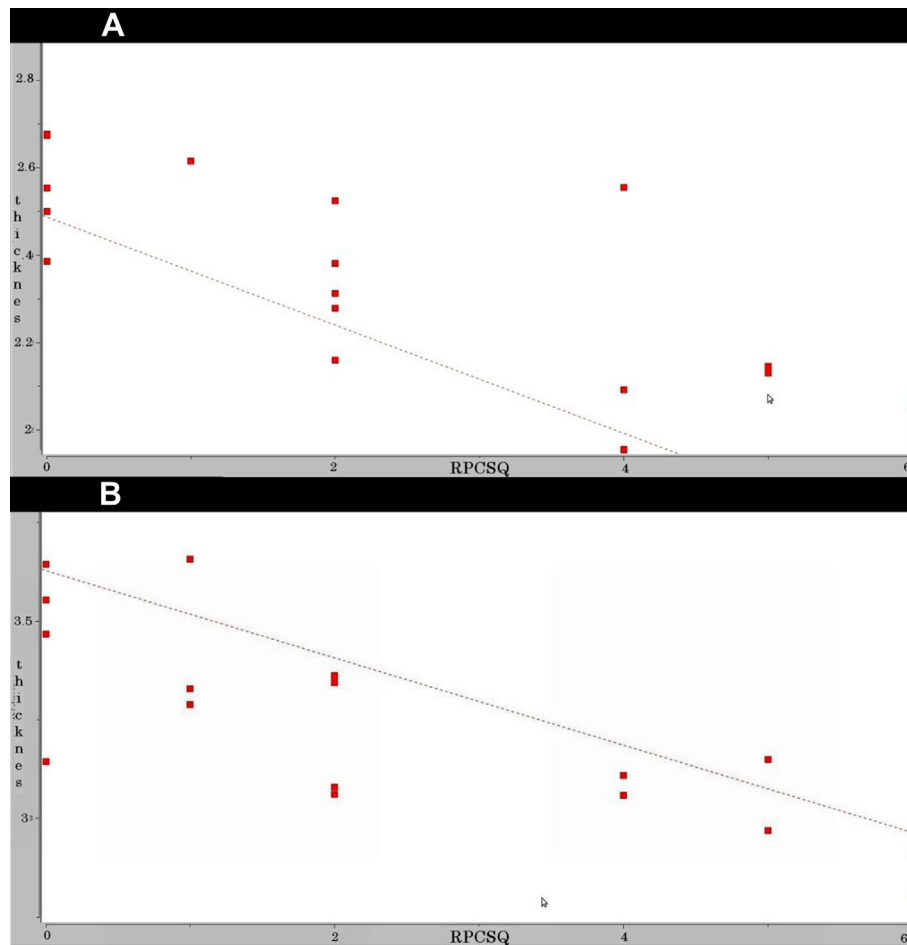
**Table 3 – Significant regions among traumatic patients with cognitive domains.**

Animal Naming Test (ANT)	Token Test (TT)
Left hemisphere Thickness, FDR – 0.15 Inferior parietal Superior parietal Precentral Monte Carlo Z simulation – 0.01, abs Inferior parietal p-0.010, CI-0.008–0.011	Right hemisphere thickness, FDR – 0.15 Inferior parietal
FDR – false discovery rate, CI – confident interval, abs – absolute value.	

regions in left ( $r_s -0.728$ ,  $p < 0.001$ ) and three regions in right hemisphere ( $r_s -0.625$ ,  $p < 0.006$ ) (Table 2). Our findings were generally consistent with findings with previous neuroimaging studies with traumatic brain injury.<sup>4,6</sup> After injury the cascade of neurobiological events that lead to changes in brain parenchyma level among susceptible individuals may be fastened.

There are no significant clusters on comparing traumatic with non-traumatic persons using FDR 0.15. Our data had 13 mild and 9 moderate TBI patients, on comparing these groups using FDR 0.15 no significant clusters were present. Probably the majority of patients were evaluated with  $\leq 13$  weeks during which no much brain measures changes can be appreciated. Previous studies have done volumetric analysis with mean duration of 10.6 months<sup>6</sup> showed significant brain measure thinning among traumatic group. Following mild to moderate injury significant brain volumetric changes occur over long time, and can also depend on individual differences such as genetic polymorphism and factors governing resiliency.

The typical neurobiological profile of head injury follows a cascade of cellular and sub cellular events. Brain structural disintegrity and neurotransmitter dysfunction occurs over variable period of time. Certain brain regions like frontal lobe and deeper midline structures are vulnerable. Disruption of these complex circuits in brain can make apparent problems like cognitive and functional impairment.<sup>15</sup> One significant cluster in inferior parietal was found on comparing the cognitive domain of ANT and TT among traumatic group using FDR 0.15 with weak correlation.



**Fig. 2 – Uncorrected clusters (probability of 0.01) between traumatic patients gray matter thickness with concussion symptoms. X-axis Rivermade post concussion symptoms questionnaires scores, Y-axis gray matter thickness. A-left hemisphere, B-right hemisphere.**

Inferior parietal lobule with its complex interconnection enables grammatically correct spoken language to analyze for meaning and perform it.<sup>16</sup> Patients with right hemisphere lesions have significantly poorer scores than controls in few parts of TT.<sup>17</sup> The TT measures more complex language abilities in addition to comprehension.<sup>18</sup>

Interesting findings from our data showed that as the RPCSQ scores increases among the traumatic group the trend of decrease in thickness (uncorrected) is noted in both right and left hemisphere (Fig. 2).

## 5. Limitations

This is a cross sectional study, where imaging is taken at one point time. The duration of imaging is 6–24 weeks with mean duration of 13 weeks, where the time point for significant brain measure changes is too less as compared with previous studies in the literature. The longitudinal studies with two points scan of at least three months interval will be more effective for volumetric changes. The FDR values taken from 0.05 to 0.15, where 0.05 FDR did not show any significant cluster for cognitive domains. So 0.15 was expected false positives for multiple cluster corrections in psychological tests. The study sample size is small, limited in its generalization. It is likely that other brain regions and variables may have survived FDR correction if the sample size was larger. We cannot be certain without a doubt that the reported brain measure changes are due to the TBI, secondary injury or other mechanism.

## 6. Conclusion

There is limited information on brain volumetric changes during early post-injury. Our results suggest the significant brain volumetric changes with age can start early after injury, but not as significant as compared with age and gender matched controls, and few cognitive domains can be weakly correlated with volumetric changes during this period. The longitudinal studies are required to understand the neurobiology of these deficit correlations with brain volumetric changes over time.

## Conflicts of interest

All authors have none to declare.

## Acknowledgment

We gratefully thank Department of science and technology (DST) for their financial support.

We thank Dr Akhil Deepika Kumarsamy, M.B.B.S (PhD), department of Neurosurgery for her support in data collection, Cathlyn Niranjana Bennett MSc (PhD), department of Clinical

psychology for her support in psychology discussion, Vasuki Prathyusha MSc (PhD), department of Biostatistics for her support in statistics discussion.

## REFERENCES

- Gururaj G. Road Safety in India: A Framework for Action, National Institute of Mental Health and Neurosciences, Implementing Road Safety in India, Report Final. 7. [www.nimhans.kar.nic.in/epidemiology/bisp/rsi2011.pdf](http://www.nimhans.kar.nic.in/epidemiology/bisp/rsi2011.pdf).
- Podell K, Gifford K, Bougakov D, Goldberg E. Neuropsychological assessment in traumatic brain injury. *Psychiatr Clin North Am.* 2010;33:855–876.
- Crippen David W. Head Trauma Treatment & Management. <http://emedicine.medscape.com/article/433855-treatment>. Accessed 3.07.12.
- Quantitative magnetic resonance imaging in traumatic brain injury Bigler, ed. *J Head Trauma Rehabil.* 2001;16:117–134.
- Hudaka Anne, Warnerb Matthew, Marquez de la Platac Carlos, Mooreb Carol, Harperb Caryn, Diaz-Arrastia Ramon. Brain morphometry changes and depressive symptoms after traumatic brain injury. *Psychiatry Res.* 2011;191:160–165.
- Gale SD, Baxter L, Roundy N, Johnson SC. Traumatic brain injury and grey matter concentration: a preliminary voxel based morphometry study. *J Neurol Neurosurg Psychiatry.* 2005;76:984–988.
- FreeSurferWiki. Available at: <http://surfer.nmr.mgh.harvard.edu/fswiki>. Accessed 13.12.11.
- MacKenzie JD, Siddiqi F, Babb JS, et al. Brain atrophy in mild or moderate traumatic brain injury: a longitudinal quantitative analysis. *AJNR Am J Neuroradiol.* 2002;23:1509–1515.
- Rao SL, Subbakrishna DK, Gopukumar K. NIMHANS Neuropsychology Battery-2004 Manual. 1st ed. Bangalore: National institute of Mental Health and Neurosciences; 2004.
- Shukla D, Devi BI, Agrawal A. Outcome measures for traumatic brain injury. *Clin Neurol Neurosurg.* 2011;113:435–441.
- Segonne F, Dale AM, Busa E, et al. A hybrid approach to the skull stripping problem in MRI. *NeuroImage.* 2004;22:1060–1075.
- Fischl B., Salat DH Busa E, Albert M, et al. Whole brain segmentation: automated labeling of neuroanatomical structures in the human brain. *Neuron.* 2002;33:341–355.
- Fischl B, Salat DH, van der Kouwe AJ, et al. Sequence-independent segmentation of magnetic resonance images. *NeuroImage.* 2004;23(suppl 1):S69–S84.
- Benjamini Y, Hochberg Y. On the adaptive control of the false discovery rate in multiple testing with independent statistics. *J Educ Behav Stat.* 2000;25:60–83.
- McAllister TW. Neurobiological consequences of traumatic brain injury. *Dialogues Clin Neurosci.* 2011;13:287–300.
- Joseph R. *The Knowing Hand: The Inferior Parietal Lobule & the Evolution of Reading, Writing, & Arithmetic, the Naked Neuron.* 2nd ed. New York: Plenum Press; 1996.
- Swisher LP, Sarno MT. Token test scores of three matched patient groups: left brain-damaged with aphasia; right brain-damaged without aphasia; non-brain-damaged. *Cortex.* 1969;5:264–273.
- Spreen O, Strauss E. *A Compendium of Neuropsychological Test. Administration, Norms, and Commentary.* 2nd ed. USA: Springer Science+Business Media, LLC; 2008:477.