


Available online at [www.sciencedirect.com](http://www.sciencedirect.com)

ScienceDirect

journal homepage: [www.elsevier.com/locate/ijnt](http://www.elsevier.com/locate/ijnt)

## Case Report

# Post-traumatic delayed intracerebral tension pneumatocele: A case report and review of literature

Pradipta Tripathy<sup>a,\*</sup>, S.S.G. Mohapatra<sup>b</sup>, Sahoo K. Ranjan<sup>c</sup>, G.S. Sarangi<sup>d</sup>, Sureswar Mohanty<sup>e</sup>

<sup>a</sup> Professor, Neurosurgery, Department of Neurosurgery, Institute of Medical Science (IMS) & SUM Hospital, Ghatikia, Bhubaneswar, Odisha 751003, India

<sup>b</sup> Associate Professor, Radiology, Department of Radiology, Institute of Medical Science (IMS) & SUM Hospital, Ghatikia, Bhubaneswar, Odisha 751003, India

<sup>c</sup> Assistant Professor, Radiology, Department of Radiology, Institute of Medical Science (IMS) & SUM Hospital, Ghatikia, Bhubaneswar, Odisha 751003, India

<sup>d</sup> Clinical Registrar, Neurosurgery, Department of Neurosurgery, Institute of Medical Science (IMS) & SUM Hospital, Ghatikia, Bhubaneswar, Odisha 751003, India

<sup>e</sup> Professor & Head, Neurosurgery, Department of Neurosurgery, Institute of Medical Science (IMS) & SUM Hospital, Ghatikia, Bhubaneswar, Odisha 751003, India

## ARTICLE INFO

## Article history:

Received 11 April 2013

Accepted 23 October 2013

Available online 9 November 2013

## Keywords:

Trauma

Intracerebral

Space occupying lesion

Delayed

Tension pneumatocele

## ABSTRACT

**Aim:** Delayed intracerebral tension pneumatocele is an uncommon cause of raised intracranial pressure (ICP) following trauma. However it can cause herniation syndrome due to sudden increase in ICP which requires emergent intervention. The present case reports a late onset intracerebral tension pneumatocele in an adult male.

**Subject:** A 35-year-old man was admitted to our emergency unit with alleged h/o head injury following a road traffic accident. The computerised tomographic (CT) scan of head showed left frontal sinus fracture, basi frontal contusion and minimal pneumocephalus. Conservative treatment was given and patient discharged on 10th day in normal neurological state. After almost a month he was re-admitted with h/o of repeated vomiting and altered sensorium. A repeat CT head at this time revealed a large left frontal intracerebral tension pneumatocele with mass effect. The patient was operated on urgently and the tense air was evacuated. Dural graft covered over the tear behind the left frontal sinus. During the postoperative period the patient's neurological status improved.

**Result:** Although traumatic pneumatocele generally develops during the early post-traumatic period, it can also develop to a tension pneumatocele resulting in mass effect in the late period leading to increased ICP and deterioration of conscious level.

Copyright © 2013, Neurotrauma Society of India. All rights reserved.

\* Corresponding author. Tel.: +91 (0)6742356292x351 (office), +91 (0)9439831761 (mobile); fax: +91 (0)674 2386393, +91 (0)674 2386223.

E-mail address: [pradipta\\_tripathy@yahoo.com](mailto:pradipta_tripathy@yahoo.com) (P. Tripathy).

0973-0508/\$ – see front matter Copyright © 2013, Neurotrauma Society of India. All rights reserved.

<http://dx.doi.org/10.1016/j.ijnt.2013.10.003>

## 1. Introduction

Pneumocephalus is usually defined as presence of air in the intracranial cavity. The term pneumocephalus was first coined by Wolff in 1914.<sup>1</sup> It is usually associated with basal skull fracture and dural tear after head and facial trauma. Clinically it manifests as cerebro spinal fluid (CSF) rhinorrhoea or otorrhoea, where as tension pneumatocele results from the entrapment of intracranial air due to a check valve system following head injury. Tension pneumatocele at times behaves like an intracranial space occupying lesion and threatens life.

## 2. Case history

A 35 years old male was admitted to neurosurgery ward with alleged h/o head injury following road traffic accident. There was no h/o loss of consciousness, vomiting or seizure but h/o bleeding from nose present. There was a sutured forehead laceration present on left side of 3 cm size. On examination, his vital signs stable, he was conscious, well oriented to time place and person. His Glasgow coma score (GCS) was 15/15, there were bilateral black eyes with periorbital swelling, so his vision and pupil could not be assessed. Except anosmia no other cranial nerves, motor and sensory deficit detected. A plain CT head was done which revealed fracture of left frontal bone involving the sinus with mild depression of posterior wall of the sinus, underlying basi frontal small contusions and patchy pneumocephalus [Fig. 1].

He was put on prophylactic antibiotic, anticonvulsant, antiemetics and analgesics with 100% oxygen by mask. For initial 24 h he was kept on IV fluids and strictly in supine posture. He was made to sit up after 48 h and checked for CSF rhinorrhea, which was not present. After 72 h a repeat CT head was done which revealed resorption of pneumocephalus and resolution of contusion. He was discharged on 10th day in a stable neurological condition.

A month later he was re-admitted in an altered sensorium with h/o repeated vomiting. On examination his vital signs were stable, he was drowsy, irritable and confused, his GCS was 13/15, pupil right side was normal, left moderately dilated and sluggishly reacting to light, no other deficit was detected. An urgent CT head [Fig. 2] was done which revealed a large left frontal intraparenchymal tension pneumatocele causing mass effect with intraventricular and subarachnoid pneumocephalus. He was operated in emergency. Frontal craniotomy, evacuation of tensed air, duroplasty and exteriorization of frontal sinus was done. Postoperatively he became fully conscious, oriented and there was no neurological deficit. A repeat CT head [Fig. 3] was done after 48 h, which showed complete resorption of left frontal lobe tension pneumatocele and subarachnoid and intraventricular air. Only mild oedema is noted in the frontal lobe and minimal extradural air. Patient was discharged on 10th day without any neurological deficit or CSF rhinorrhoea.

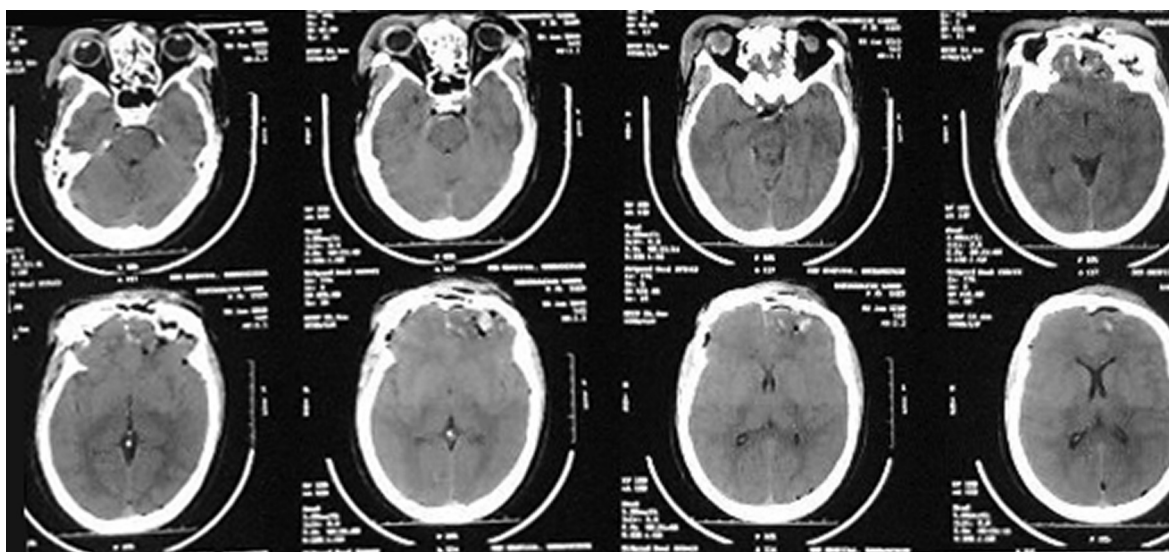
## 3. Discussion

Pneumocephalus, also known as intracranial aerocele or pneumatocele is defined as the presence of gas within any of the intracranial compartments (epidural, subdural, subarachnoid, intraventricular and intraparenchymal).<sup>2</sup>

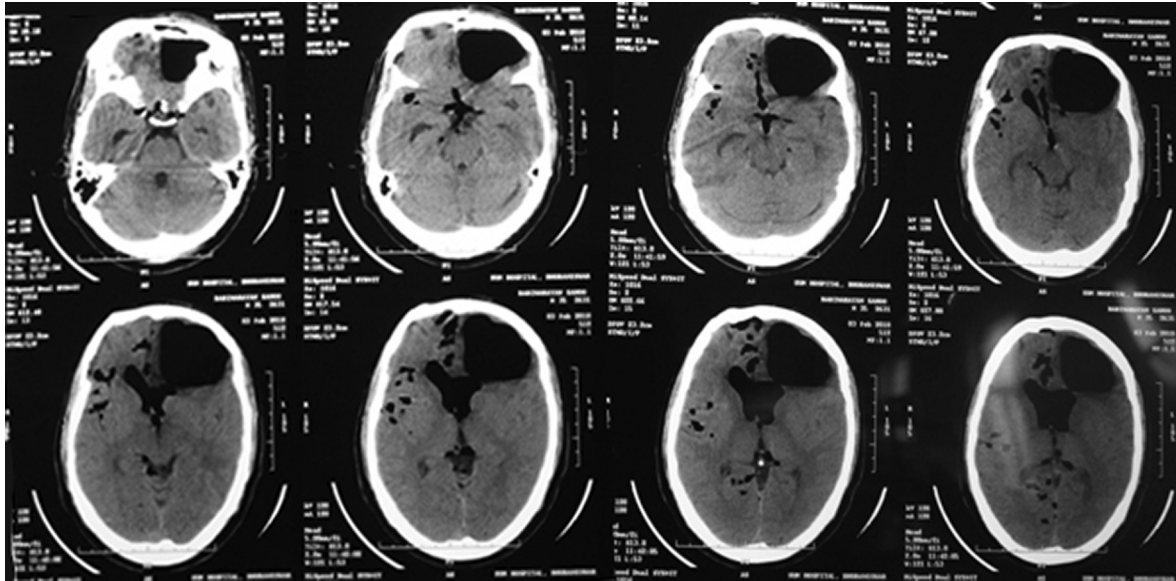
The pathophysiology of pneumocephalus usually involves one of the following mechanisms:

- i) Ball-valve mechanism in which there is a cranial defect and dural tear adjacent to a point where air is available i.e. para nasal sinus; air may be forced intracranially by coughing, sneezing or blowing etc.

The dural opening is sealed due to tamponade effect on pia-arachnoid by swollen brain, trapping the air intracranially (pneumocephalus). Repeated coughing and sneezing resulting in raised air pressure lead to larger accumulation of air in the



**Fig. 1** – A plain CT head showing fracture of left frontal bone involving the sinus with mild depression of posterior wall of the sinus, underlying basi frontal small contusions and patchy pneumocephalus.

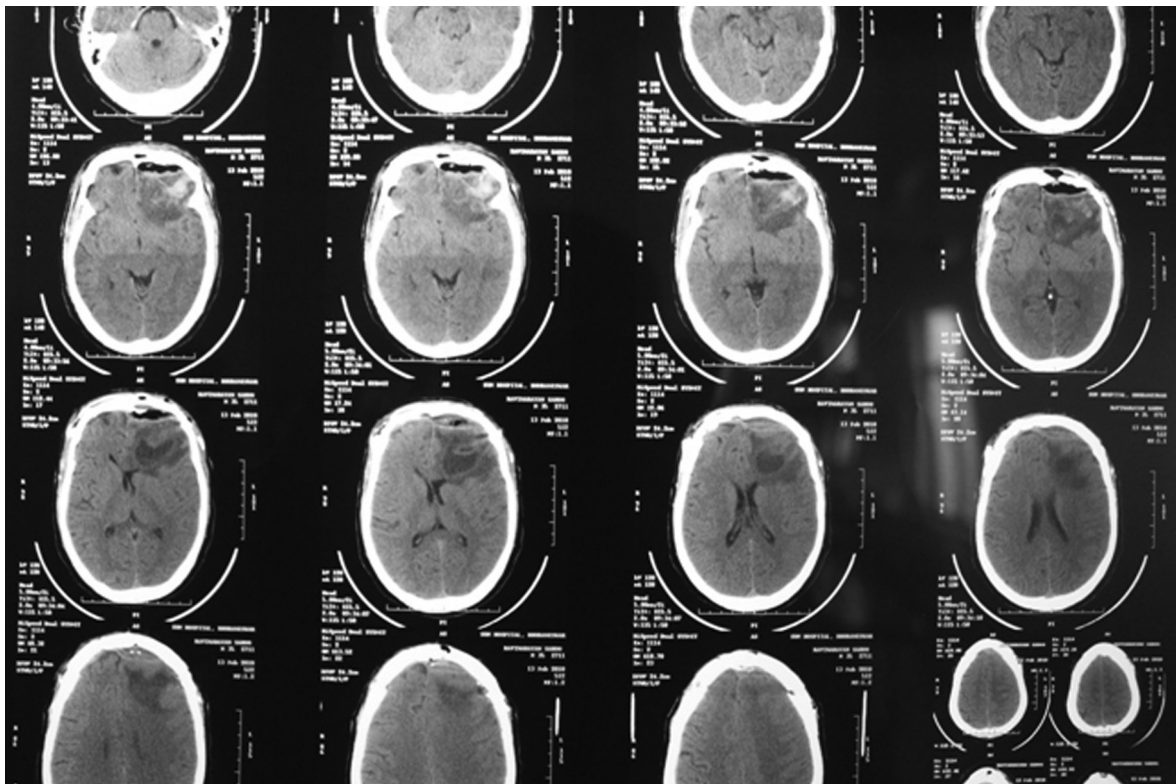


**Fig. 2 – A plain CT head showing a large left frontal intraparenchymal tension pneumatocele causing mass effect with intraventricular and subarachnoid pneumocephalus.**

subdural or within the brain itself giving rise to marked mass effect (tension pneumocephalus).

- ii) Inverted bottle neck mechanism in which air enters as fluid leaves the intracranial space.<sup>3,4</sup>

In tension pneumocephalus, air most frequently occupies the subdural area. However, air can also occupy the epidural, subarachnoid, intraparenchymal and intraventricular areas.<sup>3-6</sup> Gönül et al presented a case of tension pneumocephaly due to head trauma where they performed



**Fig. 3 – A plain CT head showing complete resorption of left frontal lobe tension pneumatocele and subarachnoid and intraventricular air.**



emergency decompressive surgery because of shift of intracranial midline structures. They noted that their case was interesting due to intraventricular tension pneumocephalus.<sup>6</sup> Ram et al presented a case of tension pneumocephaly in the posterior fossa region with CSF leakage at the suture line developing at the tenth day of a posterior fossa operation.<sup>7</sup> In the present case, initial pneumocephalus following trauma almost resolved and a tension pneumatocele developed almost a month after trauma. He did not have CSF rhinorrhoea although there was h/o bleeding from nose after trauma.

Gore et al mentioned the use of normobaric oxygen in high flow as a treatment protocol for simple pneumocephalus, which enhances the rate of absorption of pneumocephalus.<sup>8</sup> In our case patient's initial simple pneumocephalus disappeared following oxygen therapy.

Browning et al pointed out that intracranial air is frequently present after craniotomy, but it is normally absorbed in three to four weeks. The presence of pneumocephalus on a delayed postoperative CT scan should raise the possibility of a CSF fistula, or infection with a gas-forming organism. Many CSF fistulae require surgical closure in order to prevent potentially life-threatening central nervous system infections and tension pneumocephalus.<sup>9</sup>

Huang et al presented a case who had right traumatic frontal intracerebral haemorrhage and frontal bone fractures. Tension pneumocephalus was diagnosed by CT scan and plain skull X-rays. The fistulous tract of the ethmoid sinus was investigated by radioisotope albumin cisternography. This pneumatocele was unroofed and the fistula was tamponaded by pericranial muscles and the layers were sealed by fibrin glue. They concluded that, as a surgical emergency, tension pneumocephalus can be successfully treated only by early diagnosis and early treatment.<sup>4</sup>

To conclude long term observation of patients with simple pneumocephalus following trauma is beneficial as there is an expected risk of developing delayed tension pneumocephalus

which may manifest with raised ICP. Emergency intervention in these situations can be life saving.

---

### Conflicts of interest

All authors have none to declare.

---

### REFERENCES

1. Wolff E. Luftansammlung im rechten Seitenventrikel des Gehirns (Pneumocephalus). *Münch Med Wochenschr.* 1914;61:899.
2. Markham JW. The clinical features of pneumocephalus based upon a survey of 284 cases with report of 11 additional cases. *Acta Neurochir (Wien).* 1967;16:1–78.
3. Nazir SS, Wani MA, Kirmani AR. Post-traumatic subdural with intraventricular pneumatocele: a case report and review of literature. *JK Pract.* 2004;11(1):50–53.
4. Huang CF, Chou TY, Chang CK. Traumatic tension pneumocephalus—intracerebral pneumatocele: a case report. *Gaoxiong Yi Xue Ke Xue Za Zhi.* 1992;8:113–116.
5. Kon T, Hondo H, Kono M, Kasahara K. Severe tension pneumocephalus caused by opening of the frontal sinus by head injury 7 years after initial craniotomy; case report. *Neurol Med Chir (Tokyo).* 2003;43:242–245.
6. Gönül E, İzci A, Sali A, Baysefer A, Timurkaynak E. Subdural and intraventricular traumatic pneumocephalus: case report. *Minim Invasive Neurosurg.* 2000;43:98–101.
7. Ram Z, Knoller N, Findler G, Sahar A. Delayed intraventricular tension pneumocephalus complicating posterior fossa surgery for cerebellar medulloblastoma. *Child Nerv Syst.* 1992;8:351–353.
8. Gore PA, Maan H, Chang S, Pitt AM, Spetzler RF, Nakaji P. Normobaric oxygen therapy strategies in the treatment of postcraniotomy pneumocephalus. *J Neurosurg.* 2008;108:926–929.
9. Browning CJ, Harland SP, Burnet NG. Gas in the cranium: an unusual case of delayed pneumocephalus following craniotomy. *Clin Oncol (R Coll Radiol).* 2000;12:118–120.