


Available online at [www.sciencedirect.com](http://www.sciencedirect.com)

SciVerse ScienceDirect

journal homepage: [www.elsevier.com/locate/ijnt](http://www.elsevier.com/locate/ijnt)

## Case Report

# Concurrent supra and infra-tentorial traumatic parenchymal hematomas: Which one needs to be evacuated first?

Amit Agrawal<sup>a,\*</sup>, Surya Pratap Singh<sup>b</sup><sup>a</sup> Professor, Department of Neurosurgery, Narayana Medical College Hospital, Chinthareddypalem, Nellore 524003, Andhra Pradesh, India<sup>b</sup> Resident, Department of Neurosurgery, Narayana Medical College Hospital, Chinthareddypalem, Nellore 524003, Andhra Pradesh, India

## ARTICLE INFO

## Article history:

Received 23 February 2013

Accepted 12 May 2013

Available online 28 May 2013

## Keywords:

Cerebellar hematoma

Delayed hematoma

Intracerebral hematoma

Delayed traumatic intracerebellar hematoma

Cerebral contusion

## ABSTRACT

Traumatic intra-cerebellar hematoma although uncommon, yet increasing recognized lesions accounting for 6–0.82% of the total hematomas. We discuss a case of 19-year-old male multiple simultaneous traumatic supratentorial and infra-tentorial hemorrhages. In present case presence of significant size hematomas in both supra and infra-tentorial compartment posed a difficult challenge as which one needs to be evacuated first? This was a concern in present case as evacuation of the infra-tentorial hematoma can lead to downward herniation and evacuation of the supratentorial hematoma can lead to upward herniation. The difficulties and approach for an uncommon case of delayed and multiple traumatic supra and infra-tentorial hematomas are discussed.

Copyright © 2013, Neurotrauma Society of India. All rights reserved.

## 1. Introduction

Traumatic intra-cerebellar hematoma although uncommon, yet increasing recognized lesions accounting for 6–0.82% of the total hematomas.<sup>1–6</sup> Multiple simultaneous traumatic supratentorial and infra-tentorial hemorrhages are very uncommon.<sup>5,6</sup> We discuss the difficulties and approach for an uncommon case of delayed and multiple traumatic supra and infra-tentorial hematomas in a young male.

## 2. Case report

19-year-old male patient presented with 4 h after the road traffic accident, while he was driving the motor cycle and collided with a trolley and crashed into the road divider. He was in altered sensorium since then. He had multiple episodes of vomiting and left ear bleed. At the time of presentation he was in altered sensorium (GCS-E2V2M5), pupils were bilateral equal and reacting. He was moving all four limbs equally. His general and systemic examination was unremarkable.

\* Corresponding author. Tel.: +91 8096410032 (mobile).

E-mail addresses: [dramitagrawal@gmail.com](mailto:dramitagrawal@gmail.com), [dramit\\_in@yahoo.com](mailto:dramit_in@yahoo.com) (A. Agrawal).

0973-0508/\$ – see front matter Copyright © 2013, Neurotrauma Society of India. All rights reserved.

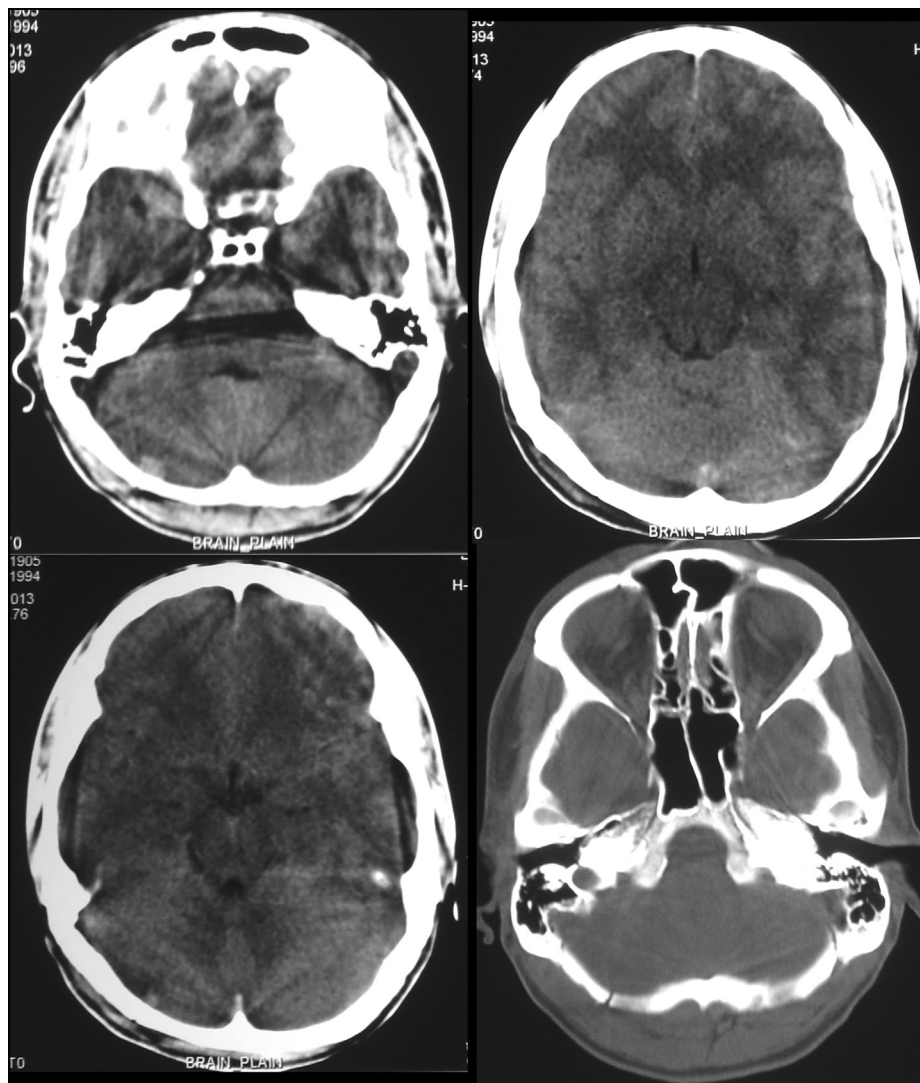
<http://dx.doi.org/10.1016/j.ijnt.2013.05.005>

The patient underwent emergency CT scan brain plain (5 h post injury) and it showed mild diffuse cerebral edema, right occipital bone fracture with small underlying cerebellar contusion and patchy appearance of the left frontal lobe (Fig. 1). The patient was admitted to intensive care unit and was started on anti-edema measures and anti-epileptics. Although his GCS was same but in view of doubtful patchy lesions a repeat elective CT scan was performed in the morning (after 18 h post-injury) and it showed extensive multiple hemorrhagic contusion involving left frontal and temporal lobe, right cerebellar hemisphere with significant mass effect and midline shift (Fig. 2). The patient was taken for emergency evacuation of both supra and infra-tentorial hematomas. While the patient was undergoing preparation for surgery both pupils became mid-dilated and mildly reactive to the light. First he underwent evacuation of right paramedian sub-occipital craniectomy and evacuation of cerebellar hematoma. It was followed by left fronto-temporal craniotomy and evacuation of frontal and temporal intra-cerebral hematomas followed by a lax duraplasty. He was kept on elective

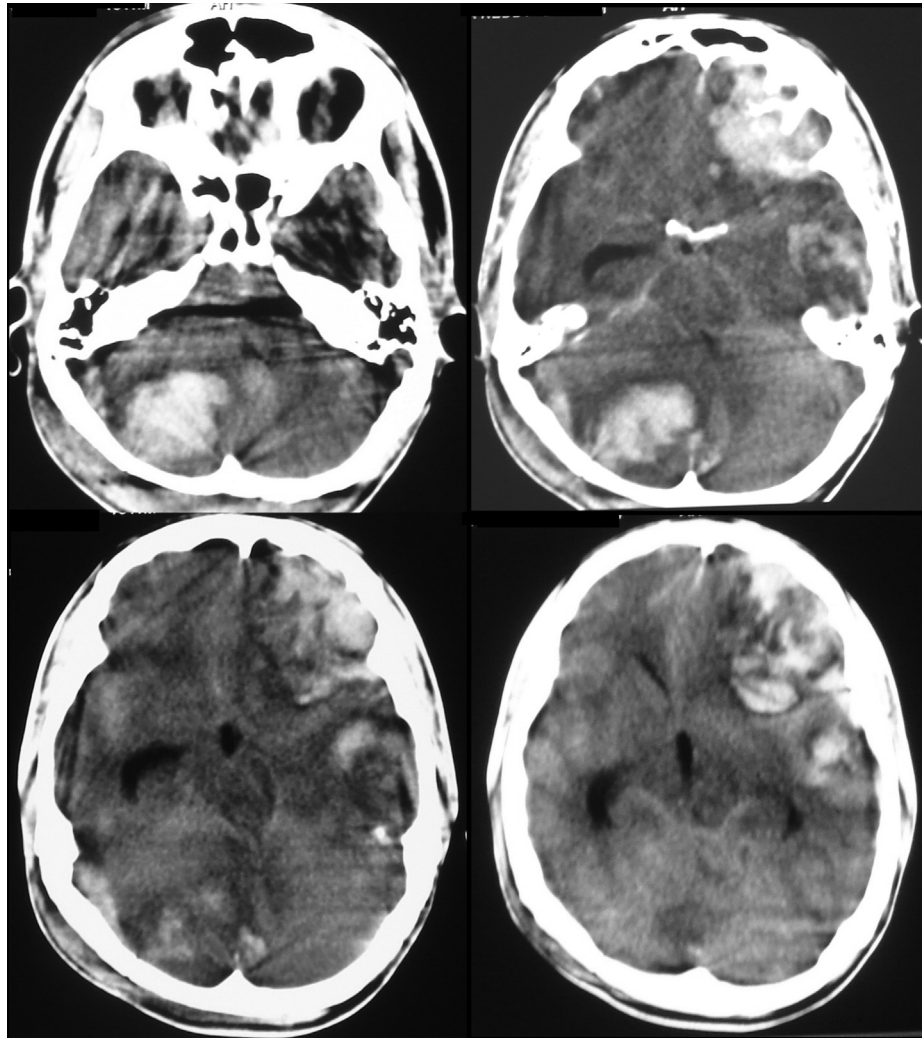
ventilation, tracheostomy was performed on 3rd day and he could be weaned off from ventilator 10-day post surgery. He made gradual recovery in his neurological status, he was localizing to pain, opening eyes to call with mild right upper and lower limb weakness. A follow up CT scan total resolution of cerebellar and frontal hematomas and resolving temporal hematoma with reduction in mass effect and midline shift (Fig. 3).

### 3. Discussion

With the increasing availability of the CT scan, delayed traumatic intracerebral hematoma (DTICH) diagnosed only sporadically in the past is now a well-established clinical entity.<sup>1,7-14</sup> In patients with delayed traumatic cerebellar hematomas few risk factors have been identified and include scalp contusion or laceration over the occiput, a suture line separation or fracture line traversing the lateral sinus or extending through the foramen magnum,<sup>2,5,15</sup> when a



**Fig. 1** – CT scan brain 4 h after injury showing only mild cerebral edema, small right cerebellar contusion, patchy left frontal basal contusion and right occipital bone linear fracture.

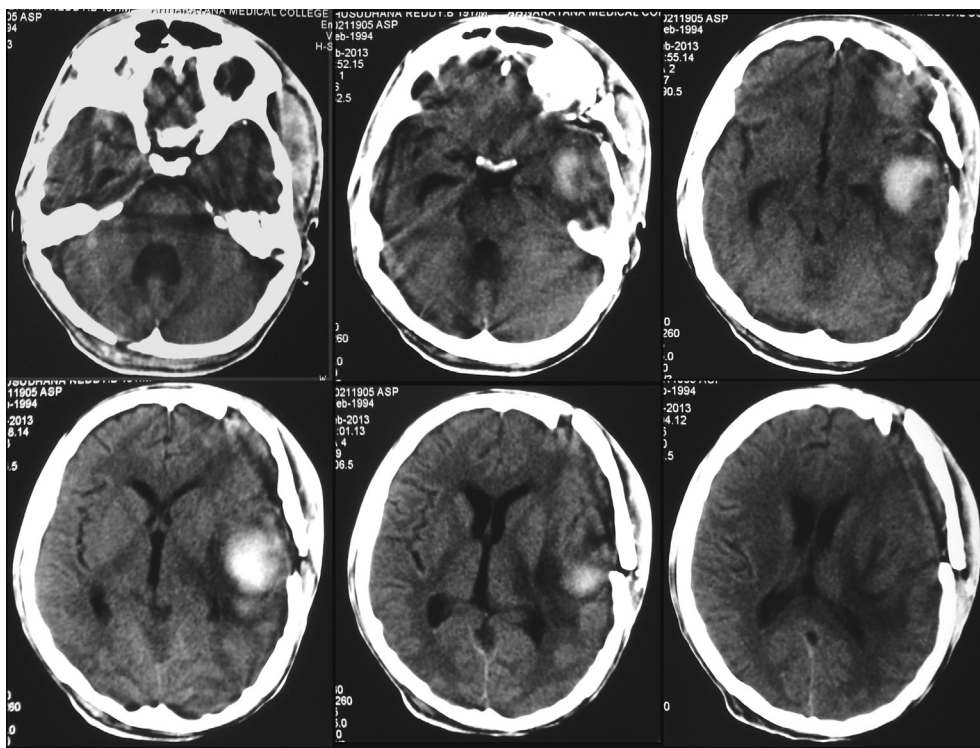


**Fig. 2 – CT scan 18 h after post injury showing extensive contusion involving right cerebellar hemisphere, left frontal and temporal lobe with significant mass effect and midline shift including distortion of 4th ventricle and brain stem (because of cerebellar contusion).**

patient's clinical condition fails to improve or deteriorates after the appropriate therapeutic measures,<sup>15</sup> elderly patients,<sup>16</sup> and injury had been sustained with the head in motion.<sup>9,11</sup> These lesions develop several hours to days after trauma and can be demonstrated and followed up by serial CT scans.<sup>10,11,16,17</sup> This dynamic and expansile nature of cerebral contusions can lead to rise in intracranial pressure and delayed neurological deterioration.<sup>18</sup> The mechanism for the expansion of hematoma are not well understood and many explanations have been proposed including latent coagulopathy leading to continued or delayed bleeding of microvessels and delayed formation of petechial hemorrhages which then coalesce to produce hemorrhagic progression.<sup>16,19–21</sup> Expanding lesions either in the supratentorial compartment or infra-tentorial compartment can cause compression of cerebral and cerebellar hemispheres and subsequent distortion (including downward or upward shift brain stem structures) of adjacent structures resulting in spectrum of clinical manifestations (tentorial herniation, brain stem ischemia, tonsillar herniation, third nerve compression and so on).<sup>22–24</sup>

Prompt evacuation of the large and expanding lesions with poor Glasgow coma scale has been associated with favorable outcome.<sup>1,3–6,21,25–27</sup> In present case the presence of significant size hematomas in both supra and infra-tentorial compartment posed a difficult challenge as all the hematomas were needed evacuation but the difficult in making a decision that which one needed to be evacuated first? This was a concern in present case as evacuation of the infra-tentorial hematoma can lead to downward herniation and evacuation of the supratentorial hematoma can lead to upward herniation with its sequelae.<sup>28–30</sup> It has been well recognized that acute pupillary dilation in a traumatic brain injury patient is usually due to uncal herniation causing mechanical compression of the 3rd cranial nerve and subsequent brain stem compromise.<sup>31</sup> However in alternative hypotheses it has been postulated that a decrease in brain stem blood flow also can cause of mydriasis and can be rapidly restored once the compression from the brain stem is removed.<sup>31</sup> Pupillary size and reaction to light helped us to make a decision. As the pupils were mid-dilated and sluggishly reacting to light it was





**Fig. 3 – Follow up CT scan at 2 weeks showing good resolution of cerebellar and frontal hematomas and resolving left temporal lobe hematoma, please note significant resolution of the mass effect and midline shift.**

presumed that probably it was due to brain stem compression and ischemia. Once the posterior fossa hematoma was evacuated pupils became normal in size and were reacting to light even before the supratentorial hematoma could be evacuated.

In summary, there may be delayed development of concurrent supra and infra-tentorial traumatic parenchymal hematomas leading to neurological deterioration of the patient. Making a decision which hematoma needs to be evacuated can be difficult. In these cases imaging findings and clinical picture of the patient can help to make a decision that which one needs to be evacuated first? As a rule of thumb, unless the supratentorial is very large and toward the midline, infratentorial hematoma needs to be evacuated first, if the lesions are on either side of the tentorium (supra and infratentorial compartment) a combined approach for evacuation may be performed. Also as long as both the hematomas are evacuated in the same general anesthesia patient is safe (even when supratentorial hematoma is evacuated first because of the sheer larger size).

### Conflicts of interest

All authors have none to declare.

### REFERENCES

- Pozzati E, Grossi C, Padovani R. Traumatic intracerebellar hematomas. *J Neurosurg.* 1982;56:691–694.
- Tsai FY, Teal JS, Itabashi HH, Huprich JE, Hieshima GB, Segall HD. Computed tomography of posterior fossa trauma. *J Comput Assist Tomogr.* 1980;4:291–305.
- Cassinari V, Dorizzi A, Pauli P, Monolo L. Expansive traumatic lesions of the posterior cranial fossa. On 4 cases of cerebellar contusion and laceration. *Minerva Neurochir.* 1967;11:230–239.
- Papadakis N, Safran A, Ramirez L, Sujatanond M, Mark VH. Traumatic cerebellar hematoma without subdural hematoma. *J Am Med Assoc.* 1976;235:530–531.
- Schneider RC, Lemmen LJ, Bagchi BK. The syndrome of traumatic intracerebellar hematoma with contrecoup supratentorial complications. *J Neurotrauma.* 1953;10:122.
- Wright RL. Traumatic hematomas of the posterior cranial fossa. *J Neurosurg.* 1966;25:402–409.
- Baratham G, Dennyson WG. Delayed traumatic intracerebral haemorrhage. *J Neurol Neurosurg Psychiatr.* 1972;35:698–706.
- Jamieson KG, Yelland JD. Traumatic intracerebral hematoma. Report of 63 surgically treated cases. *J Neurosurg.* 1972;37:528–532.
- Diaz FG, Yock DH, Larson D, Rockswold GL. Early diagnosis of delayed posttraumatic intracerebral hematomas. *J Neurosurg.* 1979;50:217–223.
- Kaufman HH, Moake JL, Olson JD, et al. Delayed and recurrent intracranial hematomas related to disseminated intravascular clotting and fibrinolysis in head injury. *Neurosurgery.* 1980;7:445–449.
- Brown FD, Mullan S, Duda EE. Delayed traumatic intracerebral hematomas. Report of three cases. *J Neurosurg.* 1978;48:1019–1022.
- Dirim BV, Orük C, Erdoğan N, Gelal F, Uluç E. Traumatic posterior fossa hematomas. *Diagn Interv Radiol.* 2005;11:14–18.
- Roberson FC, Kishore PR, Miller JD, Lipper MH, Becker DP. The value of serial computerized tomography in the management of severe head injury. *Surg Neurol.* 1979;12:161–167.

14. Sweet RC, Miller JD, Lipper M, Kishore PR, Becker DP. Significance of bilateral abnormalities on the CT scan in patients with severe head injury. *Neurosurgery*. 1978;3:16–21.
15. Koulouris S, Rizzoli HV. Delayed traumatic intracerebral hematoma after compound depressed skull fracture: case report. *Neurosurgery*. 1981;8:223–225.
16. Young HA, Gleave JR, Schmidek HH, Gregory S. Delayed traumatic intracerebral hematoma: report of 15 cases operatively treated. *Neurosurgery*. 1984;14:22–25.
17. Nagata K, Ishikawa T, Shigeno T, Kawahara N, Asano T, Takakura K. Delayed traumatic intracerebellar hematoma: correlation between the location of the hematoma and the pre-existing cerebellar contusion—case report. *Neurol Med Chir*. 1991;31:792–796.
18. Ragaišis V. Brain contusion: morphology, pathogenesis, and treatment. *Medicina*. 2002;38:243–249.
19. Kurland D, Hong C, Aarabi B, Gerzanich V, Simard JM. Hemorrhagic progression of a contusion after traumatic brain injury: a review. *J Neurotrauma*. 2012;29:19–31.
20. Van Beek JGM, Mushkudiani NA, Steyerberg EW, et al. Prognostic value of admission laboratory parameters in traumatic brain injury: results from the IMPACT study. *J Neurotrauma*. 2007;24:315–328.
21. d'Avella D, Servadei F, Scerrati M, et al. Traumatic intracerebellar hemorrhage: clinicoradiological analysis of 81 patients. *Neurosurgery*. 2002;50:16–25. discussion 25–17.
22. Kernohan JW, Woltman HW. Incisura of the crus due to contralateral brain tumor. *Arch Neurol Psych*. 1929;21:274.
23. Bhatoo HS, Sen K, Singh P, Mukherji J. MRI demonstration of Kernohan's notch. *Indian J Neuro*. 2005;2:55–56.
24. Meyer A. Herniation of the brain. *Arch Neurol Psych*. 1920;4:387.
25. Brillman J. Acute hydrocephalus and death one month after non-surgical treatment for acute cerebellar hemorrhage. Case report. *J Neurosurg*. 1979;50:374–376.
26. Ott KH, Kase CS, Ojemann RG, Mohr JP. Cerebellar hemorrhage: diagnosis and treatment. A review of 56 cases. *Arch Neurol*. 1974;31:160–167.
27. Sokol JH, Rowed DW. Traumatic intracerebellar haematoma. *Surg Neurol*. 1978;10:340–341.
28. Cuneo RA, Caronna JJ, Pitts L, Townsend J, Winestock DP. Upward transtentorial herniation: seven cases and a literature review. *Arch Neurol*. 1979;36:618–623.
29. Prabhakar H, Umesh G, Chouhan RS, Bithal PK. Reverse brain herniation during posterior fossa surgery. *Minerva Neurochir*. 2003;15:267–269.
30. Gurajala I, Brahmadas V, Rajesh A, Ramachandran G, Purohit AK. Reverse brain herniation following ventriculoperitoneal shunt. *Indian J Anaesth*. 2012;56:585–587.
31. Ritter AM, Muizelaar JP, Barnes T, et al. Brain stem blood flow, pupillary response, and outcome in patients with severe head injuries. *Neurosurgery*. 1999;44:941–948.