




ELSEVIER

Available online at www.sciencedirect.com

SciVerse ScienceDirect

journal homepage: www.elsevier.com/locate/ijnt

Case Report

Modified combined hairline and square scalp flap for evacuation of concurrent frontal contusion and parietal extradural hematoma

Amit Agrawal*

Professor of Neurosurgery, Department of Neurosurgery, Narayana Medical College Hospital, Chinthareddypalem, Nellore 524003, Andhra Pradesh, India

ARTICLE INFO

Article history:

Received 16 February 2013

Accepted 5 May 2013

Available online 28 May 2013

Keywords:

Scalp

Scalp incision

Scalp flap

Craniotomy

ABSTRACT

The proper planning of the initial scalp incision requires knowledge of superficial anatomy, the vascular supply awareness of functional considerations, extent of underlying pathology and thoughtful planning. In present case application of fundamental principles in the practice of plastic surgery i.e. modification of combined hairline and square scalp flap for evacuation of concurrent frontal contusion and parietal extradural hematoma was a simple and effective option to manage both the lesions simultaneously.

Copyright © 2013, Neurotrauma Society of India. All rights reserved.

1. Introduction

The proper planning of the initial scalp incision requires knowledge of superficial anatomy, the vascular supply awareness of functional considerations, extent of underlying pathology and thoughtful planning.^{1–3} Traditionally, the approach to the frontal region involves using the bicoronal or three-quarter Souttar incision. In present article we discuss modified combined hairline and square scalp flap for evacuation of concurrent frontal contusion and parietal extradural hematoma.

2. Case report

A 40-year-male presented with the history of road traffic accident hit by four wheeler 6 h back. He was in altered sensorium since then. He had two episodes of vomiting. There was no history of seizures, or ear, nasal and throat bleeding. His general and systemic examination was normal. Neurologically he was in altered sensorium (GCS-E2V2M5). Pupils were bilateral equal and reacting to light. He had paucity of movements on left upper and lower limbs. CT scan brain showed and right frontal hematoma with peri-lesional

* Tel.: +91 8096410032 (mobile).

E-mail addresses: dramitagrawal@gmail.com, dramit_in@yahoo.com.

0973-0508/\$ – see front matter Copyright © 2013, Neurotrauma Society of India. All rights reserved.

<http://dx.doi.org/10.1016/j.ijnt.2013.05.002>

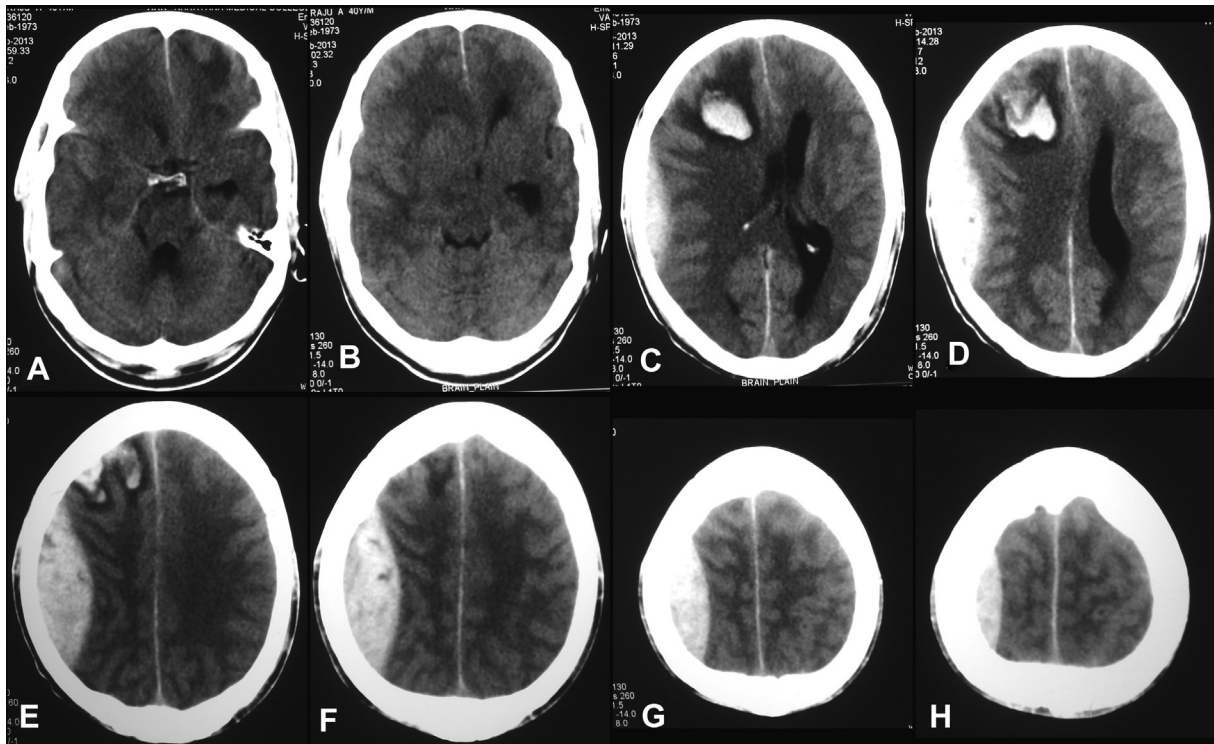


Fig. 1 – CT scan brain serial images showing the extent of frontal intracerebral and parietal extradural hematoma.

edema and mass effect and right parietal large extradural hematoma with mass effect and midline shift (Fig. 1). The patient was planned for emergency evacuation of frontal intracerebral and parietal extradural hematoma. The patient put in supine position and head turned to left side. A square shaped incision was marked for parietal hematoma and a hairline incision in frontal of coronal suture was marked to expose frontal hematoma (Fig. 2A). The anterior limb of the square flap and inferior limb of the hairline flap were combined and were based on superficial temporal artery.

An extensive bone exposure to the desired area could be achieved (Fig. 2B). A bone flap was planned keeping in mind that a trephine would had been enough to evacuate to frontal intracerebral hematoma and square bone flap wound had been needed to evacuate the parietal extradural hematoma (Fig. 3A). Extradural was exposed posteriorly and evacuated through square shaped exposure (Fig. 3B). Elliptical incision in dura was made along the antero-superior margin of the craniotomy (approximately 6 cm in front of the coronal suture) and though 5 mm corticectomy and at 1 cm depth

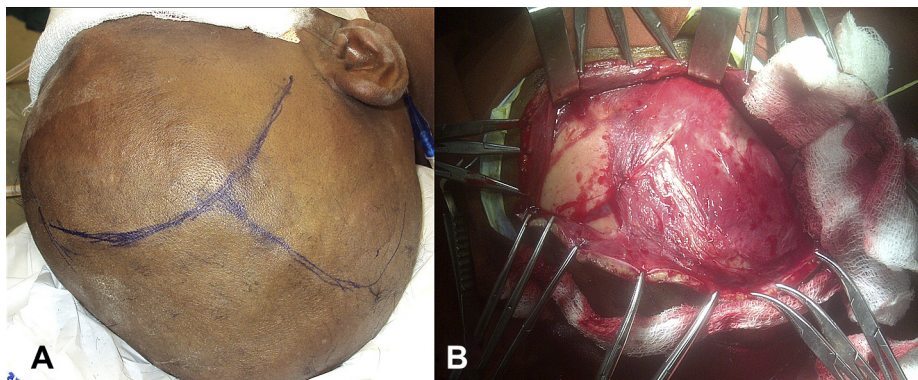


Fig. 2 – Outline of the scalp incision (A) and extent of bone exposure (B).

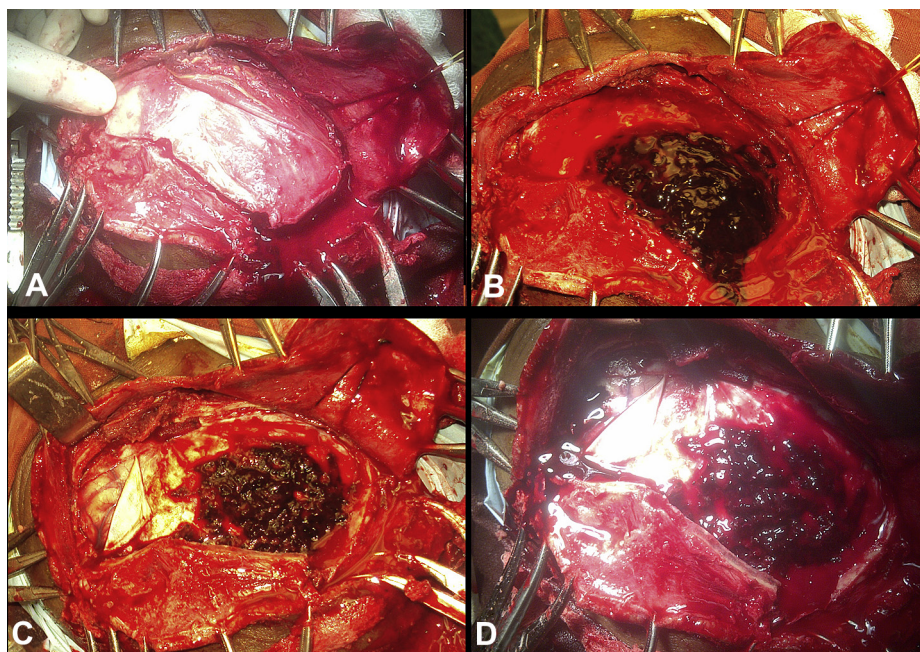


Fig. 3 – (A) Fronto-parietal bone flap, (B) exposure of extradural hematoma, (C) incision of the dura and (D) evacuation of intracerebral hematoma.

frontal intracerebral hematoma was evacuated (Fig. 3C and D). Dura was closed in a watertight manner. Dural hitches were applied and tied. Bone flap was replaced and secured. Scalp incision was closed in layers (Fig. 4). Post-operatively the patient was kept on elective ventilation and could be weaned off after 48 h. Follow up CT scan showed good evacuation of both hematomas (Fig. 5). Wound healed well at follow up (Fig. 6).

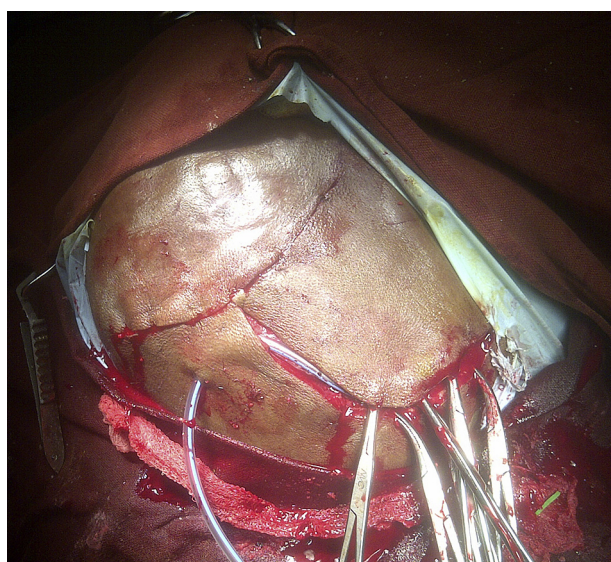


Fig. 4 – Approximation of the scalp edges.

3. Discussion

The main supplying arteries in the present scalp are (all paired) dorsal nasal, supratrochlear and supraorbital arteries (for forehead) frontal and parietal branches of the superficial temporal artery (the temporal region), posterior auricular vessels and occipital arteries supply.^{4–11} The relation between flaps and the anatomy of the cutaneous vessels has been well recognized.^{12–15} The operative scalp incision should be planned so as to optimize the exposure underlying pathology and to optimize the blood flow to the healing incision and to allow for alternate procedures.¹ Flaps may be raised in many region of the scalp and to achieve the goal a comprehensive knowledge of the anatomy of the scalp and calvaria including vascular supply is essential in planning scalp incisions.^{6,8,12,16,17} Proper design of local scalp flaps includes incorporation of major vascular pedicles within broadly based flaps⁶ and it has been recommended that flaps must be based on one or two vascular pedicles of the scalp to afford a large rotation angle.^{8,17} This knowledge of these basic principles was applied to modify and combine the two incisions in present for a luxurious exposure. Closure could be performed as per guidelines i.e. primary closure,⁶ approximation of the aponeurotic layer^{8,18} and closure without excessive tension.⁶ If possible a linear incision is preferred as a straight line incision provides rapid access, healing is more rapid and cranial nerve, and superficial temporal artery damage is minimized. However, in present case it was difficult for us to expose both the hematomas at a time by a linear incision. In present case application of fundamental principles in the practice of plastic surgery i.e. modification of combined hairline and square scalp flap for evacuation of

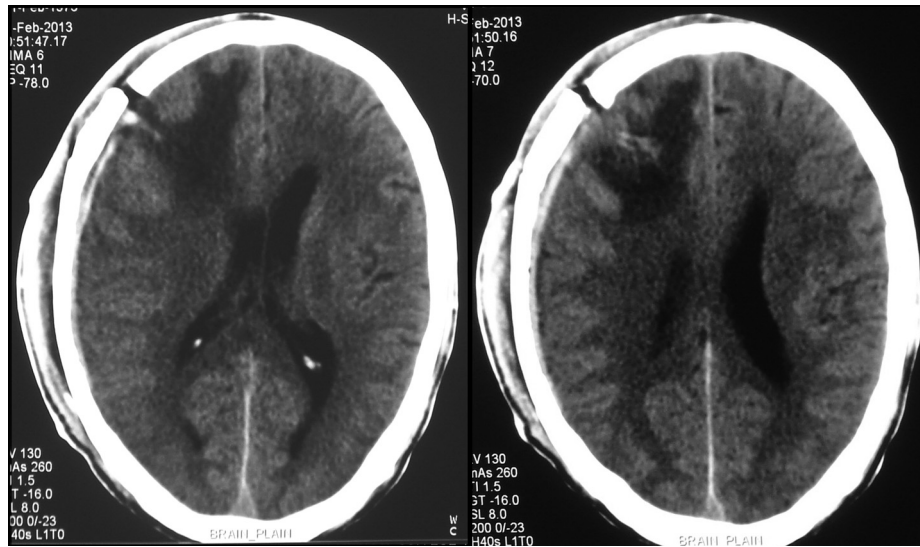


Fig. 5 – Follow up CT scan showing evacuation of ICH and EDH.

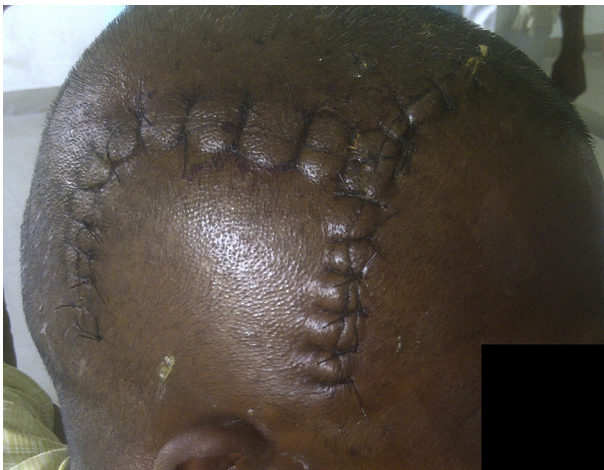

Fig. 6 – Good healing of scalp incision.

concurrent frontal contusion and parietal extradural hematoma was a simple and effective option to manage both the lesions simultaneously.

Conflicts of interest

The author has none to declare.

REFERENCES

- Schmidek HH, Sweet WH, Ratcheson RA. *Operative Neurosurgical Techniques: Indications, Methods, and Results*. New York: Grune & Stratton; 1988.
- Leshin B. *Proper Planning and Execution of Surgical Excisions. Cutaneous Surgery*. Philadelphia: Saunders; 1994:171–177.
- Frodel JL, Mabrie D. Optimal elective scalp incision design. *Otolaryngol Head Neck Surg*. 1999;121:374–377.
- Shumrick KA, Smith TL. The anatomic basis for the design of forehead flaps in nasal reconstruction. *Arch Otolaryngol Head Neck Surg*. 1992;118:373–379.
- Yoshioka N, Rhoton Jr AL. Vascular anatomy of the anteriorly based pericranial flap. *Neurosurgery*. 2005;57:11–16. discussion 11–16.
- Lin SJ, Hanasono MM, Skoracki RJ. Scalp and calvarial reconstruction. *Semin Plast Surg*. 2008;22(4):281–293.
- Knize DM. Limited incision foreheadplasty. *Plast Reconstr Surg*. 1999;103:271–284. discussion 285.
- Leedy JE, Janis JE, Rohrich RJ. Reconstruction of acquired scalp defects: an algorithmic approach. *Plast Reconstr Surg*. 2005;116:54e–72e.
- Orticochea M. Colgajos de revestimiento cutáneo del cráneo. In: Grabb W, Myers D, eds. *Colgajos Cutáneos Madrid*. Salvat; 1982:149–198.
- Hollinshead WH. *Anatomy for Surgeons: The Head and Neck*. Cassel; 1961.
- Williams PL. *Gray's Anatomy*. London: Churchill livingstone; 1995.
- Taylor G. *The Blood Supply of the Skin*. In: Grabb and Smith's *Plastic Surgery*. 5th ed. Philadelphia: Lippincott-Raven; 1997:47–59.
- Morain W, Ristic J, Manchot. *The Cutaneous Arteries of the Human Body*. New York: Springer Verlag; 1983.
- Spalteholz W. *Die Vertheilung der Blutgefässe in der Haut*; 1893.
- Salmon M, Taylor GI, Tempest MN. *Arteries of the Skin*. Churchill Livingstone; 1988.
- Newman MI, Hanasono MM, Disa JJ, Cordeiro PG, Mehrara BJ. Scalp reconstruction: a 15-year experience. *Ann Plast Surg*. 2004;52:501–506. discussion 506.
- Frodel JL, Ahlstrom K. Reconstruction of complex scalp defects: the "Banana Peel" revisited. *Arch Facial Plast Surg*. 2004;6:54–60.
- Onishi K, Maruyama Y, Hayashi A, Inami K. Repair of scalp defect using a superficial temporal fascia pedicle VY advancement scalp flap. *Br J Plast Surg*. 2005;58:676–680.