


Available online at [www.sciencedirect.com](http://www.sciencedirect.com)

SciVerse ScienceDirect

journal homepage: [www.elsevier.com/locate/ijnt](http://www.elsevier.com/locate/ijnt)

## Review Article

# Traumatic contre-coup bilateral intracerebellar hematoma: A case report and review of literature

Pradipta Tripathy<sup>a,\*</sup>, G.S. Sarangi<sup>b</sup>, S.S.G. Mohapatra<sup>c</sup>, Sureswar Mohanty<sup>d</sup>

<sup>a</sup> Professor, Department of Neurosurgery, Institute of Medical Science (IMS) & SUM Hospital, Sector – 8, Kalinga Nagar, Ghatikia, Bhubaneswar 751003, Odisha, India

<sup>b</sup> Clinical Registrar, Department of Neurosurgery, Institute of Medical Science (IMS) & SUM Hospital, Kalinga Nagar, Ghatikia, Bhubaneswar 751003, Odisha, India

<sup>c</sup> Associate Professor, Department of Radiology, Institute of Medical Science (IMS) & SUM Hospital, Kalinga Nagar, Ghatikia, Bhubaneswar 751003, Odisha, India

<sup>d</sup> Professor & Head, Department of Neurosurgery, Institute of Medical Science (IMS) & SUM Hospital, Kalinga Nagar, Ghatikia, Bhubaneswar 751003, Odisha, India

## ARTICLE INFO

## Article history:

Received 31 January 2013

Accepted 6 April 2013

Available online 12 April 2013

## Keywords:

Traumatic

Contrecoup

Bilateral

Intracerebellar

Hematoma

## 1. Introduction

Traumatic posterior fossa hematomas are mostly surface hematomas. Unilateral intracerebellar hematoma following trauma occurs due to direct occipital injury or as result of frontal impact (contre-coup). A case of contre-coup bilateral intracerebellar hematoma is being reported in an elderly patient following an impact injury on forehead.

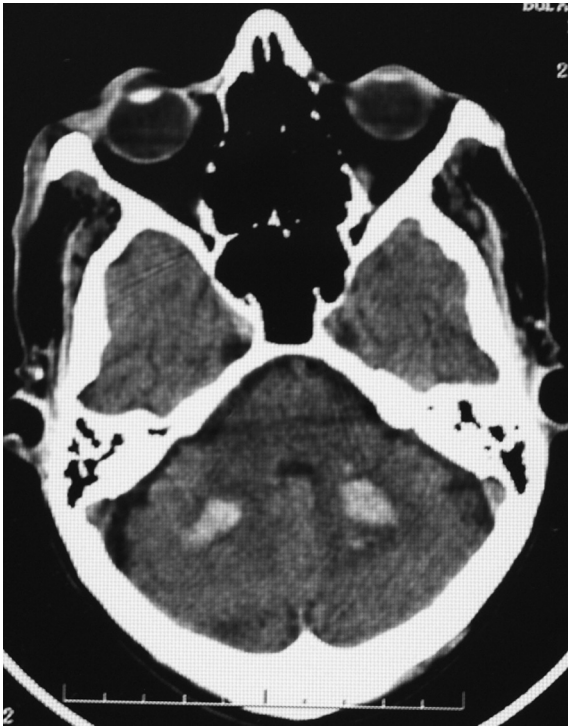
## 2. Case history

A 65-year-old male admitted to neurosurgery ward with history of head injury due to road traffic accident. He was walking on road and was hit by a motor-bike from back at around 4 P.M. Immediately he fell down on ground hitting his forehead. He had bruised over left forehead. There was transient loss of consciousness after which he regained full

\* Corresponding author. Tel.: +91 (0) 674 2356292x351 (O), +91 (0) 9439831761 (mobile); fax: +91 (0) 674 2386393, +91 (0) 674 2386223.  
E-mail address: [pradipta\\_tripathy@yahoo.com](mailto:pradipta_tripathy@yahoo.com) (P. Tripathy).

0973-0508/\$ – see front matter Copyright © 2013, Neurotrauma Society of India. All rights reserved.

<http://dx.doi.org/10.1016/j.ijnt.2013.04.004>



**Fig. 1 – Plain CT scan of head showing bilateral mirror image like intracerebellar hematomas perivermian area.**

consciousness. Except mild headache, he did not have any features of raised intracranial pressure.

On examination his general physical examinations were normal. He was normotensive. There were forehead bruises. On neurological examination he was conscious but confused. His GCS was 14/15 and pupils were of normal size reacting to light bilaterally. He had bilateral coarse tremors of hands and bilateral cerebellar ataxia.

CT scan of head revealed hematomas of size 1 × 1 inch in perivermian location in both cerebellar hemisphere (Fig. 1). No fracture of calvaria was reported.

Patient was managed conservatively with mannitol I.V 8 h for 3 days. He improved, become conscious, well oriented after 1 week. However he had persistent vertigo particularly while changing his posture and intentional tremors in hand. He was discharged from hospital on 10th day. After 3 months of follow up he was symptom free and repeat CT head this time revealed disappearance of bilateral cerebellar hematomas and cerebellar signs.

### 3. Discussion

Contre-coup posterior fossa hematoma is reported although they are rare. Usually the hematomas are unilateral extra or

subdural and SAH.<sup>1</sup> If in addition rotational or torsional injury is present patient may develop acute brain stem contusion or infarct along with the hematomas. These patients become unconscious from the beginning and prognosis is very poor irrespective of type of treatment.<sup>2</sup> CT scan of head is the best modalities of investigation to identify these radiological findings. Clinical presentation of the patient usually depends on site and size of the hematoma and associated mass effect. If the size of hematoma >3 cm, surgical intervention is indicated as life saving procedure.<sup>3</sup> The outcome of intracerebellar hematomas depends on various factors like at admission GCS, size of hematoma, associated lesions i.e SAH and intraventricular hemorrhage and time interval between initiation of treatment since the time of injury.<sup>3,4</sup> Results are good only in patients who are conscious or having good GCS score at the time of injury. Moderate to small size hematomas are best managed conservatively.<sup>4</sup>

Spontaneous cerebellar hematomas are usually seen in elderly hypertensives females<sup>4</sup> but traumatic cases are usually in young adult males which are mostly unilateral.<sup>5</sup> In our case the impact on forehead led to hematomas in both cerebellar hemispheres as contre-coup phenomena possibly due to high impact force.

### 4. Conclusion

Contre-coup bilateral intracerebellar hematoma is a rare occurrence not yet reported in the literature.

### Conflicts of interest

All authors have none to declare.

### REFERENCES

1. Pozzati E, Grossi C, Padovani R. Traumatic intracerebellar hematomas. *J Neurosurg.* 1982;56:691–694.
2. Hamasaki T, Yamaki T, Yoshino E, Higuchi T, Horikawa Y, Hirakawa K. Traumatic posterior fossa hematoma. *No To Shinkei.* 1987;39:1083–1090.
3. D'Avwlla D, Servadei F, Scerrati M, et al. Traumatic intracerebellar hemorrhage: clinico-radiological analysis of 81 patients. *Neurosurgery.* 2000;50(1):16–25.
4. Koziarski A, Frankiewicz E. Medical and surgical treatment of intracerebellar haematomas. *Acta Neurochir (Wien).* 1991;110:24–28.
5. Baldini M, Vivenza C, Princi L. Post traumatic intracerebellar hematoma. *Neurosurg Rev.* 1979;2:113–116.