


Available online at www.sciencedirect.com

SciVerse ScienceDirect

journal homepage: www.elsevier.com/locate/ijnt

Case Report

Cerebrospinal fluid fistula due to penetrating trauma

Kerem Mazhar Ozsoy^a, Guner Menekse^{a,*}, Ali Ihsan Okten^a, Aslan Guzel^b

^a Adana Numune Training and Research Hospital, Department of Neurosurgery, Adana, Turkey

^b Associate Professor of Neurosurgery, Adana Numune Training and Research Hospital, Department of Neurosurgery, Adana, Turkey

ARTICLE INFO

Article history:

Received 18 July 2012

Accepted 6 April 2013

Available online 12 April 2013

Keywords:

Cerebrospinal fluid leak

Fistula

Penetrating injury

ABSTRACT

Penetrating spinal injury with CSF (cerebrospinal fluid) leakage, without neurological deficit is extremely rare. Most of these CSF leakages spontaneously stops and do not threaten life. CSF fistula due to penetrating trauma treated with conservatively in the first step. In the failure of conservative treatment surgery is necessary. Penetrating-cutting insults to the spinal cord are generally caused by back attack to the cervical and thoracic area and usually they are with incomplete cord injury. Most of these cases are caused by knife. In the present study a case with lumbar CSF leakage caused by knife injury treated with surgery without neurological deficit presented.

Copyright © 2013, Neurotrauma Society of India. All rights reserved.

1. Introduction

Penetrating spinal cord injuries caused by knife is more frequent among South Africa and it is reported rare in developed countries. Cord injuries are mostly discussed in the literature. CSF leakage without neurological deficit is not common. Most of these fistulas spontaneously resolve.

2. Case

An 18-year-old male referred to our emergency department after being stabbed in the back with a knife during a fight and suffered CSF leakage without neurological deficit. 2 cm incision in the region of L5 had been sutured. Spinal plain graphs encountered no pathological finding. MRI demonstrated a fistula from skin to the spinal canal at the L5-S1 level (Fig. 1). Tetanus prophylaxis and antibiotic admitted. CSF leakage stops and patient wound was normal. In the fifth day of injury patient discharged but the patient admitted to emergency

department with CSF fistula on the 10th day of injury. The patient operated due to CSF leakage. A vertical incision centered on the site of penetration was made. The incision of the blade was traced and a right L5 laminectomy was performed. Ruptured dura mater was primarily sutured and tissue glue was admitted on sutured area. The postoperative period was uneventful and the patient was discharged at the 5th postoperative day. At the 3rd month the patient was free of CSF leakage or neurological symptoms and sagittal T-2 weighting MR image shows resolution of the knife track (Fig. 2).

3. Discussions

Spinal cord injury generally occurs as a result of vehicle accident, crash and sport injuries. Penetrating spinal injuries among the spinal injuries occurred only 1.5% of cases. Other than firearms injuries predominantly caused by knife (72–90%).^{1–6} Generally these kinds of injuries occur in 14–40 years old male (84%) and usually involve upper thoracic level

* Corresponding author. Adana Numune Egitim ve Arastirma Hastanesi, Nöroşirürji Kliniği, Ege Bagatur Bulvarı, Yuregir, Adana, Turkey. Tel.: +90 5325119929.

E-mail addresses: gunerbc@yahoo.com, gunernrs@gmail.com (G. Menekse).

0973-0508/\$ – see front matter Copyright © 2013, Neurotrauma Society of India. All rights reserved.

<http://dx.doi.org/10.1016/j.ijnt.2013.04.002>

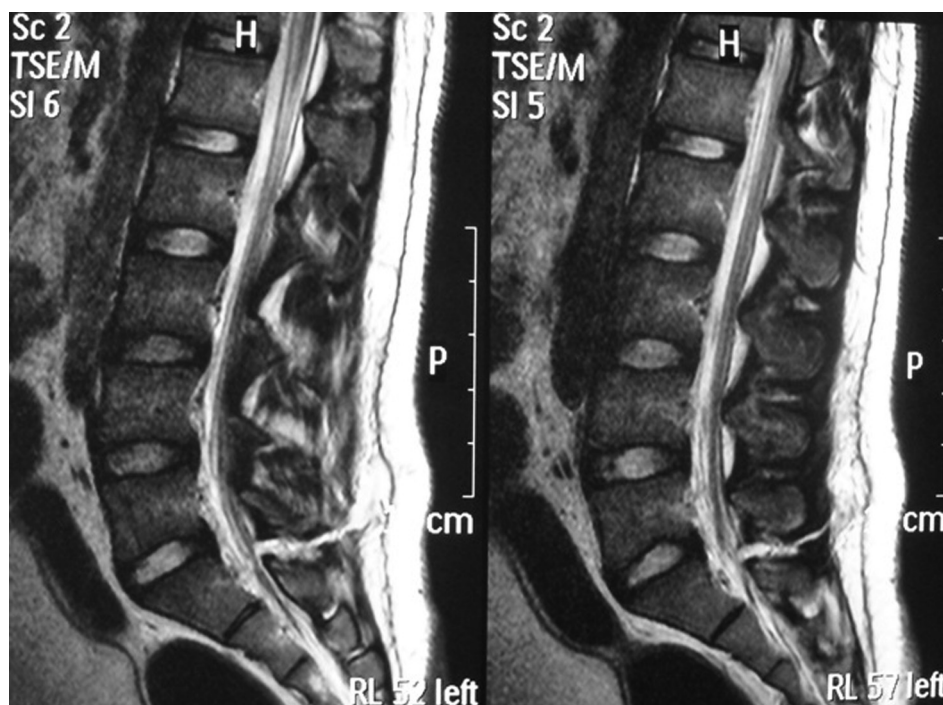


Fig. 1 – Sagittal T-2 weighting MR image shows knife track extending from skin to subarachnoid space.

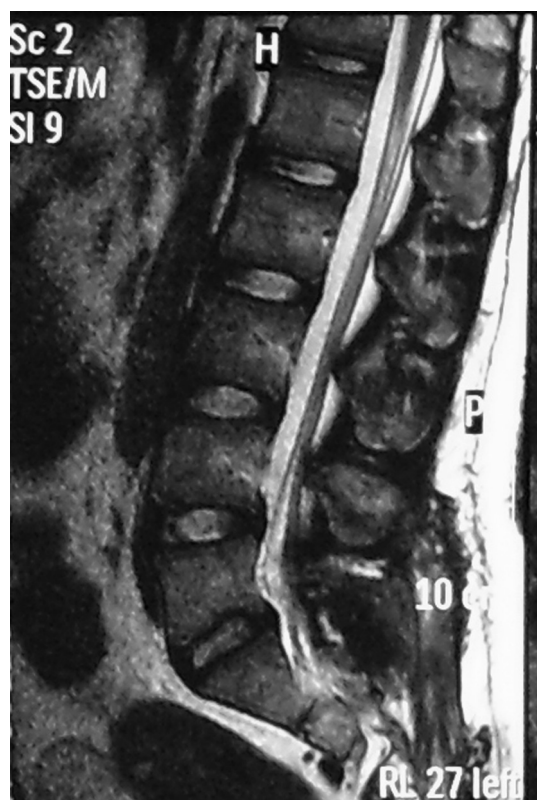


Fig. 2 – Sagittal T-2 weighting MR image at the postoperative third month of stab injury shows resolution of the knife track.

(54–63%) and reported to be less frequent in cervical level (27–30%) and lumbar level (7%).^{1–5,7} Degree of injury is due to tool sharpness, force of the impact and resistance of the body tissue. Clinical picture may be manifested by the cord, roots injury or cauda equina syndrome.^{7–10} In reported cases of penetration to the spinal cord 1/3 of them ended with full cord injury and 2/3 of the with Brown-Sequard and cauda equina syndrome rarely reported.^{4,6,8–12} In the report of the Peacock within the 450 spinal cord knife injuries only 18 cases (4%) showed CSF leakage. Generally CSF leakage heals spontaneously without surgery.⁴

X-Ray graphs are useful to investigate bone injury and gives information about foreign mass. BT show bony structures and foreign mass. MR is the best diagnostic tool to investigate cord injury, soft tissue, disc, ligament injury and epidural subdural and subarachnoid hemorrhage.^{8,9,13–15} The first step in the treatment of the penetrating knife injury is to stop movement of the knife in the spinal region. Generally most of the knives are removed after stable but sometimes they may stuck to soft tissue or bone. In incomplete spinal cord injury treatment is controversial. In incomplete cord injury neurological improvement occurs in 50–60% of cases.¹⁶ The aim of the treatment in neurological intact patients is to remove foreign mass in the light of radiological study with minimum trauma.¹⁷

Local wound care, analgesia, wide spectrum antibiotic and tetanus prophylaxes are recommended in penetrating spinal cord injuries. Surgical indications are foreign mass or bony fragments in central canal, epidural or intradural abscess, CSF leakage more than 4 days.^{3,4,6} In cases with CSF leakage to remove foreign mass and primary suturation of dura mater is the best treatment option.^{7,10,18}

In the report of Rahamimov et al¹⁹ 2 patients with CSF leakage and pneumocephalus successfully recovered with the

following treatment protocol: 1 – Trendelenburg positioning of the patient, 2 – Insertion of a continuous-drainage CSF catheter into the lumbar thecal sac, 3 – Primary suture of the leaking skin wound, 4 – Intravenous antibiotic therapy. In our case, we preferred surgical repair because of delayed presentation.

Complication associated with penetrating cord injuries are wound infection, CSF leakage, post traumatic syrinx, meningitis, sepsis, paraspinal abscess, osteomyelitis, epidural or subdural hematoma, meningocele and internal organ injuries. The prognoses for penetrating sharp tool injuries are generally better than with blunt or gunshot injuries of the spine.

In conclusion MR is the most helpful tool during the diagnosis in cases without metallic fragments inside. CSF leakage treated with surgery in the failure of conservative treatment.

Conflicts of interest

All authors have none to declare.

REFERENCES

1. Heary RF, Vaccaro AR, Mesa JJ, Balderston RA. Thoracolumbar infections in penetrating injuries to the spine. *Orthop Clin North Am.* 1996;27:69–81.
2. Izu T, Iwasaki Y, Sasaki H, Abe H. Spinal cord and root injuries due to glass fragments and acupuncture needles. *Surg Neurol.* 1985;23:255–260.
3. LeBlanc HJ, Gray LW, Kline DG. Stab wounds of the cauda equina. Case report. *J Neurosurg.* 1969;31:683–685.
4. Peacock WJ, Shrosbree RD, Key AG. A review of 450 stab wounds of the spinal cord. *S Afr Med J.* 1977;25(51):961–964.
5. Shahlaie K, Chang DJ, Anderson JT. Nonmissile penetrating spinal injury. Case report and review of the literature. *Neurosurg Spine.* 2006;4:400–408.
6. Thakur RC, Khosla VK, Kak VK. Non-missile penetrating injuries of the spine. *Acta Neurochir (Wien).* 1991;113:144–148.
7. Splavski B, Vranković D, Sarić G, Blagus G, Mursić B, Rukovanjski M. Early management of war missile spine and spinal cord injuries: experience with 21 cases. *Injury.* 1996;27:699–702.
8. Kulkarni AV, Bhandari M, Stiver S, Reddy K. Delayed presentation of spinal stab wound: case report and review of the literature. *J Emerg Med.* 2000;18:209–213.
9. Rubin G, Tallman D, Sagan L, Melgar M. An unusual stab wound of the cervical spinal cord: a case report. *Spine.* 2001;15(26):444–447.
10. Manzone P, Domenech V, Forlino D. Stab injury of the spinal cord surgically treated. *J Spinal Disord.* 2001;14:264–267.
11. Doğan S, Kocaeli H, Taşkapılıoğlu MO, Bekar A. Stab injury of the thoracic spinal cord: case report. *Turk Neurosurg.* 2008;18:298–301.
12. Lipschitz R, Block J. Stab wounds of the spinal cord. *Lancet.* 1962;28(2):169–172.
13. Alkan A, Baysal T, Saras K, Sigirci A, Kutlu R. Early MRI findings in stab wound of the cervical spine: two case reports. *Neuroradiology.* 2002;44:64–66.
14. Jacobsohn M, Semple P, Dunn R, Candy S. Stab injuries to the spinal cord: a retrospective study on clinical findings and magnetic resonance imaging changes. *Neurosurgery.* 2007;61:1262–1267.
15. Moyed S, Shanmuganathan K, Mirvis SE, Bethel A, Rothman M. MR imaging of penetrating spinal trauma. *AJR Am J Roentgenol.* 1999;173:1387–1391.
16. Velmahos GC, Degiannis E, Hart K, Souter I, Saadia R. Changing profiles in spinal cord injuries and risk factors influencing recovery after penetrating injuries. *J Trauma.* 1995;38:334–337.
17. Jallo GI. Neurosurgical management of penetrating spinal injury. *Surg Neurol.* 1997;47:328–330.
18. Seçer M, Gezici AR, Dalgic A, Ergüngör MF. Delayed pseudomeningocele as a result of penetrating injury: case report. *Ulus Trauma Acil Cerrahi Derg.* 2011;17:189–191.
19. Rahamimov N, Mulla H, Freiman S. Cerebrospinal fluid leakage and pneumocephalus secondary to spine stab wounds. *J Orthop Traumatol.* 2010;11:57–59.