

Case report

Clinical, MRI and electrographic characteristics of three children with Hemiconvulsion-Hemiplegia/Hemiconvulsion-Hemiplegia-Epilepsy (HH/HHE) syndrome—A rare childhood epileptic encephalopathy



Yeeshu Singh Sudan, K.P. Vinayan*, Arun Grace Roy

Division of Pediatric Neurology, Department of Neurology, Amrita Institute of Medical Sciences, Amrita University, Kochi, India

ARTICLE INFO

Article history:

Received 1 August 2016

Accepted 21 December 2016

Available online 6 January 2017

Keywords:

Hemiconvulsion

Hemiplegia

Epilepsy

Status epilepticus

ABSTRACT

Hemi convulsion-Hemiplegia-Epilepsy (HH/HHE) syndrome is a very rare catastrophic epileptic syndrome in childhood which follows a prolonged focal motor status epilepticus in infancy and early childhood. Here we are describing the clinical, MRI and electrographic characteristics along with long term outcome of three children with HH/HHE syndrome. A review of the current literature on HH/HHE syndrome is attempted stressing on the diagnostic features and the neurobiological relationship between prolonged focal motor status epilepticus and subsequent development of HH/HHE syndrome. Early identification of this syndrome may help the treating physician in providing families with a relatively accurate prognosis regarding the functional outcome and subsequent development of epilepsy.

© 2016 Indian Epilepsy Society. Published by Elsevier, a division of RELX India, Pvt. Ltd. All rights reserved.

1. Introduction

Hemi convulsion-Hemiplegia-Epilepsy (HH/HHE) syndrome is a very rare epileptic encephalopathy which follows a prolonged focal motor status epilepticus in infancy and early childhood.¹ The focal motor seizure usually occurs during the course of a febrile illness. HH/HHE syndrome is characterized by a specific clinical sequence; initially it starts with an acute episode of prolonged clonic seizures with unilateral predominance (hemiconvulsions) which is immediately followed by flaccid hemiplegia (a hemi convulsion- hemiplegia episode). This acute phase is followed by characteristic cerebral hemi atrophy with subsequent appearance of epilepsy after a variable period of epileptogenesis.² There are very few reports of HH/HHE in the recent literature. Here we report three children who presented to our department with this rare epileptic encephalopathy over a period of 3 years at different stages of the natural history of HH/HHE syndrome. This retrospective clinical study has been approved by the institutional ethics committee.

Case 1

3 1/2 year old boy presented to our emergency department with short duration fever and multiple episodes of right sided focal clonic seizures involving both upper and lower limbs. Child continued to have seizures for the next three days and was managed by multiple antiepileptic drugs and anesthetic agents in the intensive care setting. Eventually seizures were controlled on the 8th day of illness. During this time, child was noted to have right sided hemiplegia. Initial EEG (Fig. 1) showed asymmetric suppression of electrical function over the left hemisphere with delta slowing over the right. Very frequent seizures were also noted arising from left posterior head region (Fig. 2). Initial MRI brain (Fig 3A and B) at the time of admission showed diffusion restriction in gyral and sub cortical region of left hemisphere. Repeated imaging after 3 weeks (Fig. 4A and B) showed gyral hyper intensities with diffusion restriction and contrast enhancement involving the entire left cerebral cortex. CSF studies and investigations for a possible vasculitis were noncontributory.

Gradually the condition of the child improved and seizures were controlled on multiple antiepileptic drugs and steroids. He had a prolonged hospital stay of 2 months and had residual right hemiparesis at the time of discharge. MRI brain (Fig. 5A–C) repeated after 7 months of initial MRI, showed diffuse hemi atrophy of left hemisphere.

* Corresponding author.

E-mail address: vinayankp@aims.amrita.edu (K.P. Vinayan).

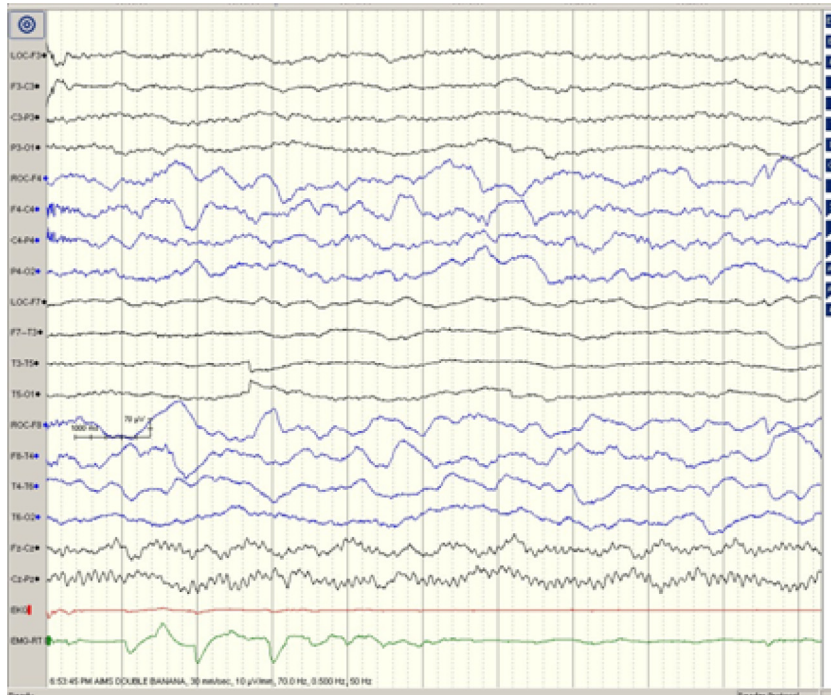


Fig. 1. Case 1 Day 1. Interictal EEG in the bipolar longitudinal montage showing asymmetric suppression of electrical function on left side with delta slowing over right hemisphere. (Paper speed 30 mm/s, high frequency filter 70 Hz, low frequency filter 0.5 Hz, Notch filter 50 Hz, 10 microvolt/mm).

No further clinical seizures were recorded during 2 years of follow up and child continued to improve slowly. At the last contact, child could walk unaided but still gait was abnormal with

spasticity of both right upper and lower limbs. EEG (Fig. 6) at the last follow up showed asymmetric slowing over the left

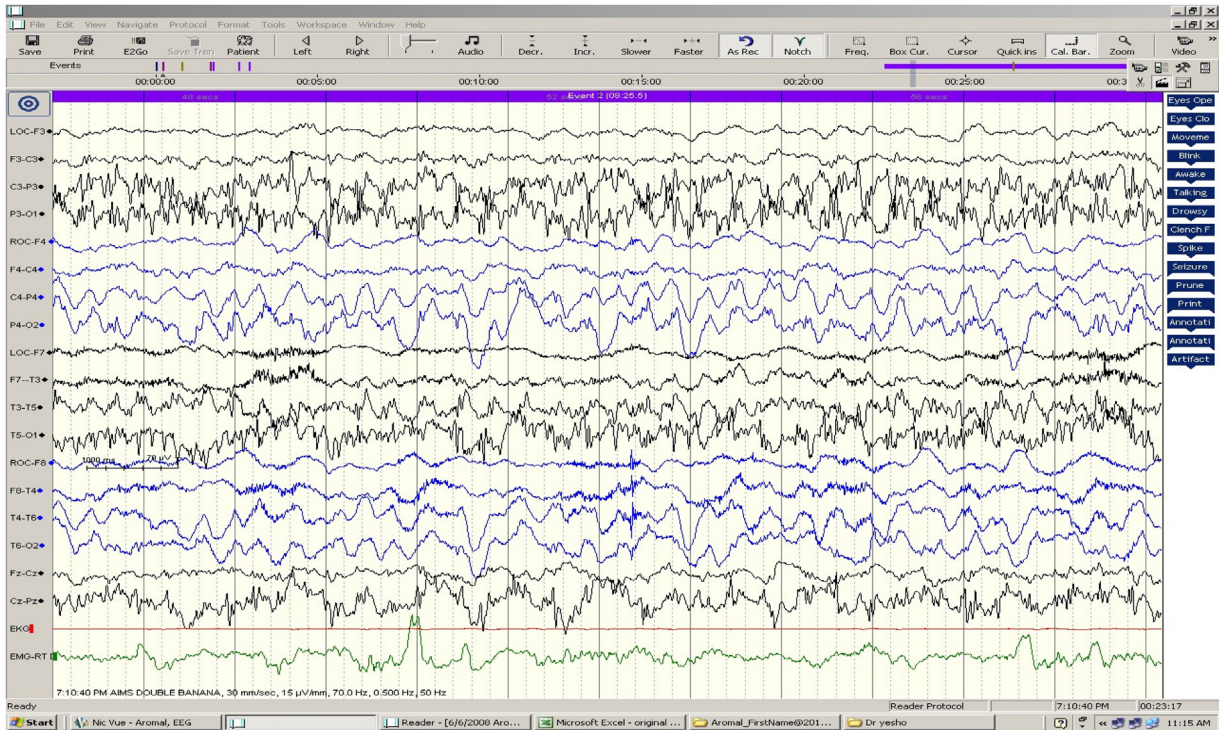


Fig. 2. Case 1, Day 1: EEG in the bipolar longitudinal montage showing the ictal pattern over the left posterior head region. (Paper speed 30 mm/s, high frequency filter 70 Hz, low frequency filter 0.5 Hz, Notch filter 50 Hz, 15 microvolt/mm).

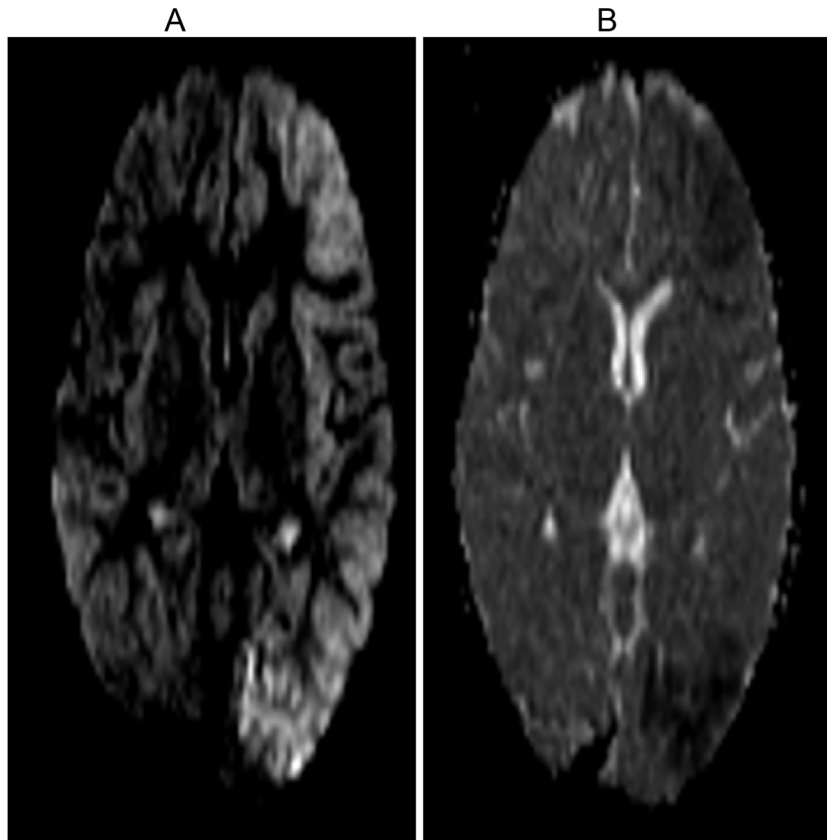


Fig. 3. Case 1: Initial MRI brain at presentation—showing significant diffusion restriction in diffusion weighted image (A) with decreased apparent diffusion coefficient (B) involving left hemisphere.

hemisphere with predominantly left hemispheric multifocal spike and waves. Anti-epileptic drugs were being gradually tapered.

Case 2

This was a 2.5 year old boy, first child of third degree consanguineous marriage with no significant antenatal issues

and normal developmental milestones. Child had a history of simple febrile seizures at 1.5 year of age. After 4 months, child again had a prolonged right sided focal seizures leading to refractory focal motor status epilepticus associated with fever, which was managed by multiple AEDs in another hospital. During this time, he developed right upper and lower limb weakness which persisted after discharge from the hospital. CT head (Fig. 7)

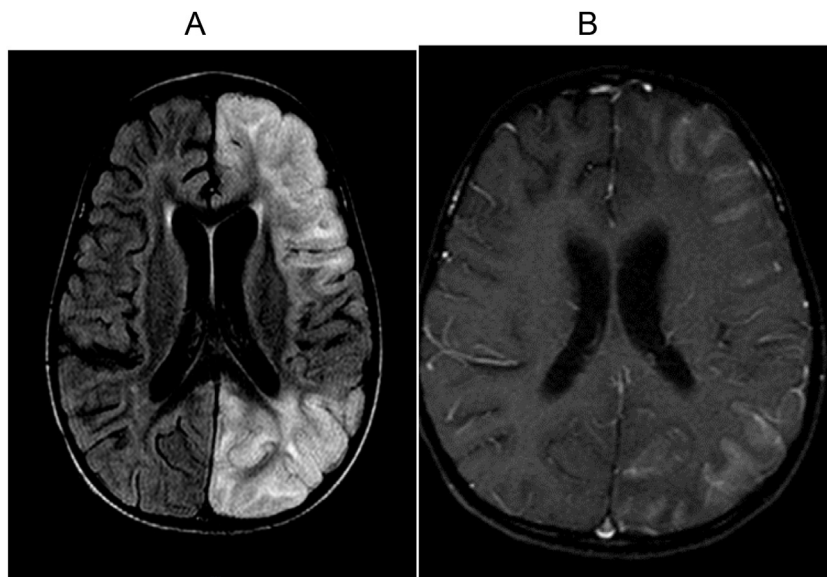


Fig. 4. Case 1 MRI AFTER 3 WEEKS. A) T2 flair axial sequence showing diffuse left cerebral hyper intensities diffusely over left cerebral hemisphere. B) T 1 Axial with contrast sequence showing gyral enhancement diffusely over left hemisphere.

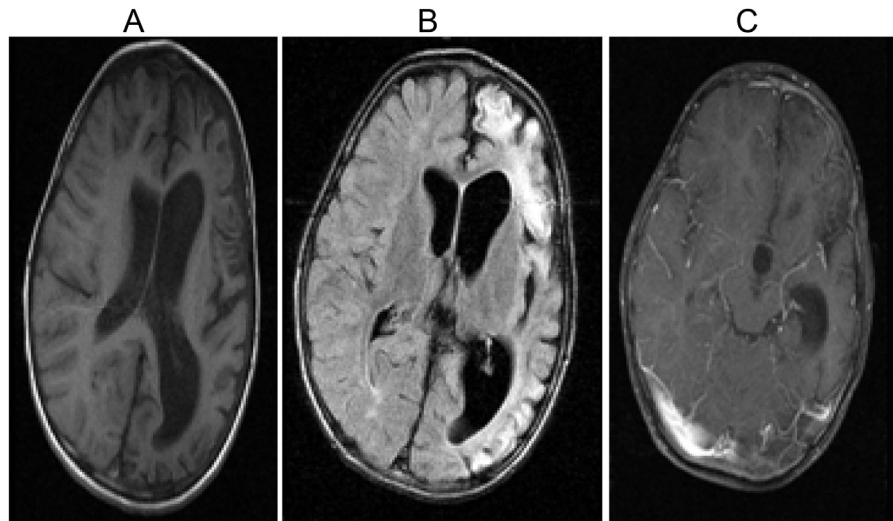


Fig 5. Case 1 MRI after 7 months.

A). T1 axial view showing significant atrophy of the left hemisphere. B) T2 flair images showing left hemisphere atrophy and prominent dilated ventricles along with hyper intense signal from left hemisphere in gyriform pattern with subcortical white matter extension. C) T1 AXIAL contrast showing no abnormal enhancement of lesions.

showed diffuse hypodensities over the left hemisphere. MRI brain taken after 3 months of the onset of right hemiparesis (Fig. 8A–C), showed mild diffuse atrophy of left cerebral hemisphere. CSF study was normal. Child had right sided weakness which improved gradually over the next few months. Child was seizure free then for the next 5 months. He presented to our hospital with multiple episodes of clonic seizures involving right upper and lower limbs despite on multiple AEDs. We repeated the MRI brain (Fig. 9A–C) after 6 month of the initial insult which showed diffuse atrophy of left cerebral hemisphere. EEG showed diffuse slowing of left cerebral hemisphere with left fronto temporal epileptiform

abnormalities. At the last follow up at 6 years of age, he is seizure free on multiple anti-epileptic drugs with a residual right hemiparesis. He had persisting epileptiform abnormalities over the left hemisphere.

Case 3

This was a 10 year old boy at the time of presentation with past history of low birth weight along with documented hypoglycemia and seizures on day 3 of life. He had global developmental delay. At the age of 5 years, he had an episode of prolonged focal seizures

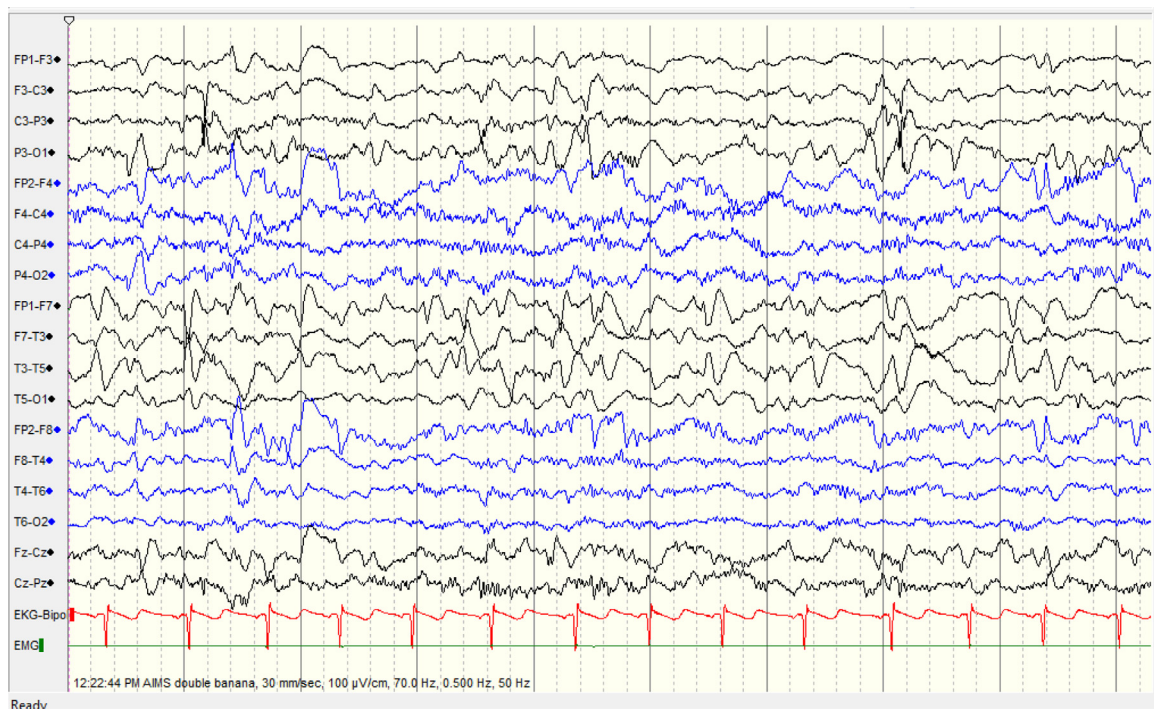


Fig. 6. Case 1 EEG at 2 years of follow up: In bipolar longitudinal montage showing asymmetric slowing over the left hemisphere with predominantly left hemispheric multifocal spike and waves. (Paper speed 30 mm/s, high frequency filter 70 Hz, low frequency filter 0.5 Hz, Notch filter 50 Hz, 10 microvolt/mm).

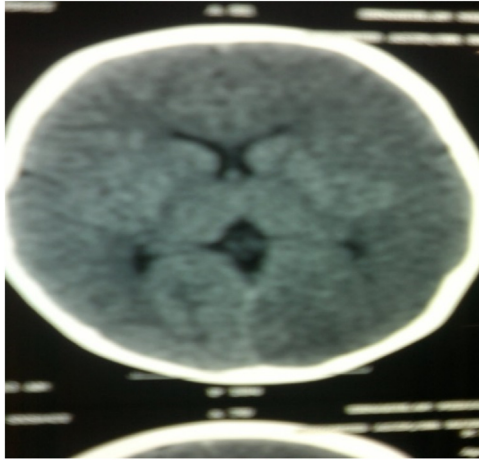


Fig. 7. Case 2. Initial CT head showing hypo dense area involving whole of the left hemisphere.

involving right side of body followed by right sided hemiparesis. Child did not have any further seizures after that and he was maintained on antiepileptic drugs. He came to our department for evaluation of persisting hemiparesis and neurocognitive problems. Examination revealed right sided hemiparesis with right upper motor neuron facial palsy along with moderate mental retardation. MRI Brain (Fig. 10A–C) showed diffuse atrophy of left cerebral hemisphere and right parieto-occipital region with ex vacuo dilatation of left lateral ventricle and occipital horn of right lateral ventricle. EEG showed suppression of background on left hemisphere with right parietal epileptiform abnormalities. He did not have further epileptic seizures till the last follow up at 13 years of age. He is on monotherapy with valproate.

2. Discussion

Hemiconvulsion–Hemiplegia/Hemiconvulsion–Hemiplegia–Epilepsy (HH/HHE) syndrome was first reported by Gastaut and colleagues¹ in 1957. He published a series of 150 patients, studied clinically and electroencephalographically and described this syndrome consisting of hemiconvulsions and hemiplegia occurring in the initial years of life, a seizure free interval with possible regression of the motor deficit and ultimate appearance of psychomotor epilepsy. Pathophysiology of this syndrome still remains poorly understood and the long-term cognitive outcomes

are still unclear. The incidence of HH/HHE has declined considerably over the last 20 years in developed countries. This inference is largely based on the lack of published large clinical series since 1995. It may suggest the current availability of relatively better management strategies for prolonged seizures in young children, especially the abortive treatments with benzodiazepines. A decrease in the incidence of febrile status epilepticus due to increased rates of childhood immunizations may be another factor. Incidence from developing countries is largely unknown. Most of the recent reports include only very small number of patients which indicate the relative rarity of this clinical entity. A list of recently reported case series of HH/HHE is given in Table 1.

The initial episode of HH/HHE syndrome has its peak incidence during the first 2 years of life, mostly between 5 months and 2 years of age, with only few patients who are 4 years or older.³ In this clinical series, all the children had the initial event of seizures before 5 years of age. In approximately three fourths of patients, the HH episode evolves to the secondary appearance of focal epilepsy. The average interval from the prolonged initial convulsion to chronic epilepsy was 1 to 2 years, but it can be delayed up to 5–10 years. HH/HHE syndrome may be divided into 3 distinct clinical stages as initial hemiconvulsion, followed by a stage of residual hemiplegia and later onset of focal epilepsy. The syndrome starts as a hemiconvulsion which may be a prolonged one. It frequently involves whole of the affected side and sometimes last even more than 24 hours. This prolonged status epilepticus is usually preceded by a febrile episode which may usually be a minor childhood infection.³ The seizure is usually unilateral clonic with variable degree of impairment of consciousness, and autonomic symptoms (cyanosis, hyper salivation, respiratory dysfunction). If very prolonged, convulsions may spread to the other side or may rarely change sides. Control of seizures at this stage may be of paramount importance as it may prevent further damage to the brain and subsequent development of epilepsy.

The second hemiplegic stage of the syndrome immediately follows the prolonged convulsive episode. It may initially be flaccid and involves both upper and lower limbs but may gradually become spastic as time passes. The minimum duration of the hemiplegia should be more than 7 days in order to separate it from the post ictal or Todd's paralysis. In 20% of the cases, the hemiplegia may not remain permanent and may disappear within 1 to 12 months.¹ The third stage of HH/HHE is focal epilepsy which is variable and may not be present in all the cases. The average interval from initial convulsions to chronic epilepsy is 1–4 years. A study by Vivaldi⁴ reported a range of 1 month to 9 years after the

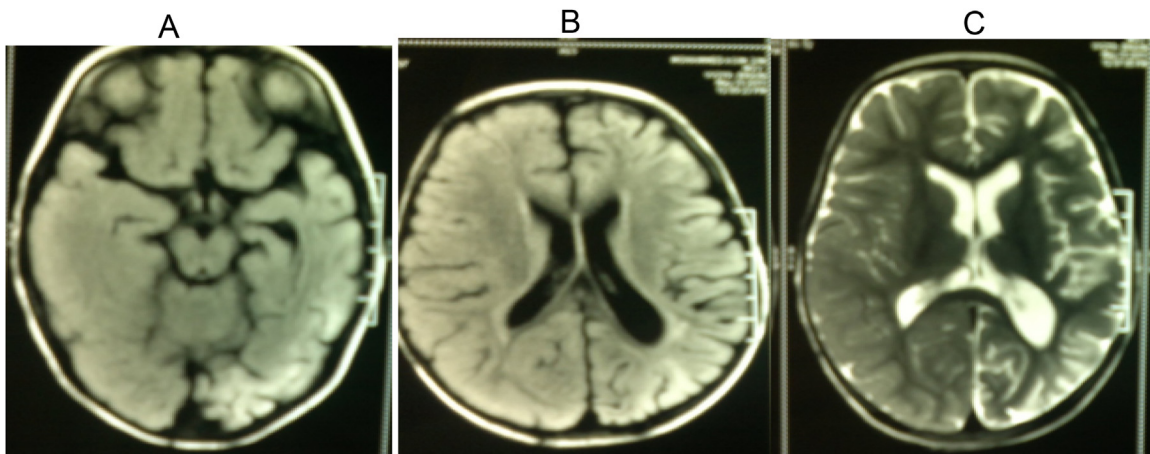


Fig. 8. case 2 MRI brain at 3 months A, B) MRI axial T2 flair images showing hyperintense signal involving whole of the left hemisphere with minimal atrophy and prominent dilated lateral ventricles. C) Axial T2 image showing similar findings.

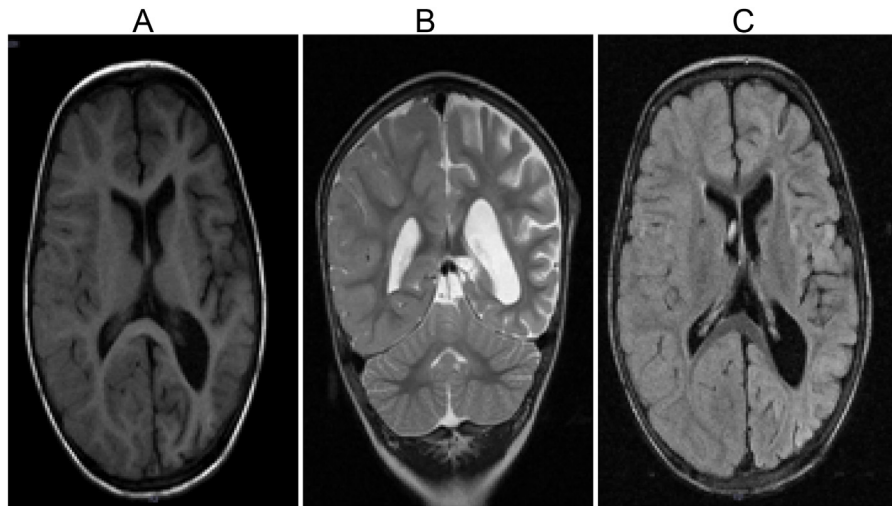


Fig. 9. Case 2. MRI brain after 6 months A) T1 axial view showing left hemisphere atrophy. B) T2 coronal view showing left Hemisphere atrophy. C) T2 flair axial images with similar findings. No hyper intensities were seen.

acute episode. Approximately two thirds of the late seizures are focal seizures with alteration of consciousness. Gastaut et al.¹ initially considered that the epilepsy is always comprised of focal seizures originating from the temporal lobe but Chauvel and Dravet⁵ studied adult cases with HHE and showed that the origin of seizures could be in temporal, fronto temporal or parieto central regions. Case 1 and 3 of our series did not develop focal epilepsy till the last contact. This might be due to the changes in natural history due to the relatively early treatment with immunotherapy. Another possible hypothesis is the prolonged window period of epileptogenesis, and these children may develop focal epilepsy at a later date. Case 2 developed focal epilepsy after 5 months of initial insult. Table 2 summarizes demographic, clinical and follow up data of all the three children.

HH/HHE syndrome may be divided into 2 groups. Idiopathic HH/HHE is associated with fever of systemic infections and commonly presents as febrile convulsions. In such cases, the prolonged seizure activity itself may be responsible for the

appearance of new lesions occurring in a previously normal brain. Epilepsy and neurological sequelae might be the direct consequence of seizures. Case 1 and 2 of this cohort are probably idiopathic HH/HHE.

Symptomatic type is associated with fever as well as some identified, predisposing factors like head trauma, subdural effusions, meningitis, or cerebral vascular disease prior to the onset of HH. The prolonged seizure would then produce or contribute to the development of irreversible brain damage with resultant focal epilepsy. Case 3 of this series is probably symptomatic.

The exact etiopathogenesis of HH/HHE syndrome remains unclear. The duration of the initial event, the cortical structures involved in the propagation of the initial seizure, and the epileptogenicity of the brain lesions resulting from the initial event are supposed to be the major factors contributing to the final outcome. The pathogenesis may also be related to causes of prolonged febrile seizures like genetic factors and pre-existing

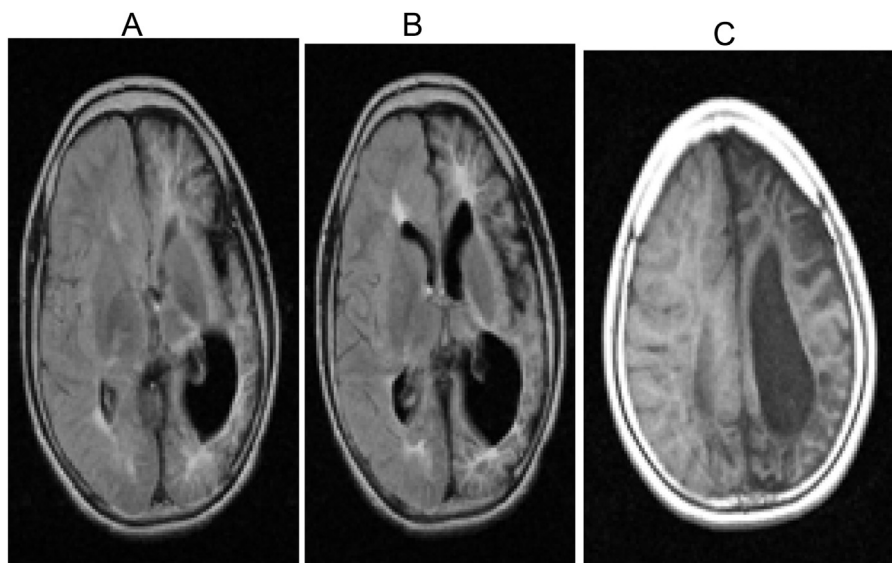


Fig. 10. Case 3. 5 years after the initial status (A, B, C)MRI brain Flair axial view showing diffuse atrophy of left cerebral hemisphere and right parieto-occipital region with ex vacuo dilatation of left lateral ventricle and occipital horn of right lateral ventricle.

Table 1
Recent literature on HH/HHE syndrome.

Case report/case series	Year of publication	Pts characteristics	HH/HHE	No. of pts	Idiopathic/symptomatic	Important finding
van Toorn R et al. ¹⁶	2011	4-M 4 pts – F	HHE	8	Idiopathic	Crossed cerebellar atrophy in 2 pts
Mirsattari SM ¹⁷	2008	Case series	HHE	5	Idiopathic, symptomatic	Poor Long term cognitive outcome
Kim DW ¹⁴	2008	TLE gp-12 Multifocal gp-14	HHE	26 Pts	NA	Surgical intervention may be helpful in resistant epilepsy DW images may be the only abnormality in initial period.
Arrese-Gispert L ¹⁸	2005	Case 1–16 months/ F Case2- 2.6y F	HH	2	Case1 Idiopathic case 2 symptomatic	
Yamazaki S ⁹	2011	5 y	HHE	1	Idiopathic	CACNA1A S218L mutation
Gupta R ¹⁹	2014	3 y girl	HHE/	1	Symptomatic	1q44 microdeletion
Shimakawa S ²⁰	2014	1 y – onset	HHE	1	Idiopathic	ACTH improved seizures

Abbreviations; – HH- Hemi convulsion-hemiplegia, HHE- Hemi convulsion-hemiplegia epilepsy, pts – patient, M- male, F – female. DW –diffusion weighted. ACTH – Adrenocorticotrophic hormone, TLE – Temporal lobe epilepsy.

cortical lesions. Pathologic examinations showed cytotoxic edema along with spongiosis and disruption of the normal cellular architecture.⁶ It has been proposed that these changes could be related to the primary, presumed viral infection with resultant inflammatory cytokine damage.⁷ There has also been speculation that the syndrome is directly related to the prolonged ictal activity. This prolonged, ictal activity could cause excessive neuronal excitation via N-methyl-D-aspartic acid (NMDA) glutamate receptors. This could also lead to a cascade of increased intracellular calcium causing cytotoxic edema and eventual necrosis and apoptosis. It has been proposed that HH/HHE syndrome, along with febrile infection related epilepsy syndrome (FIRES) may constitute a spectrum of inflammatory mediated encephalopathy syndromes with the difference in clinical expression related to the stage of brain maturation.⁸ There are no known underlying genetic factors consistently associated in children with HH/HHE syndrome, however there are several case reports of HH/HHE syndrome associated with CACN1 A mutation,⁹ protein S deficiency,¹⁰ factor V Leiden mutation¹¹ and L-2-hydroxyglutaric acidurias.¹² These cases demonstrate the etiologic heterogeneity of this epileptic syndrome.

Immediately after the initial HH episode, CT scan may show unilateral swelling and edema of the hemisphere involved in the epileptic discharge. Later, rather characteristic uniform hemi atrophy with midline displacement is observed. Magnetic resonance imaging (MRI) brain show, in the early stages, hyper intensities located throughout the affected cerebral cortex predominantly involving the grey matter on T2 sequences and diffusion restriction with a decreased apparent diffusion

coefficient, which would indicate that the underlying lesion is cytotoxic edema.¹³ After a period of several days, these changes disappear and brain atrophy becomes evident uniformly affecting an entire hemisphere, both cortical and sub cortical, with dilatation of the ventricular system. Cases 1 and 2 clearly demonstrate this characteristic evolution of neuroimaging findings (Figs. 3–5, 7–9). This pattern makes it possible to differentiate HH/HHE syndrome from focal atrophies that appear in perinatal lesions of ischemic origin. An important distinguishing feature from ischemic stroke is that these abnormalities are independent of any vascular territory

The inter ictal EEG showed multifocal spikes and sharp waves, as well as generalized and bilateral slow waves. Widespread inter ictal abnormalities were more frequently encountered in the symptomatic category of HH/HHE patients. Even when radiologic studies suggested a strictly unilateral pathology, the distribution of EEG anomalies was more diffuse with multifocal inter ictal spiking suggesting the possible existence of multiple epileptic networks.

The best approach to reduce the incidence of post convulsive hemiplegia and late-onset focal epilepsy is the prompt recognition and early vigorous treatment of prolonged seizures of any etiology, especially of febrile convulsions in children. The role of immunotherapy is not established, however a trial may be worthwhile in the acute setting. After some variable period (months to years) of seizure freedom, approximately two-thirds of patients will develop epilepsy that in many cases becomes intractable. There is evidence that surgical treatment of delayed intractable epilepsy in HH/HHE syndrome is beneficial.¹⁴ Surgical interventions including focal resections, hemispherectomy and callosotomy

Table 2
Demographic, clinical and follow up data of 3 children with HH/HHE syndrome.

Cases	Age at presentation	Sex	Development/ Past history	Age at the time of hemiconvulsion/ Hemiplegia	EEG	Initial Imaging MRI/CT	Follow up imaging MRI	Epilepsy on last follow up
Case 1	3.5 Y	Male	Normal	3.5 years	Left parieto temporal discharges	MRI –Cortical and subcortical HI on T2 weighted images, DW restriction of Left Hemisphere.	Diffuse atrophy of left hemisphere	Absent
Case 2	2.5 y	Male	Febrile seizure	1.9 years	Left fronto temporal slowing with discharges	CT – Diffuse hypo densities over the left Hemisphere	Diffuse atrophy of left cerebral hemisphere	Present
Case 3	10 y	Male	GDD, neonatal seizures	5 years	Left hemispheric back ground suppression with right parietal discharges	No data available	Diffuse atrophy of left cerebral hemisphere	Absent

Abbreviations; HI – Hyper intensities, DW- Diffusion weighted, GDD – global developmental delay.

have been tried in the past. Kwan et al.,¹⁵ reported 4-year follow-up in three children who underwent callostomy. All patients experienced a significant reduction of generalized tonic seizures.

3. Conclusion

This case series reports the clinical – radiological features and long term outcome of 3 children with HH/HHE syndrome, managed with current therapeutic protocols. HH/HHE along with recently described febrile infection related epileptic syndrome (FIRES) may constitute a spectrum of febrile illness triggered epileptic encephalopathies with a shared neurobiology.

Conflict of interest

None.

Disclosures

Nil.

Contribution credit

YS: Data collection, analysis, and preparation of manuscript. VKP: conceptualized and supervised the data. AG: critically reviewed the literature.

Acknowledgements

Nil.

References

- Gastaut H, Poirier F, Payan H, et al. H.H.E. syndrome: hemiconvulsions, hemiplegia, epilepsy. *Epilepsia*. 1959;1:418–447.
- Tenney JR, Schapiro MB. Hemiconvulsion-hemiplegia-epilepsy syndrome. *Neurology*. 2012;79(1):e1–e4.
- Aicardi J, Chevrie Jv. Convulsive status epilepticus in infants and children: a study of 239 cases. *Epilepsia*. 1970;11:187–197.
- Vivaldi J. *Les crises hémicloniques de l'enfant: modalités évolutives* Thèse, Marseille. .
- Chauvel P, Dravet C, et al. The HHE syndrome. In: Roger, ed. *Epileptic Syndromes in Infancy, Childhood, and Adolescence*. 4th ed. Montrouge John Libbey Eurotext; 2005:277–293.
- Freeman J, Coleman L, Smith L, et al. Hemiconvulsion-hemiplegia-epilepsy syndrome: characteristic early magnetic resonance imaging findings. *J Child Neurol*. 2002;17:10–16.
- Auvin S, Devisme L, Maurage C, et al. Neuropathological and MRI findings in an acute presentation of hemiconvulsion-hemiplegia: a report with pathophysiological implications. *Seizure*. 2007;16:371–376.
- Patil SB, Roy AG, Vinayan KP. Clinical profile and treatment outcome of febrile infection-related epilepsy syndrome in South Indian children. *Ann Indian Acad Neurol*. 2016;19(2):188–194.
- Yamazaki S, Ikeno K, Abe T, et al. Hemiconvulsion-hemiplegia-epilepsy syndrome associated with CACNA1A S218L mutation. *Pediatric Neurol*. 2011;45:193–196.
- Mondal RK, Chakravorty D, Das S. Hemiconvulsion, hemiplegia, epilepsy syndrome and inherited protein S deficiency. *Indian J Pediatr*. 2006;73(2):157–159.
- Scantlebury MH, David M, Carmant L. Association between factor V Leiden mutation and the hemiconvulsion, hemiplegia, and epilepsy syndrome: report of two cases. *J Child Neurol*. 2002;17:713–717.
- Lee C, Born M, Salomons GS, et al. Hemiconvulsion-hemiplegia-epilepsy syndrome as a presenting feature of L-2-hydroxyglutaric aciduria. *J Child Neurol*. 2006;21:538–540.
- Kataoka K, Okuno T, Mikawa H, et al. Cranial computed tomographic and electroencephalographic abnormalities in children with post-hemiconvulsive hemiplegia. *Eur Neurol*. 1988;28:279–284.
- Kim D, Kim K, Chu K, et al. Surgical treatment of delayed epilepsy in hemiconvulsion-hemiplegia-epilepsy syndrome. *Neurology*. 2008;70:2116–2122.
- Kwan SY, Wong TT, Chang KP, et al. Seizure outcome after corpus callosotomy: the Taiwan experience. *Child's Nerv Syst*. 2000;16:87–92.
- VanToorn R, Janse van Rensberg P, Solomons R, et al. Hemiconvulsion-hemiplegia-epilepsy syndrome in South African children: insights from a retrospective case series. *Eur J Paediatr Neurol*. 2011;16(2):142–148.
- Mirsattari SM, Wilde NJ, Pigott SE. Long-term cognitive outcome of hemiconvulsion-hemiplegia epilepsy syndrome affecting the left cerebral hemisphere. *Epilepsy Behav*. 2008;13(4):678–680.
- Arrese-Gispert L, Gutierrez-Solana LG, Garcia-Penas JJ, et al. Hemiconvulsion hemiplegia syndrome: two case reports with findings from magnetic resonance imaging of the brain in diffusion-weighted sequences. *Rev Neurol*. 2005;41(6):344–348.
- Gupta R, Agarwal M, Boqqula VR, et al. Hemiconvulsion-hemiplegia-epilepsy syndrome with 1q44 microdeletion: causal or chance association. *Am J Med Genet A*. 2014;164A(1):186–189.
- Shimakawa S, Nomura S, Ogino M, et al. ACTH therapy on intractable epilepsy in Hemiconvulsion-Hemiplegia-Epilepsy syndrome. *Brain Dev*. 2015 Aug;37(7):733–737.