


Available online at www.sciencedirect.com

ScienceDirect

journal homepage: <http://www.journals.elsevier.com/international-journal-of-epilepsy>

Case Report

Refractory status epilepticus: Febrile Illness Related Epileptic Syndrome (FIRES)



Varun Kumar Sharma*, Anaita Udwadia Hegde, Fazal Nabi

Jaslok Hospital and Research Centre, Mumbai, India

ARTICLE INFO

Article history:

Received 26 November 2014

Accepted 20 July 2015

Available online 1 October 2015

Keywords:

Refractory epilepsy

FIRES

Ketogenic diet

Lacosamide

ABSTRACT

In recent literature, a new entity has emerged, which focuses on a possible non-encephalitic epileptic encephalopathy precipitated by fever in a previously normal child. We report a typical case of Febrile illness related epileptic syndrome (FIRES) from Indian subcontinent. The index case presented with fever and multiple seizures, which progressed to status epilepticus and encephalopathy. All infectious, metabolic and autoimmune markers were negative. Convulsions were refractory to all possible treatment except thiopentone which achieved burst suppression pattern. Breakthrough seizures were prevented by using lacosamide and ketogenic diet along with multiple anticonvulsants. At 1-year follow-up, patient had a relatively good neurological outcome, however has persistent refractory epilepsy.

© 2015 Indian Epilepsy Society. Published by Elsevier B.V. All rights reserved.

1. Introduction

In India, viral encephalitis is an important cause of mortality and morbidity in children. Despite latest diagnostic modalities, no etiological agent is identified in many cases.¹ In recent literature, a new entity has emerged which focuses on a possible non-encephalitic refractory status epilepsy precipitated by non-specific fever in previously normal children. The typical clinical presentation, characteristic seizure semiology, CSF and MRI imaging findings merit it to be listed under the most recent accepted term known as Febrile illness related epileptic syndrome (FIRES).^{2,3}

2. Case report

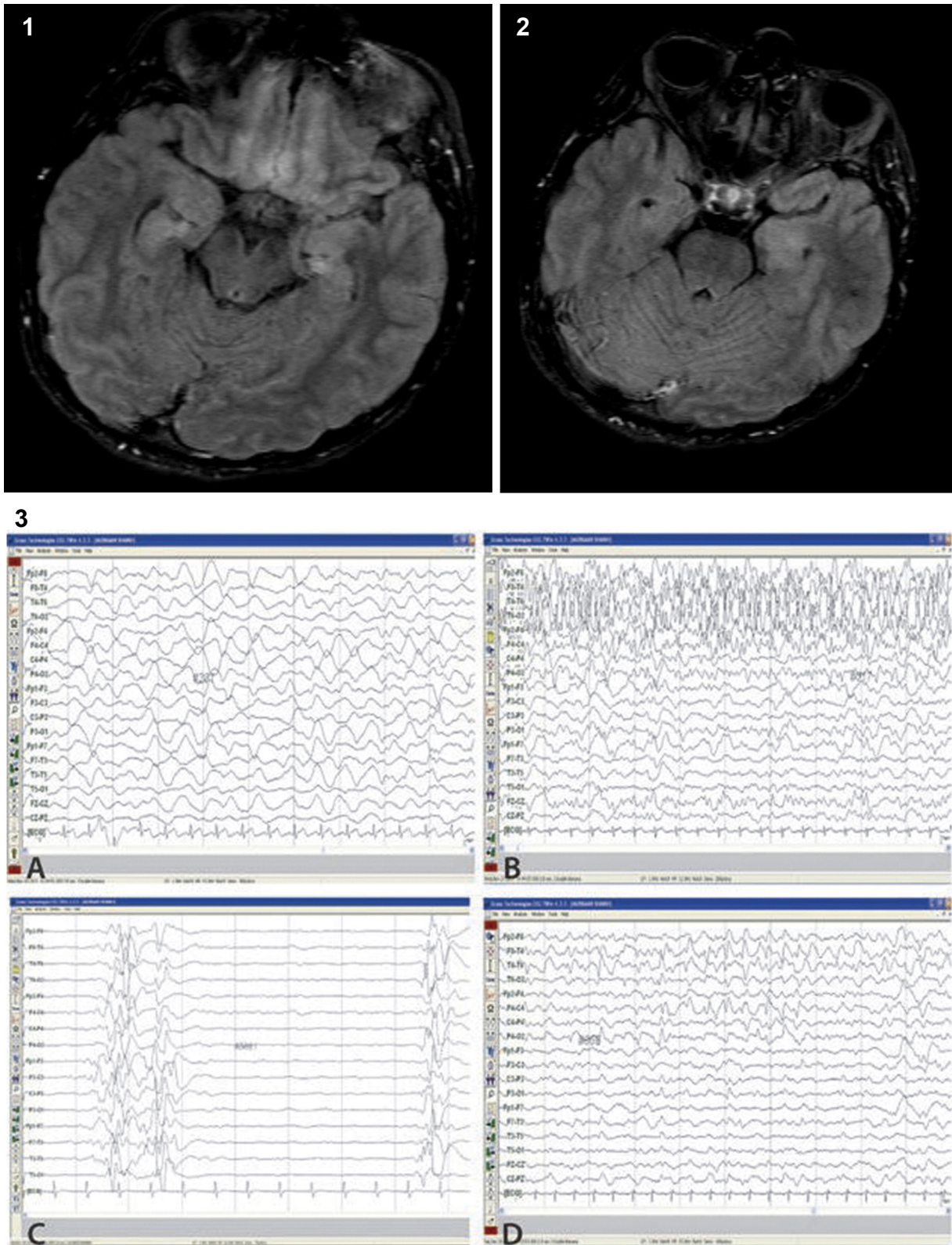
A 13-year-old, previously healthy school-going adolescent girl was admitted to the PICU with two episodes of seizures,

which was complex partial in nature. There was history of fever since 3 days and headache since 1 day. On admission in our PICU she was afebrile, conscious, following commands but was slightly irritable. There was no neurological deficit, no signs of meningeal irritation or raised intracranial tension. Past medical, surgical, family, social and environmental exposure history was unremarkable.

CSF microscopy revealed 8 cells/mm³ and all were lymphocytes. CSF glucose was 54 mg/dl with a simultaneous blood glucose level of 95 mg/dl. Protein was 45 mg/dl. CSF bacterial culture was negative. CSF for HSV PCR, entire DNA and RNA viral panel (Rapid nucleic acid amplification) was also negative. Anti-NMDA and anti VGKC antibodies were negative. MRI of brain showed very subtle gyriform intracortical hyperintensities on FLAIR images through the lateral perisylvian cortex of the left cerebral hemispheres accompanied by hyperintensities in the left uncus and possibly the left hippocampus (Figs. 1 and 2).

Patient was treated with intravenous ceftriaxone, acyclovir and phenytoin. During the initial hospital course patient

* Corresponding author at: 2007/2, 20th Floor, Jaslok Hospital, Dr G Deshmukh Marg, Peddar Road, Mumbai 400026, India. Tel.: +91 09769860225. E-mail address: drvarun1983@gmail.com (V.K. Sharma).



Figs. 1 and 2 – Subtle gyriform intracortical hyperintensities on FLAIR images through the lateral perisylvian cortex of the left cerebral hemispheres accompanied by hyperintensities in the left uncus and hippocampus. Fig 3(A) EEG showing diffuse large amplitude slow waves; (B) EEG showing continuous epileptiform discharges; (C) Burst suppression pattern on tapering Thiopentone; (D) EEG with diffuse slowing along with interictal discharges over both hemisphere but predominantly in right frontal region.

developed recurrent seizures which started over the face with occasional progress to entire left side of the body. Termination of seizures was achieved by intermittent dose of intravenous midazolam or lorazepam. The frequency of seizures increased from two to eleven convulsions per day by the sixth day despite use of three first line anticonvulsants (phenytoin, levetiracetam and sodium valproate) in maximum maintenance dose. Bed side EEG was done at regular intervals which showed diffuse large amplitude slow waves (Fig. 3A). No periodic lateralizing epileptiform discharges were noted. Patient had normal sensorium in between the convulsion episodes except the irritability which gradually increased.

Over the next 1 week, patient seizures increased to 30-90 episodes/day, which was brief and limited to the left hemifacial region with twitching of the eyebrows. Her sensorium worsened with concomitant use of multiple anticonvulsants to control her seizures. Bedside EEG showed continuous epileptiform discharges (Fig. 3B). She required mechanical ventilation in the view of encephalopathy. She received following medications in order: phenobarbitone, midazolam infusion, ketamine infusion, high dose oral topiramate, clobazam and thiopentone infusion. She was also treated with intravenous immunoglobulin 2 g/kg over 4 days followed by three doses of Inj methylprednisolone but with absolutely no response. Burst suppression pattern was achieved after thiopentone was initiated, which was maintained for 48 h by continuous EEG monitoring (Fig. 3C). Patient remained seizure free while on thiopentone with sustained burst suppression pattern. Thiopentone was subsequently tapered in the view of cardiac decompensation and requirement of two vasopressors. Patient showed recurrence of similar hemi-facial seizures with daily frequency of 75-80. Ketogenic diet was introduced for the control of seizures. However it had to be stopped in spite of a partial favourable response after 5 days in view of hypokalemia and paralytic ileus. Lastly, Inj lacosamide was started. Frequency of seizures decreased to 8-10/day. Seizure frequency decreased even further with an increase to high dose lacosamide (15 mg/kg/day). Simultaneously the ketogenic diet was reinitiated at a 4:1 ratio. She however persisted to stay encephalopathic. Despite tapering of midazolam, there was no reversal of encephalopathy. Her Glasgow coma scale remained 3/15 for almost a month and she required mechanical ventilation and vasopressors for 28 days. She also underwent tracheostomy. Frequency of convulsion reduced slowly, and she became seizure free from day 25 of admission. EEG showed diffuse slowing along with frequent intermittent subclinical seizures in addition to multifocal bilateral epilepticform discharges, predominantly over the right fronto-temporal region (Fig. 3D). The EEG abnormalities slowly decreased over days to weeks. Repeat MRI showed soft hyperintensities in previous left temporal region, with focal areas of hypoperfusion in the left parietal cortex possibly due to hypotension.

After 6 weeks of illness, we noted a slow reversal of encephalopathy. She had two episodes of breakthrough seizures of similar nature precipitated by fever which was controlled by intravenous anticonvulsants and strict ketogenic diet. At 10 weeks, when discharged, she had an improved cognitive state, started spontaneous relevant speech; power improved to more than 3 in all limbs, was able to walk with

support, feed herself and had complete bladder bowel control. At discharge she remained on five oral anticonvulsants and the ketogenic diet (4:1).

At 1-year follow-up, she gets mild focal seizures 1-2/month, especially when we are trying to taper her AED'S. We had to taper and stop the diet after 3 months, as she could not comply with it once she started going to school. She is currently still on 3 AED'S with a lot of difficulty. She was able to walk after undergoing regular physiotherapy. She has started schooling but has considerable behavioural issues both at school and home.

3. Discussion

FIRES is a clinical diagnosis based on its characteristic presentation and investigations findings. The index case presented with a non-specific low-grade fever and after an interval of 3 days developed multiple seizures, which progressed to status epilepticus and encephalopathy. These seizures were classically facio-brachial associated with facial myoclonus. Convulsions were refractory to all possible treatments except thiopentone which achieved burst suppression pattern. However on tapering the thiopentone the seizures recurred and eventually settled with intravenous lacosamide and ketogenic diet. This case is similar to case series reported in literature with different nomenclatures.³⁻⁸

In 2003, Baxter et al. reported a case series of six children with diagnosis of Idiopathic catastrophic epileptic encephalopathy.⁴ Wilder-smith published case series of seven adult patients with a condition described as New onset refractory status epilepticus (NORSE).⁵ All the patients had poor outcome. In 2006, Mikaeloff et al. described a similar entity as Devastating epileptic encephalopathy in school-aged children (DESC) in 14 children with median age of 7.5 years. The seizures were precipitated by a non-specific febrile event with a median lag of 4 days. Seizures were refractory to all treatment except thiopentone. All patients survived the event but had significant neuro-cognitive sequelae and persistent seizures.⁶ In 2009, Sukama et al. coined the term acute encephalitis with refractory, repetitive partial seizures (AERPS) and also laid the diagnostic criteria.⁷ In 2010, Baalen et al. described similar condition in 22 children as Febrile infection-related epilepsy syndrome (FIRES).⁸ All the above centres reported similar cases involving acute refractory status, in young school-going children, with all known etiologies being ruled out. They all had prolonged courses, with a poor outcome. Currently the most accepted term is Febrile Illness Related Epileptic Syndrome coined by Nabout et al.⁹

FIRES is a clinical diagnosis and diagnosis of exclusion. The median age of presentation is 8 years (2-17 years). Seizures are generally partial and the frequency can be high as 100/day. Most patients have characteristic semiology of facial or peribuccal myoclonic fits as seen in our case. CSF examination reveals fewer than 10 cells/mm³, while other metabolic, autoimmune, infectious panel are found to be normal as documented in this case. EEG in these patients shows slow background during the acute phase and multifocal spikes during the chronic phase. MRI is generally normal but in some patients, hyperintensities are noted in the hippocampi as

noted in our case. Our case fulfilled all the diagnostic criteria given by Sukama et al.⁷

The etio-pathogenesis of FIRES is poorly understood. As the condition is precipitated by fever, an infection-triggered process may be responsible. Infectious disease or autoimmunity is less likely as the relevant investigations are usually negative.¹⁰

The disease course is characterized by refractory status epilepticus with requirement of thiopentone induced coma in most of the cases. The seizures in our patient were uncontrolled on six anticonvulsants. We used thiopentone to achieve burst suppression pattern. Use of thiopentone was associated with circulatory dysfunction requiring multiple vasopressors precluding its use for a long duration. During withdrawal of thiopentone, we used a new anticonvulsant, IV lacosamide as ketogenic diet was stopped in view of paralytic ileus. We found it possibly effective in controlling the seizures. Lacosamide is a functionalized amino acid with anticonvulsant properties. It acts by enhancing the slow inactivation of sodium channels. Lacosamide has been used as an adjunctive therapy in paediatric patients with refractory focal epilepsy.¹¹⁻¹³ The usual maintenance dose used in children is 5-12.5 mg/kg/day. We started lacosamide in a dose of 10 mg/kg/day but increased to 15 mg/kg/day to control the seizures. No adverse events were noted at this higher dose. Despite initial failure of introducing ketogenic diet, we were successful in introducing it later. We found ketogenic diet possibly effective in preventing breakthrough seizures, though it cannot be stated with certainty as multiple anticonvulsants were ongoing. This is similar to observations made by Nabbout et al.¹⁴

The overall outcome of the disease is poor as refractory epilepsy persists in the survivors.¹⁰ FIRES is noted to be associated with persistent epilepsy, other neurological disorders like attention deficit disorder, learning disabilities, borderline cognitive level, mild to severe mental retardation and occasionally vegetative state.¹⁰ After 1 year, our patient still has drug resistant epilepsy as well as significant behavioural and cognitive issues.

Conflicts of interest

All authors have none to declare.

REFERENCES

1. Karmarkar SA, Aneja S, Khare S, Saini A, Seth A, Chauhan BK. A study of acute febrile encephalopathy with special reference to viral etiology. *Indian J Pediatr.* 2008;75:801-805.
2. Ismail FY, Kossoff EH. AERRPS, DESC, NORSE, FIRES: multi-labeling or distinct epileptic entities? *Epilepsia.* 2011;52:e185-e189.
3. Nabbout R. FIRES and IHHE: Delineation of the syndromes. *Epilepsia.* 2013;54 Suppl:54-56.
4. Baxter P, Clarke A, Cross H, et al. Idiopathic catastrophic epileptic encephalopathy presenting with acute onset intractable status. *Seizure.* 2003;12:379-387.
5. Wilder-Smith EP, Lim EC, Teoh HL, et al. The NORSE (new-onset refractory status epilepticus) syndrome: defining a disease entity. *Ann Acad Med Singapore.* 2005;34:417-420.
6. Mikaeloff Y, Jambaqué I, Hertz-Pannier L, et al. Devastating epileptic encephalopathy in school-aged children (DESC): a pseudo encephalitis. *Epilepsy Res.* 2006;69:67-79.
7. Sakuma H, Awaya Y, Shiomi M, et al. Acute encephalitis with refractory, repetitive partial seizures (AERRPS): a peculiar form of childhood encephalitis. *Acta Neurol Scand.* 2010;121:251-256.
8. Van Baalen A, Häusler M, Boor R, et al. Febrile infection-related epilepsy syndrome (FIRES): a nonencephalitic encephalopathy in childhood. *Epilepsia.* 2010;51:1323-1328.
9. Kramer U, Chi CS, Lin KL, et al. Febrile infection-related epilepsy syndrome (FIRES): pathogenesis, treatment, and outcome: a multicenter study on 77 children. *Epilepsia.* 2011;52:1956-1965.
10. Nabbout R, Vezzani A, Dulac O, Chiron C. Acute encephalopathy with inflammation mediated status epilepticus. *Lancet Neurol.* 2011;10:99-108.
11. Kim JS, Kim H, Lim BC, et al. Lacosamide as an adjunctive therapy in pediatric patients with refractory focal epilepsy. *Brain Dev.* 2014;36:510-515.
12. Yorns Jr WR, Khurana DS, Carvalho KS, Hardison HH, Legido A, Valencia I. Efficacy of lacosamide as adjunctive therapy in children with refractory epilepsy. *J Child Neurol.* 2014;29:23-27.
13. Grosso S, Parisi P, Spalice A, Verrotti A, Balestri P. Efficacy and safety of lacosamide in infants and young children with refractory focal epilepsy. *Eur J Paediatr Neurol.* 2014;18:55-59.
14. Nabbout R, Mazzuca M, Hubert P, et al. Efficacy of ketogenic diet in severe refractory status epilepticus initiating fever induced refractory epileptic encephalopathy in school age children (FIRES). *Epilepsia.* 2010;51:2033-2037.