

Spontaneous relocation of intracranial bullet

Aditya P Misra MD, A Gupta M Ch, R Awasthi MS

Departments of Radiodiagnosis and Neurosurgery,
Rama Medical College, Mandhana, Kanpur (Uttar Pradesh).

INTRODUCTION

With continuously increasing episodes of violence around the world the frequency of firearm injuries involving the brain are on an ever increasing trend¹. Bullet injuries to head need special attention in view of requirement of prompt decisions regarding surgical removal. The neurological status at time of presentation and the location of the bullet often dictates the decision regarding surgical removal. However an important though uncommon complication of retained bullet is that of spontaneous relocation. We report a case of spontaneous relocation of bullet injury and review the relevant literature.

CASE REPORT

A 22-year-old male presented with alleged firearm injury to the head. There was a single stitched entry wound in the right temporal region. GCS of the patient at time admission was E4V5M6. There was no neurological deficit. Pupils were equal, reacting and vitals were stable.

CT brain was done. Scout film showed bullet in frontal region (Fig 1). On axial sections, the bullet was seen in right frontal region and small hematoma along with bony fragment was also noticed in the right frontal lobe (Fig 2). Fracture could be seen at site of entry in the greater wing of sphenoid & adjacent skull base on right side. The entry wound was debrided and stitched. Patient was treated conservatively with antibiotics, antiepileptics and anti edema measures, and was planned for surgery.

At the beginning of surgery, C –arm fluoroscopy was done to confirm the position of the bullet. The bullet was found to be migrated to occipital region. The patient was shifted for CT scan, scout film showed bullet in occipital region (Fig. 3). Axial images revealed relocation

of the bullet to the postero-basal part of the right occipital lobe just above the tentorium. (Fig. 4). Orientation of the bullet was same after migration. Additional contusion was seen near frontal horn of right lateral ventricle, indicating possible migration through right lateral ventricle. However, GCS of the patient remained unchanged.

Fig 1

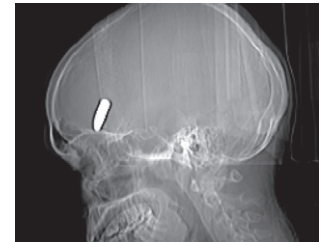


Fig 2

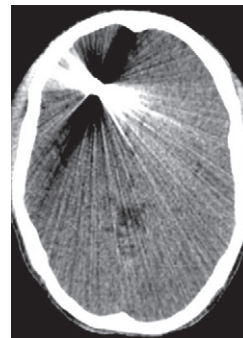
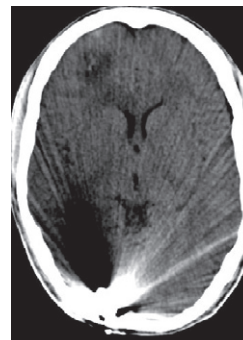


Fig 3

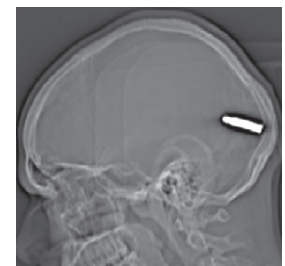

Fig 4



Address for correspondence:

Dr Aditya Prakash Misra
2A/43, Azad Nagar, Kanpur 208002 (U.P.)
Tel : 091-5122560316, Mob : 0919839188620
Fax : 091-51222583875
Email : saggimishra@rediffmail.com

Parieto-occipital craniotomy was done. Intra-operatively direct vision and palpation was possible. The bullet was safely removed and post operative course was uneventful. No neurological deficit was seen due to surgery.

DISCUSSION

Firearm injuries have become much more common with ready availability of the firearms in the society. The management of these injuries needs to be studied in detail in order to intervene during the course of the treatment at the right moment. The cases need to be treated on individual basis with few basic guidelines. Most of the decisions are dependent upon the course of the recovery within the hospital. Removal of the bullet should be done for patients undergoing surgery for wound debridement or evacuation of intra or extra axial fluid collection provided the bullet is in the vicinity and easily accessible and removal of which should not lead to further deterioration in the neurological status due to its proximity to vital structures². Secondary sequelae such as abscess formation, ventriculitis, focal seizures or migration are further indications warranting surgical intervention.

Spontaneous relocation of the projectile in the cerebral parenchyma is an uncommon complication of bullet injuries. Vilvandre and Morgan were the first to demonstrate the movement of intracranial metallic foreign bodies radiographically in two patient³. Various theories have been put forward regarding the same. Gravitational factor has been suggested to be a cause for the caudal migration especially in the absence of significant cranial swelling and minimal increase in intracranial pressure⁴. Cerebral softening has also been mentioned as a cause which permits the migration. Some authors have suggested the ventricular system to be the ferry for transportation of the bullet from one area of the brain to the other⁵. Early migration may occur with brain laceration or cavitation or a location near - or in the ventricle or subdural space⁶.

Rengachary et al described spontaneous posterior migration of the bullet to more dependent position⁷. Interestingly enough, the orientation of the bullet remained unchanged. G. Alessi et al have described spontaneous version and anterior migration of the bullet again with the orientation of the bullet remaining unchanged⁸. Ross D et al have reported two cases of spontaneous migration of retained bullets⁹. Both these

patients showed neurological deterioration and CT scans revealed migration of the bullets. The patients underwent immediate surgical removal of the bullet following which the patients demonstrated significant functional recovery.

In our case bullet relocation was evident on third day after injury when it was seen lying in the postero-basal part of the right occipital lobe just above the tentorium as compared to previous posterior frontal location with orientation of the bullet being unchanged. The contused cerebrum adjacent to frontal horn of right lateral ventricle was suggestive of the possible transventricular migration of the bullet. Hence in our case gravity were probably responsible for the bullet migration.

Surgical treatment of bullet injuries needs to be decided on individual basis with intraoperative localization being essential. Spontaneous relocation though uncommon should be watched for as it may be responsible for damage to vital structures producing significant neurological damage. The presence of migration should be considered to be an urgent indication for surgical intervention.

REFERENCES

1. Karabagali Hakan. Spontaneous movements of bullets in the interhemispheric region. *Ped Neurosurg*; 41:148-50.
2. Hammon WM. Analysis of 2187 consecutive penetrating wounds of the brain. *J Neurosurg* 1971; 34:142-4.
3. Vilvandre G, Morgan JD. Movements of foreign bodies in the brain. *Arch Radiol Electrother* 1916;21:22-7.
4. Rappl G, Arce CA, McKenzie R. Incidence of intracranial bullet fragment migration. *Neuro Res* 1999; 21:475-80.
5. Salvati M, Cervoni L, Rocchi G, Rastelli E, Delfini R. Spontaneous movement of metallic foreign bodies. *J Neurosurg Sci* 1997; 41:423-5.
6. Brown LJ. Unusual pneumoencephalogram following fragment wound of the brain. *J Neurosurg* 1970; 32:100-2.
7. Rengachary SS, Carey M, Templer J. The sinking bullet. *Neurosurgery* 1992; 30:291-5.
8. G Alessi, S Aiyer, N Nathoo. Home made gun injury: spontaneous version and anterior migration of bullet. *Br J Neurosurg* 2002; 16:381-4.
9. Ross D, Zafonte DO, Thomas Watanabe, Nancy R. Mann. Moving bullet syndrome: A complication of penetrating head injury. *Arch Phys Med Rehab* 1998; 79: 1469-72.