

## Unusually delayed posttraumatic CSF rhinorrhoea

KVLN Rao M Ch, Dhaval Shukla M Ch, B Indira Devi M Ch

Department of Neurosurgery, NIMHANS, Bangalore, Karnataka

**Abstract:** Cerebrospinal fluid (CSF) rhinorrhoea is not uncommon after traumatic brain injury. It usually occurs within first two days of trauma and subsides spontaneously. Delayed leak beyond three months of trauma is rare. We describe a case of posttraumatic CSF rhinorrhoea which presented 44 years after injury.

**Keywords:** CSF leak; meningitis; trauma

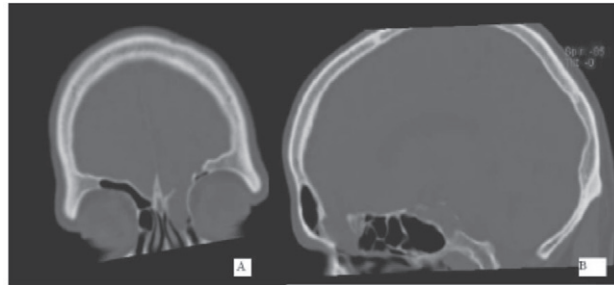
### INTRODUCTION

Cerebrospinal fluid (CSF) leak after traumatic brain injury (TBI) is not an uncommon phenomenon. CSF rhinorrhoea is usually apparent during the first 48 hours in two third of cases after TBI. In the remaining cases it is evident within 3 months. However in exceptional cases, CSF rhinorrhoea does not appear even decades after TBI. Such patients often present with recurrent meningitis and a CSF leak is detected during the work up for the cause of recurrent meningitis<sup>1</sup>. The following report describes a case of delayed CSF rhinorrhoea.

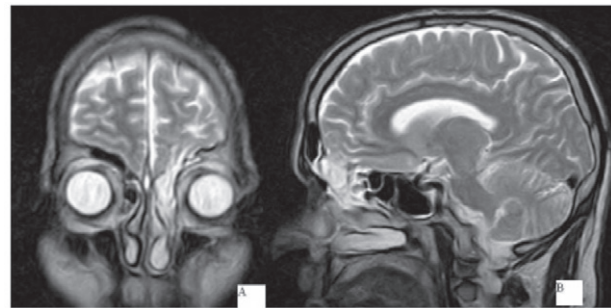
### CASE REPORT

A 57 years old gentleman was referred to us for evaluation and treatment of clear water discharge from left nostril of one year duration. He had suffered three bouts of meningitis one year back, and was treated in a different hospital. He did not have CSF rhinorrhoea during any of these episodes. After treatment of third episode of meningitis, he developed CSF leak from left nostril. The leak was exacerbated on lying down on left side and on sitting. He recollected that he had sustained head injury at age of 12 years (44 years before onset of CSF rhinorrhoea), when he had fallen down from a tree and sustained a laceration on left side of his forehead. The scalp laceration was sutured primarily. There was bleeding from nose but he does not remember whether a clear fluid was also leaking from nose at that time. He remained conscious and was not hospitalized and hence he thought this accident as a minor event in his life which he had almost forgotten, and was not revealed to

previous physician who had treated him for recurrent meningitis. He never had CSF rhinorrhoea during these 44 years. General examination revealed a small scar on left side of forehead. Besides anosmia on left side there were no neurological deficits. Clinically CSF rhinorrhoea could not be demonstrated. Routine haematological and biochemical investigation were normal. CT scan of head with coronal and axial reconstruction revealed a well demarcated bone defect in the floor of the anterior cranial fossa at the level of anterior ethmoidal cells on left side. (Fig 1). MRI of brain revealed the same defect with herniation of leptomeninges and thin gliotic tissue in the nasal cavity (Fig 2). The clinical and radiological diagnosis was post traumatic CSF rhinorrhoea due to



**Fig 1:** CT scan of head coronal (A) and sagittal (B) reconstruction, bone windows showing a bone defect in ACF base at level of anterior ethmoids.



**Fig 2:** MRI of brain T2W, coronal (A) and sagittal (B) acquisition, showing herniating arachnoid and CSF from ACF base to anterior ethmoids and nasal cavity.

#### Address for correspondence:

Dr. B Indira Devi, Professor

Department of Neurosurgery, National Institute of Mental Health and Neurosciences (NIMHANS), Bangalore 560029, Karnataka

Phone: 0091 080 26995409 Fax : 0091 080 26631830

Email: bidevi@gmail.com

defect in the anterior cranial fossa (ACF) base at ethmoidal cells. A bifrontal craniotomy and intradural repair of CSF fistula was done. On retracting the left frontal lobe a thin gliotic tissue and arachnoid was seen going through the bone defect. The gliotic tissue and arachnoid was resected and a bone defect 3.5 X 1.5 cms was found in the ACF base at the region of anterior ethmoidal cell. The margins of the defect were smooth. The defect was sealed with a piece of temporalis muscle and a bone graft harvested from inner table of frontal bone. The base of ACF was covered with fascia lata. A lumbar drain was inserted after surgery and CSF was drained for 5 days. Two months after surgery he presented again with headaches without fever. An MRI of brain showed bilateral chronic subdural haematomas. There was no CSF leak from the repaired site. Chronic subdural hematomas were evacuated by burr holes. At follow up, four months after surgery, he was asymptomatic.

### DISCUSSION

Post traumatic CSF leak often subsides spontaneously. The mechanism of natural healing is sealing by blood clot, inflammation, or brain tissue herniation. The probability of spontaneous closure in case of CSF otorrhoea is higher than rhinorrhoea. Such natural healing mechanisms are not perfect and patients may present again with CSF leak in first few months. The mechanisms of leak within few months are resolution of oedema, absorption of blood clot, contracture of scar, and necrosis of soft tissues or bone. The incidence of delayed CSF leak beyond 3 months is 5%, whereas delay beyond a year is very rare<sup>2</sup>. If CSF does not leak within months of TBI, the event is often forgotten till patients

get recurrent meningitis several years later. Delayed CSF rhinorrhoea is reported even 48 years after initial trauma<sup>3</sup>. The possible mechanisms of appearance or reappearance of CSF leak in such delayed cases is raised intracranial pressure, another trauma, growing skull fracture, and ascending infections. None of these causes were responsible in our case. The probable mechanism in our case is atrophy of the brain resulting in retraction of herniated brain tissue leading to opening of fistula. It is difficult to prove whether the defect of the bone was large at the time of initial trauma or it has increased over years due to mechanism similar to that of growing skull fracture in our case. In the reported cases of delayed leaks after trauma herniating brain through the defect was found. This herniation was responsible for initial cessation of CSF leak and later for maintaining the bone defect by interfering with healing<sup>1</sup>.

In any patient who presents with recurrent meningitis a history of TBI, howsoever minor or remote, should be sought and should be investigated for CSF fistula.

### REFERENCES

1. Okada J, Tsuda T, Takasugi S, Nishida K, Tóth Z, Matsumoto K. Unusually late onset of cerebrospinal fluid rhinorrhoea after head trauma. *Surg Neurol* 1991; 35:213-7.
2. Talamonti G, Fontana RA, Versari PP, et al. Delayed complications of ethmoid fractures: a "growing fracture" phenomenon. *Acta Neurochir (Wien)* 1995; 137:164-73.
3. B. Schick B, Weber R, Kahle G, Draf W, Lackmann GM. Late manifestation of traumatic lesions of skull base. *Skull Base Surgery* 1997; 7:77-83.