

Posterior circulation stroke following mild head injury

SGS Datta M Ch

Department of Neurosurgery
Command Hospital (Northern Command), C/o 56 APO

Abstract: A young soldier sustained clinically mild head injury. He developed complication 24 hrs after head injury in the form of left cerebellar infarct with acute hydrocephalus. In spite of best efforts to resuscitate the patient and to relieve the raised intra cranial pressure, he succumbed to his complications. The case report highlights posterior circulation stroke as a rare complication of mild head injury.

Keywords: mild head injury, posterior circulation stroke

INTRODUCTION

Traumatic vascular lesions can occur after severe or even the mildest forms of head and cervical trauma¹. The initial evaluation of the injured patient must be thorough and the clinical suspicion of vascular injury must be highly suspected based on the mechanism of injury. A case of posterior circulation stroke presenting 24 hrs after a mild head injury is presented.

CASE REPORT

A 32-year-old serving soldier sustained head injury in a road traffic accident on 02 Sep 2007, and had brief loss of consciousness and one episode of vomiting after the injury. He recovered well and was asymptomatic, when admitted for observation. Primary survey at the referring hospital revealed a patient with minimal head injury, with stable vital parameters. His GCS was 15 / 15; he was alert & had no neurological deficits. He had a lacerated wound forearm with suspected tendon injuries. The wound was explored on 02 Sep 07 under local anesthesia and primary repair was done. Chest and neck radiographs were normal. He was admitted and closely monitored.

On 03 Sep 07, at 0830 hrs, he complained of severe suboccipital headache followed by two episodes of vomiting. Neurologically he still remained alert and well oriented. The treating surgeon discussed the case on telephone and possibility of a post-traumatic delayed expanding posterior fossa hematoma was considered.

Address for correspondence:

Wg Cdr SGS Datta
Gd Spl (Surgery) & Neurosurgeon
CH (NC), C/o 56 APO
Tele: 0-9906000580, email: sgs1datta@rediffmail.com

He was advised to immediately evacuate the patient to the referral hospital for NCCT head & further management by the neurosurgeon. While waiting for air evacuation, he deteriorated precipitously – he had an episode of decerebrate posturing, with post ictal GCS of E1 M1 V1, with poor respiratory effort necessitating intubation and ventilation. Pupils were equal & reactive, and there were no localizing signs. He was stabilized and air evacuated on ventilatory support to our centre. The patient suffered two cardiac arrests en route in the helicopter and was revived by the accompanying medical officer.

He reached our centre on 03 Sep 07 at 1800 hrs. Initial evaluation showed the patient was still in circulatory collapse with pulse not recordable and systolic blood pressure at 50 mm Hg, GCS of E1 M1 VT, with fixed, dilated pupils. Resuscitation, ventilation was continued & inotropic support was instituted. Urgent NCCT head showed a large left cerebellar infarct with acute hydrocephalus (Fig 1). He was directly rushed to the OT and emergency left frontal external ventricular drain (EVD) was placed. CSF was under high pressure & clear. Following placement of EVD, his vitals improved (pulse - 100 / min, BP - 110 / 70 mmHg) but neurologically he did not show any improvement. He was closely monitored and maintained on ventilator & inotropic support. Anti cerebral edema measures were instituted. Plan was to watch for hemodynamic stabilization before any attempt at decompressing the posterior fossa.

He remained in poor neurologic status on 04 Sep 07. There was minimal CSF drainage in the EVD (50 cc). Repeat scan showed well placed ventricular catheter, and the ventricles were fully collapsed (slit like), and severe cerebral edema (Fig 2).

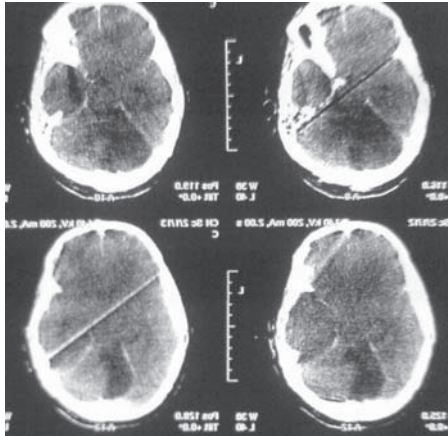


Fig 1: NCCT head showing large left cerebellar infarct.

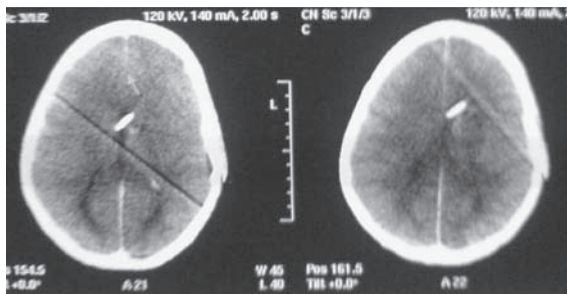


Fig 2: NCCT head showing left frontal external ventricular drain in position with completely collapsed ventricles

In view of his poor general & neurologic status, decompressive surgery was deferred. Shortly after, he had another episode of cardio respiratory arrest at 1130 hrs from which he could not be revived.

DISCUSSION

Posterior circulation territory stroke following mild head injury is a known entity although rarely seen. Numerous case reports appear in literature from time to time highlighting this complication^{2,3,4}. Possible consequences of blunt trauma to the head and neck include injury to the vertebrobasilar system in the form of angiorrhesis, subintimal, intramural and perivascular hemorrhage leading to a partial narrowing of the injured vessel. These processes can be complicated by progressive thrombosis & vascular occlusion^{5,6,10}. Neck vessel injury is probably an under diagnosed complication of head or cervical spine trauma. In one series of 57 patients without clinical

signs suggestive of neck vessel trauma, sonography revealed abnormalities in 3 patients (11%) with head injury and in 6 patients (20%) with cervical spine or combined head and spine injury, in both groups mainly related to the vertebrobasilar system⁷. MRI & MRA helps demonstrate the vascular pathology in these cases^{8,10}. The commonest site of vertebral artery dissection seems to occur at C1-C2⁹. A high index of suspicion followed by early recognition of these complications is absolutely essential to prevent poor outcomes.

REFERENCES

1. Guyot LL, Kazmierczak CD, Diaz FG. Vascular injury in neurotrauma. *Neurol Res* 2001; 23:291-6.
2. Murase S, Ohe N, Nokura H, Miwa Y, Ohkuma A. Vertebral artery injury following mild neck trauma: report of two cases. *Neurologic Surgery (Japan)* 1994; 22: 671-6.
3. Della Corte F, Caricato A, Pennisi Mariano A, Pappalardo E, Piazza O, Rollo M. Injury of the vertebral artery after closed head trauma. *Euro J Emerg Med* 1999; 6: 255-8.
4. Sprogøe-Jakobsen S, Falk E. Fatal thrombosis of the basilar artery due to a minor head injury. *Forensic Sci Int* 1990; 45: 239-45.
5. Iwase H, Kobayashi M, Kurata A, Inoue S. Clinically unidentified dissection of vertebral artery as a cause of cerebellar infarction. *Stroke* 2001; 32: 1422-4.
6. Pötsch L, Bohl J. Traumatic lesion of the extra cranial vertebral artery—a note-worthy potentially lethal injury. *Int J Legal Med* 1994; 107: 99-107.
7. Rommel O, Niedeggen A, Tegenthoff M, Kiwitt P, Bötel U, Malin J. Carotid and vertebral artery injury following severe head or cervical spine trauma. *Cerebrovasc Dis* 1999; 9: 202-9.
8. Duval EL, Van Coster R, Verstraeten K. Acute traumatic stroke: a case of bow hunter's stroke in a child. *Eur J Emerg Med* 1998; 5: 259-63.
9. Kim SH, Kosnik E, Madden C, Rusin J, Wack D, Bartkowski H. Cerebellar infarction from a traumatic vertebral artery dissection in a child. *Pediatr Neurosurg* 1997; 27: 71-7.
10. Bhatoo HS, Bakshi SS. Traumatic posterior inferior cerebellar artery infarction. *Ind J Neurotrauma* 2004; 1: 69-71