

Piracetam in postconcussion syndrome: preliminary results of a randomized study using SPECT

Deepak Agrawal M Ch, NK Gowda MD*

Departments of *Nuclear medicine and Neurosurgery
All India Institute of Medical Sciences, New Delhi-110029, India

Abstract: Aim of this study was to study the changes in regional cerebral perfusion following administration of the drug piracetam using single photon emission computed tomography (SPECT) in patients with postconcussion syndrome (PCS). Twenty consecutive male patients 18-65 years of age, with mild traumatic brain injury and PCS who had a normal initial CT head but an abnormal SPECT scan (carried out within 72 hours of the injury), were included in the study. Patients were randomized to either receive a daily dose of 2.4g of piracetam for six weeks (n=10) (piracetam group), or no piracetam (n=10) (control group). A repeat SPECT scan was performed at six weeks of follow up and any subjective improvement in symptoms (if any) noted. While the pre-treatment mean ratio for the piracetam treated group (0.86) and controls (0.85) did not differ significantly ($p = 0.304$; 95% CI -0.041, .0136), there was a significant rise in the post treatment ratio in the piracetam group (mean: 0.959) as compared to the controls (mean: 0.882) ($p < 0.001$; 95% CI -.0114, -0.038). Nine patients (90%) also had improvement in their symptoms of PCS, compared to only three patients in the test group (Fisher exact test; 2 tailed: $p=0.01$). Our study suggests that the cerebral perfusion defects seen on SPECT imaging may per se be responsible for the clinical manifestations of PCS. Low-dose piracetam appears to improve regional cerebral blood flow and reverse perfusion abnormalities in these patients. This study paves the way for further randomized, placebo controlled trials with piracetam for more definitive results.

Keywords: closed head injury, concussion, cerebral perfusion, mild traumatic brain injury, neuroprotective agents, post concussion syndrome, piracetam, SPECT

INTRODUCTION

Up to 60% of patients with minor traumatic brain injury (MTBI) will suffer from post concussion syndrome (PCS) characterized by persistence of symptoms such as headache, fatigue, memory difficulties and emotional lability. These symptoms of which can prove to be very distressing to such patients and despite new insights gained into the pathophysiology of mild traumatic brain injury and the realization that there may be profound brain perfusion abnormalities existing behind a seemingly normal CT head of such 'minor' head injury patients with postconcussion syndrome, most neurosurgeons can do little except giving reassurance and prescribing analgesics and anti-vertigo medication.

Piracetam, a cyclic derivative of GABA is known to have anti-ischemic properties, and has been shown to reverse perfusion abnormalities in cases of stroke and

dementia¹, as well decrease the amount of cellular loss induced by focal ischemic injury². Although it has been used in postconcussion syndrome for more than 25 years³, it has not gained acceptance due to lack of objective evidence of benefits in this condition. Previous studies have relied on subjective criteria such as symptoms for assessing its benefits³, and its therapeutic efficacy in postconcussion syndrome using more scientific methods has not been yet studied. This study was designed to look for cerebral perfusion changes on serial SPECT imaging in patients with postconcussion syndrome, and correlate it with symptomatic improvement (if any) following administration of piracetam.

MATERIALS AND METHODS

This study was carried out prospectively in the departments of neurosurgery and nuclear medicine in our institution over a twelve-month period. Ethical clearance was obtained from the institute's ethics committee and the study was performed under approval of the research review board of the institute. Only male patients who were greater than 18 years and less than 65 years of age were considered for the study. All patients who were included in this study agreed to participate

Address for Correspondence:

Dr Deepak Agrawal,
Assistant Professor
Department of Neurosurgery & Gamma Knife,
Neuroscience Centre, All India Institute of Medical Sciences,
New Delhi, India-110029

and informed consent was taken from all. Patients were defined as having mild traumatic brain injury according to the criteria published by the members of the Mild Traumatic brain injury Interdisciplinary Special Interest Group (BISIG) of the American Congress of Rehabilitation Medicine⁴, which states that in MTBI:

1. Loss of consciousness should not exceed 30 minutes.
2. After 30 minutes the initial GCS score should be between 13 and 15.
3. Posttraumatic amnesia should not exceed 24 hours.

Patients with MTBI were admitted in the department of neurosurgery and underwent a non-contrast scan (NCCT) of the head as well as single photon emission computed tomography (SPECT) scan of the brain within 72 hours of the injury. Patients having any parenchymal injury on the CT scan were excluded from the study. Detailed history and examination findings were recorded and patients with previous history of concussion or head injury, or an associated medical disorder were excluded from the study.

Postconcussion syndrome

To assist with the diagnosis of PPCS, World health Organization published a set of guidelines and defined PCS is defined as “. . . history of head trauma with loss of consciousness [that] precedes symptom onset by a maximum of four weeks with three or more symptoms of the following: headache, dizziness, malaise, fatigue, noise intolerance; irritability, depression, anxiety, emotional lability; subjective concentration, memory, or intellectual difficulties without neuropsychological evidence of marked impairment; insomnia; reduced alcohol tolerance; and preoccupation with above symptoms and fear of brain damage without hypochondriacal concern and adoption of sick role”⁵.

Amongst these patients of mild traumatic brain injury, twenty consecutive patients who had postconcussion syndrome *and* an abnormal SPECT scan only were further considered for this study. Those patients who had symptoms of postconcussion syndrome but a normal brain SPECT were excluded from the study. The included subjects were randomly allocated into two groups using computer generated random numbers into a test group (n=10) and control group (n=10). In both the groups patients were again evaluated for the presence of features of postconcussion syndrome at the end of six weeks of follow up.

Piracetam treated group

Subjects received a total daily dose of 2.4 g of piracetam (Cerecetam[®], Intas Pharmaceuticals Ltd., Ahmedabad, India) orally, divided in three equal doses for a period of six weeks. A repeat SPECT scan was done at the end of this period.

Control Group

Subjects in this group were not given piracetam and underwent SPECT scan similarly within 72 hours of admission and at the end of six weeks of follow up.

SPECT

SPECT was done on a dual headed rotating scintillation gamma camera (Elscint, Varicam), 30-90 minutes after injection of 15-25 mCi (10 MBq /kg) of 99m-Tc-ECD intravenously in a silent room with eyes open. Acquisition was done using 128 X 128 matrix, 360--^o, 120 projections, 60 projection per head, 25 seconds per projection, using low energy ultrahigh resolution fan beam collimator or low energy high resolution parallel hole collimator. Transaxial (oriented in frontocerebellar plane), coronal and sagittal slices with an image resolution of 1 cm were reconstructed using Butterworth filter, Nyquist(cyc/cm) of 1.404, and cutoff frequency of 0.56. Chang attenuation correction of 0.11cm⁻¹ was applied. Final data was displayed on a 10 grade color scale and semiquantitative analysis of the data done using semiautomatic brain quantification programs (Xpertpro, Entegra with Neurogam). Circular region of interest (ROI) with a radius of 9.1mm (6 pels) in the basal ganglia, thalamus, temporal lobe, visual cortex and brain stem were used. ROI with radius of 11.2 mm (7 pels) were used in frontal, parietal, occipital and cerebellar lobes. Side-to-side difference of radiotracer uptake (counts) more than 10% between the regions of interest was taken as a significant for reduced perfusion. If both the lobes were affected, the cerebellum was considered as the reference. This method is within the guidelines of Society of Nuclear Medicine.

The relative improvement in the cerebral perfusion was calculated by comparing the ratio of the average counts in affected and unaffected lobe, in the initial SPECT with that done at six weeks of follow up. Data was analyzed using statistical software ‘Epi Info 2000 ver 1.1.2’

RESULTS

The control group was found matching with the piracetam treated group in age and sex (Table 1 & Table 2). While the pre-treatment ratio for the piracetam treated group (mean: 0.86) and controls (mean: 0.85) did not differ significantly ($p = 0.304$; 95% CI -0.041, .0136), there was a significant rise in the post treatment ratio in the piracetam treated group (mean: 0.959), as compared to the controls (mean: 0.882) ($p = <0.001$; 95% CI - .0114, -0.038) (Fig 1A&B). Clinically too, on assessing for postconcussion syndrome, nine patients (90%) in the piracetam treated group had complete resolution of their symptoms on follow up, compared to only three patients in the control group having relief from postconcussion syndrome, and this was also statistically significant (Fisher exact test; 2 tailed: $p=0.01$).

Table 1: Piracetam treated group showing the ratio of the radiotracer count between the uninvolved and the involved lobe, within 72 hours (baseline) and after six weeks of treatment with piracetam.

PIRACETAM TREATED GROUP					
Patient	Age	Involved lobe	Baseline ratio	Ratio at six weeks	Symptoms
1	25	Lt Temporal	0.812121	0.972222	Improved
2	25	Rt Temporal	0.880952	0.96	Improved
3	26	Rt Temporal	0.9	0.972028	Improved
4	23	Rt Temporal	0.886076	0.954955	Improved
5	35	Lt Temporal	0.888158	0.96063	Improved
6	25	Rt Frontal	0.827586	0.935484	Improved
7	30	Rt Temporal	0.857143	0.969325	Improved
8	27	Lt Frontal	0.868132	0.957317	Improved
9	32	Lt Temporal	0.88	0.949153	Same
10	29	Lt Temporal	0.851064	0.961538	Improved

Table 2: Control group showing the ratio of the radiotracer count between the uninvolved and the involved lobe, within 72 hours (baseline) and after six weeks of head injury. The change in symptoms is also given for each patient.

CONTROL GROUP					
Patient	Age	Involved lobe	Baseline ratio	Ratio at six weeks	Symptoms
1	17	Rt Frontal	0.829787	0.816327	Same
2	26	Rt Temporal	0.869318	0.954315	Improved
3	28	Lt Temporal	0.896104	0.917647	Same
4	26	Lt Frontal	0.822222	0.833333	Same
5	33	Rt Temporal	0.897059	0.916667	Same
6	23	Rt Temporal	0.863636	0.95625	Improved
7	40	Rt Temporal	0.813953	0.829268	Same
8	25	Lt Frontal	0.857143	0.92	Improved
9	32	Rt Temporal	0.820225	0.823529	Same
10	28	Rt Temporal	0.842975	0.857143	Same

DISCUSSION

Postconcussion syndrome can prove to be both chronic and disabling in patients with mild traumatic brain injury, and despite being a common cause of neurological consultation, has remained an enigma to treat. Physicians tend to waive off patients symptoms as purely psychological in nature and a normal radiological picture such as a CT scan only further strengthens this belief.

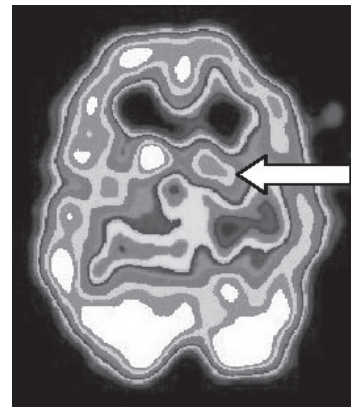


Fig 1A: SPECT scan showing temporal hypoperfusion (white arrow) in a patient with postconcussion syndrome.

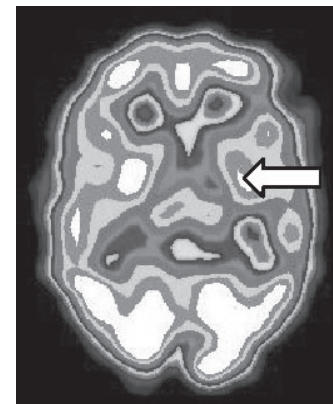

Fig 1B: SPECT scan of the same patient showing improvement in perfusion following six weeks treatment with piracetam.

Nothing however could be further from the truth. As recent research has shown⁵, patients with postconcussion syndrome have neuropathological, neurophysiological and neuropsychological changes overlaid with physical and emotional aspects which can make the management very complex and prolonged.

Various modalities ranging from neuropsychological testing⁶, evoked potential testing⁷, to newer radiological techniques such as PET, SPECT and MRI have been investigated as tools to correlate cerebral dysfunction with postconcussion syndrome symptoms⁸⁻¹⁰. Umile et al. tried to correlate dynamic imaging (PET and SPECT) findings with static imaging (CT and MRI) as well as with neuropsychological testing in 19 patients with minor head injury and postconcussion syndrome, and found that 90% had abnormal findings on PET or SPECT imaging¹¹. Though PET is slightly superior to SPECT in terms of spatial resolution, SPECT is much more affordable and widely available making it attractive as a

cost-effective investigative and diagnostic tool in postconcussion syndrome. In our study SPECT has shown a sensitivity of 80% which is excellent when compared to the abysmally poor sensitivities of 9% for MRI and 46% for CT scan recorded by others^{8,11}. As our own control group shows, perfusion abnormalities do not correct spontaneously over time in a significant number of patients, and changes in cerebral perfusion on SPECT have been found to persist for as long as one year following mild traumatic brain injury¹².

All patients with postconcussion syndrome in our study had temporal or frontal hypoperfusion on brain SPECT and no patient showed hyperperfusion. This finding of areas of hypoperfusion in minor head injury has been described previously¹³⁻¹⁸, and may result from vasospasm, direct vascular injury and perfusion changes due to alterations in remote neuronal activity (diaschisis)¹⁶. There is evidence to show that brain is more vulnerable to ischemic injury after minor head injury¹⁷, and it has been hypothesized that SPECT findings representing hypoperfusion may in fact lead to secondary ischemic injury, clinically manifesting as postconcussion syndrome¹⁶.

Our preliminary results show that piracetam successfully reverses the hypoperfusion successfully in patients with mild traumatic brain injury as compared to the control group and taken in conjunction with the symptomatic improvement, these findings can be considered particularly significant. Piracetam has been shown to reverse perfusion abnormalities in cases of stroke and dementia¹, and has also been tried previously in postconcussion syndrome³. However, it was never accepted for general neurosurgical use due to absence of any objective evidence of its benefits, and this in turn was due to lack of a suitably sensitive investigative modality that could be used for carrying out necessary trials. As our study shows, serial SPECT scanning can provide an ideal platform to test the efficacy of various drugs (including piracetam) in reversing perfusion abnormalities in postconcussion syndrome.

Piracetam, a nootropic agent, has a unique mode of action that though not entirely clear, may be explained by its neuroprotective properties, mediated through effects on the cell membrane¹⁹. Piracetam improves membrane bound cell functions including ATP production and secondary messenger activity^{20,21}. It also has been shown that piracetam has beneficial effects on the cerebral blood flow, by decreasing the adhesivity,

aggregation, and deformability of erythrocytes along with flow thrust tension of the blood²². Various placebo-controlled trials have shown piracetam to improve learning, memory²³, and vertigo^{24,25}. Due to its exceptional benign safety profile, more than 12 g of piracetam has been given as daily dose in acute stroke without significant side effects²⁶. In our study a relatively modest dose of 2.4 g per day was given for six weeks, and even at this dose there was a highly statistically significant improvement in cerebral perfusion in the piracetam treated group. Clinically too, on assessing for postconcussion syndrome, 90% of the patients in the piracetam treated group had complete resolution of their symptoms at six weeks of follow up. This resolution of postconcussion symptoms in the piracetam treated group, when compared to the control group was also found to be statistically significant.

Our study shows that low dose piracetam successfully reverses cerebral perfusion deficits and may result in accelerated symptomatic improvement in patients with postconcussion syndrome. However, as the study number is small, before recommending piracetam for clinical use in postconcussion syndrome, placebo-controlled trials using larger number of patients are required.

CONCLUSIONS

Our results show that cerebral perfusion defects occur in majority of the cases of postconcussion syndrome following mild traumatic brain injury. These perfusion defects per se may be responsible for the clinical manifestations of postconcussion syndrome and this is further borne out by the improvement in regional blood flow and the reversal of perfusion abnormalities on SPECT, along with alleviation of clinical symptoms of postconcussion syndrome, following administration of piracetam. Serial SPECT may, therefore, also serve as a platform for testing the efficacy of various neurobehavioral and pharmacological interventions. This study paves the way for more randomized, placebo controlled trials with piracetam for more definitive results.

Conflict of interest and funding source statement

The study was funded entirely from within the department of neurosurgery and nuclear medicine and none of the authors had any financial and personal relationships with other people or organizations involved in this study. Except for the authors, *no* other person, company or

organization was involved in study design; in the collection, analysis, interpretation of data, writing of the report or in the decision to submit the paper for publication.

REFERENCES

1. Heiss W-D, Ilsen HW, Wagner R, Pawlik G, Wienhard K: Remote functional depression of glucose metabolism in stroke and its alteration by activating drugs. In W-D H, ME P (eds): Positron Emission Tomography of the brain. Berlin Heidelberg, Springer-Verlag, 1983:162-8.
2. Xerri C, Zennou-Azogui Y. Influence of the postlesion environment and chronic piracetam treatment on the organization of the somatotopic map in the rat primary somatosensory cortex after focal cortical injury. *Neuroscience* 2003;118:161.
3. Hakkarainen H, Hakamies L. Piracetam in the treatment of post-concussional syndrome. A double-blind study. *Eur Neurol* 1978;17:50-55.
4. Mild Head Injury Interdisciplinary Special Interest Group of the American Congress of Rehabilitation Medicine: Definition of mild traumatic brain injury. *J Head Trauma Rehabil* 1993;8:86-8.
5. World Health Organization: International Statistical Classification of Diseases and related Health Problems, 10th ed. Geneva, Switzerland. ed 10, Geneva, Switzerland, World Health Organization, 1992.
6. Parker RS, Rosenblum A. IQ loss and emotional dysfunctions after mild head injury incurred in a motor vehicle accident. *J Clin Psychol* 1996;52:32-43.
7. Soustiel JF, Hafner H, Chistyakov AV, Barzilai A, Feinsod M. Trigeminal and auditory evoked responses in minor head injuries and post-concussion syndrome. *Brain Inj* 1995;9:805-13.
8. Kant R, Smith-Seemiller L, Isaac G, Duffy J. Tc-HMPAO SPECT in persistent post-concussion syndrome after mild head injury: comparison with MRI/CT. *Brain Inj* 1997;11:115-24.
9. Nedd K, Sfakianakis G, Ganz W, et al. 99mTc-HMPAO SPECT of the brain in mild to moderate traumatic brain injury patients: compared with CT—a prospective study. *Brain Inj* 1993;7:469-79.
10. Tokutomi T, Hirohata M, Miyagi T, Abe T, Shigemori M. Posttraumatic edema in the corpus callosum shown by MRI. *Acta Neurochir Suppl* 1997;70:80-83.
11. Umile EM, Sandel ME, Alavi A, Terry CM, Plotkin RC. Dynamic imaging in mild traumatic brain injury: support for the theory of medial temporal vulnerability. *Arch Phys Med Rehabil* 2002;83:1506-13.
12. Jacobs A, Put E, Ingels M, Put T, Bossuyt A. One-year follow-up of technetium-99m-HMPAO SPECT in mild head injury. *J Nucl Med* 1996;37:1605-9.
13. Agrawal D, Gowda NK, Bal CS, Pant M, Mahapatra AK. Is medial temporal injury responsible for pediatric postconcussion syndrome? A prospective controlled study with single-photon emission computerized tomography. *J Neurosurg (Pediatrics 2)* 2005;102:167-71.
14. Agrawal D, Gowda NK, Bal CS, Mahapatra AK. Postconcussion syndrome: is the cause central? Correlation with single photon emission computed tomography. *Neurosciences Today* 2003;7:33-6.
15. Arvigo F, Cossu M, Fazio B, et al.. Cerebral blood flow in minor cerebral contusion. *Surg Neurol* 1985;24:211-217.
16. Hofman PA, Stapert SZ, van Kroonenburgh MJ, Jolles J, de Kruijk J, Wilmink JT. MR imaging, single-photon emission CT, and neurocognitive performance after mild traumatic brain injury. *AJNR Am J Neuroradiol* 2001;22:441-9.
17. Jenkins LW, Lu Y, Johnston WE, Lyeth BG, Prough DS. Combined therapy affects outcomes differentially after mild traumatic brain injury and secondary forebrain ischemia in rats. *Brain Res* 1999;817:132-44.
18. Masdeu JC, Van Heertum RL, Kleiman A, et al. Early single-photon emission computed tomography in mild head trauma. A controlled study. *J Neuroimaging* 1994;4:177-81.
19. Peuvot J, Schanck A, Deleers M, Brasseur R. Piracetam-induced changes to membrane physical properties. A combined approach by ³¹P nuclear magnetic resonance and conformational analysis. *Biochem Pharmacol* 1995;50:1129-34.
20. Benzi G, Pastoris O, Villa RF, Giuffrida AM. Influence of aging and exogenous substances on cerebral energy metabolism in posthypoglycemic recovery. *Biochem Pharmacol* 1985;34:1477-83.
21. Nickolson VJ, Clason-van der Wiel HJ, Wolthuis OL. Further studies on the therapy of organophosphorous anti-cholinesterase intoxication with veratrinic compounds; the role of calcium. *Eur J Pharmacol* 1975;30:188-96.
22. Gouliaev AH, Senning A. Piracetam and other structurally related nootropics. *Brain Research Reviews* 1994;19:180.
23. Croisile B, Trillet M, Fondarai J, Laurent B, Mauguier F, Billardon M. Long-term and high-dose piracetam treatment of Alzheimer's disease. *Neurology* 1993;43:301-5.
24. Fernandes CM, Samuel J. The use of piracetam in vertigo. *S Afr Med J* 1985;68:806-8.
25. Oosterveld WJ. The efficacy of piracetam in vertigo. A double-

- blind study in patients with vertigo of central origin.
Arzneimittelforschung 1980;30:1947-9.
26. De Deyn PP, Reuck JD, Deberdt W, Vlietinck R, Orgogozo JM. Treatment of acute ischemic stroke with piracetam. Members of the Piracetam in Acute Stroke Study (PASS) Group.
Stroke 1997;28:2347-52.