

# Percutaneous Pedicle Screw and Rod Insertion for Fracture of the Lumbar Spine

**Prafulla Kumar Sahoo** M Ch

Department of Neurosurgery  
Army Hospital (Research & Referral)  
Delhi Cantt 110010, New Delhi

**Abstract:** Standard techniques for lumbar pedicle screw and rod fixation involve open exposure and extensive muscle dissection. The purpose of this study was to report the indications, operative techniques and preliminary experiences with percutaneous lumbar pedicle screw and rod insertion for internal fixation of the lumbar spine. Fifteen patients underwent percutaneous pedicle screw and rod fixation. Spondylolisthesis was present in six patients, compression fracture in four, chronic discogenic pain in four and tuberculosis of the spine was present in one patient. All patients underwent successful percutaneous single level fusions. The follow up period ranged from 6 to 12 months. Percutaneous lumbar pedicle screw and rod insertion can be performed in a straight forward manner through percutaneous stab wounds. This procedure minimises the morbidity associated with traditional open approaches without compromising the quality of spinal fixation. Preliminary experiences with this device has been encouraging

**Keywords :** Percutaneous Surgery; Lumbar Spine, Pedicle Screw Fixation

## INTRODUCTION

The uses of pedicle screws for spinal stabilisation have become increasingly popular worldwide. Pedicle screw system engages all three columns of the spine and can resist motion in all planes. Several studies suggest that pedicle screw fixation is a safe and effective treatment for many spinal disorders<sup>1,2</sup>. Standard techniques for pedicle screw placement require extensive tissue dissection to expose entry points and to provide lateral-to-medial orientation for optimal screw trajectory. Open pedicle screw and rod fixation have been associated with wide paraspinal muscle dissection, extensive blood loss, lengthy hospital stays, and high cost<sup>3</sup>.

Magerl<sup>4</sup>, who used an external fixator, first described percutaneous fixation of the lumbar spine. Mathews and Long<sup>5</sup> first described and performed percutaneous lumbar pedicle fixation technique in which they used plates as the longitudinal connectors. Lowery and Kulkarni<sup>6</sup> subsequently described a similar technique in which rods were placed. Although the latter authors reported high success rate, Mathews and Long noted a significant rate of non-union. In all cases, the longitudinal connectors were placed either externally<sup>4</sup> or superficially, just beneath the skin<sup>5-7</sup>. This has several potential disadvantages. First,

the superficial hardware can be irritating and requires routine removal<sup>6</sup>. Second, longer screws are required, producing a less effective biomechanical stabilisation than that achieved using standard pedicle fixation systems and leading to a higher potential for implant failure.

The use of the percutaneous pedicle screw and rod fixation (Sextant) system offers several distinct advantages over conventional pedicle screw fixation. The system eliminates the need for a large midline incision and significant paraspinal muscle dissection. Both the pedicle screws and the precontoured rods are placed through stab incisions. The paraspinal muscles are bluntly split rather than divided, leading to shorter periods of hospitalisation and recovery<sup>7,8,9</sup>. Blood loss and tissue trauma are minimised. An ideal lateral-to-medial screw trajectory is much more easily accomplished, especially in larger patients, as significant paraspinal tissue retraction is avoided.

Compared with previously used percutaneous techniques, the Sextant procedure allows the screw/rod to be placed in a standard anatomical position. This optimizes the biomechanics of the fixation and allows the hardware to remain in place without irritating the superficial tissues of the low back, and thus avoids routine hardware removal. In addition, this technique minimizes much of the "fiddle factor" of connecting a percutaneous rod to pedicle screws. The inserter geometrically constrains the rod's

*Address for correspondence :* Col P K Sahoo M Ch  
Department of Neurosurgery  
Command Hospital (SC), Pune - 411040, Maharashtra

pathway, simplifying insertion of the rod. The Cannulated extension sleeves allow the lock plugs to be quickly and easily seated against the rod, simplifying screw-rod connection. Because the Sextant inserter remains connected to the screws and rods, appropriate compression and distraction forces can be applied to the construct prior to final tightening.

### **The Percutaneous Screw & Rod Insertion (Sextant) System**

The CD Horizon® Sextant™ spinal system is a minimal access spinal technology (MAST™), that offer surgeons the ability to treat spinal conditions using less-invasive techniques and minimise the approach related morbidity of traditional lumbar pedicular screw fixation. The instrumentation uses poly axial screws and pre-contoured rods that are inserted percutaneously. This is possible by the use of geometrically constrained inserter (an innovative mechanical arc device) that passes the rod directly into the screw heads through a small skin incision to stabilise the adjoining vertebrae with minimal injury to muscles near the spine. This minimally invasive technique significantly reduces the size of the incision and resulting scarring to the major muscles in the back. The key benefit is reduced trauma to the soft tissue surrounding the spine. Less paraspinous muscle dissection reduces the postoperative pain with shorter recovery time and early rehabilitation.

### **Indications**

Percutaneous pedicle screw and rod fixation of lumbar spine is appropriate for chronic back and leg pain due to (a) Degenerative disc disease and (b) Grade I or II spondylolisthesis. Acute low back pain due to (a) Compression fracture without neurological deficit and (b) Tuberculosis of the spine can also be treated by the above method. Patients with severe lumbar canal stenosis, severe osteoporosis and spinal infection are poor candidates for percutaneous pedicle screw and rod fixation. Patients with grade III and IV spondylolisthesis should not undergo surgery by minimal access percutaneous method

### **Surgical Strategy**

A multiaxial lumbar pedicle screw system was designed so that screws could be placed percutaneously using an extension sleeve that would allow for remote manipulation of the poly axial screw heads and remote engagement of the screw locking mechanism. A unique rod insertion device was developed that linked to the screw extension sleeves, allowing for a pre-cut, precontoured rod to be placed through a small stab wound. Because the insertion device relies on geometrical constraint of the rod pathway through the screw heads, rods can be placed in a standard

sub muscular position with minimal manipulation, essentially without muscle dissection, and without the need for direct visual feedback

### **1. Operative Room set up, anaesthesia and Patient positioning**

Preoperative planning is useful in determining the proper starting point and screw trajectory. The percutaneous posterior fixation of the dorsolumbar spine is performed under general anaesthesia. The patient should be positioned prone, on top of chest rolls with the abdomen free, but a knee chest position should be avoided. Verify that adequate fluoroscopic images of the pedicles can be obtained in both an AP and lateral view before proceeding. While adjustments in patient positioning can be made, tables that limit good AP fluoroscopy should generally be avoided. A longer preparation area is also necessary because the SEXTANT rod inserter can have an entry point relatively far away from the levels being instrumented.

### **2. Initial Skin Incisions and Pedicle Identification**

A 22-gauge spinal needle can be used to verify the appropriate location of the skin incisions. The needle is positioned on the skin directly over the pedicle on an AP image. The needle is then moved laterally 1 to 2 cm and inserted through the skin to the intersection of the facet and transverse process. Both AP and lateral images confirm that the appropriate starting place has been determined. The pedicle is roughly a cylindrical structure. The ideal starting point is at the intersection of the facet and the transverse process. As the pedicle is navigated, the trajectory should be aimed toward the medial wall, but not approach it too closely.

### **3. Pedicle Screw Placement**

- (a) **Pedicular access:** An 11-gauge bone biopsy needle is used to gain access to the pedicle. After placing the bone biopsy needle at the intersection of the facet and the transverse process, the needle may be advanced partially through the pedicle. An AP image should show the needle tip at the lateral margin of the pedicle initially. As the needle advances towards the base of the pedicle, it should approach the pedicle centre on the AP image.
- (b) **Insertion of Guide wire:** The inner trocar of the needle is removed to allow the guidewire to be inserted into the pedicle. Unintentional advancement of the wire can be potentially dangerous. Once the guidewire is inserted, the needle may be removed.

- (c) **Dilatation of the Lumbodorsal fascia:** The fascia and muscle must be dilated to allow for screw placement. Three dilators are used to gently make a path of the appropriate dimension. The first two dilators are removed, leaving the third dilator to serve as a tissue protection sleeve during the tapping step.
- (d) **Pedicle Preparation:** The pedicle is prepared by placing the tap over the guidewire and through the third dilation sleeve. Fluoroscopy should be used to verify the position of the guidewire and the tap during this step. Screw length can be determined by using the calibration markings on the shaft of the tap. After tapping, remove the dilator but leave the guidewire in place.
- (e) **Screw Extender Assembly:** Before a screw can be inserted into the pedicle, the screw extenders must be assembled to the Multi Axial Screws. First, a setscrew is placed in the setscrew-retaining sleeve by pushing the smooth cap of the setscrew into the distal end of the sleeve. Make certain the threads are not inside the sleeve.

Next, the sleeve is placed into the screw extender. Initially the two buttons on the extender must be depressed, but they should be released after the sleeve is partially inserted. As the sleeve slides down, an audible “click” will be heard, confirming the sleeve is in the correct, most upward position. *The proper position of the sleeve is very important, as it will allow for the rod to engage the saddle of the Multi Axial Screw.*

A CD HORIZON® Cannulated M8 Multi Axial Screw is placed in the distal end of the extender and the combination plug driver is used to advance the setscrew. The inner sleeve prevents the setscrew from travelling too far into the saddle of the M8 screw. Before implantation, check to make sure the setscrew is in the appropriate position by visual inspection and by manually passing a rod between the screw head and the setscrew.

The screwdriver is placed into the screw assembly from the top. The tip of the screwdriver passes through the setscrew and into the head of the Multi Axial Screw. Since the screwdriver passes through the setscrew, care should be taken during screwdriver insertion and removal. This will ensure the screwdriver does not change the position of the setscrew. The entire assembly is then inserted over the guidewire

- (f) **Final Screw Placement:** After driving the screw assembly into the pedicle, remove the guidewire to prevent it from being advanced. Be certain that the screw assembly is not inserted too far. If the multi

axial head of the M8 screw is driven too forcefully against bone, it will lose its multi axial capabilities making it difficult to connect the assemblies during subsequent steps.

- (g) **Second Screw Placement:** The process is repeated for the second screw on the same side. After inserting both, the screw assemblies should be at approximately the same height outside of the patient. Both assemblies should move freely following insertion.

#### 4. Rod Placement

- (a) **Connection of extenders:** Rotate the extenders so the two flat sides are facing each other. The male and female parts are then mated together and rotated so there is no gap between the two extenders. Once the extenders are connected and the flat surfaces are completely flush, the rod inserter can be attached.
- (b) **Attachment of the Rod Inserter and Rod Trocar:** The rod inserter is attached to the two screw assemblies by lining up the pegs of the inserter and the grooves of the assemblies. The thumbscrew on the side of the inserter is tightened to attach the device securely. A rod trocar tip must then be placed into the tip of the rod inserter by backing out, and then pushing down the thumbscrew on top of the inserter. After the trocar is in place, tighten the thumbscrew to securely fasten the tip.
- (c) **Passage of the Trocar:** The rod trocar is used to help make a path through the fascia and muscle down to the saddle of the first screw. A small skin incision is required, then the trocar is advanced through the muscle until it hits the first screw saddle as confirmed on lateral fluoroscopy.
- (d) **Measurement of Rod:** The appropriate rod length may be determined by placing the rod templates into the two screw extenders. If the template is beyond the line of a particular rod length, the next size rod must be used. After determining rod size, the templates are removed before rod insertion.
- (e) **Passing the Rod:** Replace the rod trocar with the appropriate sized rod as determined by the rod template. Trocar removal is accomplished by reversing the steps for attachment. Pass the rod through the screw heads so the tapered tip of the rod is completely through the distal screw as verified by lateral fluoroscopy.
- (f) **Final Tightening:** After verifying with AP, lateral, and oblique views that the rod is seated in the heads

of both screws, the set screws can be tightened. Before attempting to tighten the set screws, the lock screw retaining sleeves must be lowered, press the buttons on the screw extenders and push the inner sleeves down. This step allows the set screws to engage the rod.

The compressor handles may be used for provisional tightening. With both handles in place, the construct can be compressed, held and provisionally tightened. Final tightening is achieved with the final plug driver by tightening until the set screw heads shear off. The sheared-off portion of the set screws will be retained inside the retaining sleeves (Fig 1).

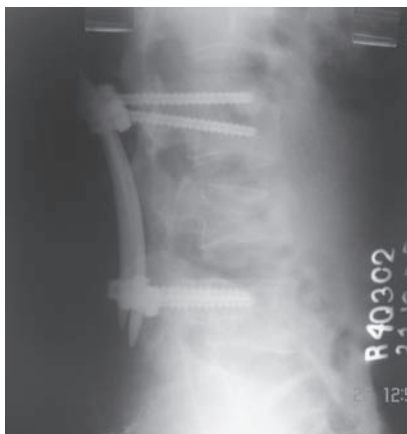


Figure 1.

### 5. Removal of Assembly

The rod inserter must be detached from the rod by again reversing the steps of attachment. After the inserter is disconnected from the rod, the entire rod inserter assembly may now be pulled out of the patient. The final construct can then be viewed with AP and lateral fluoroscopy. The entire process is repeated for the contralateral side.

### 6. Closure (Fig. 2)

Closure is accomplished with a few interrupted stitches in the fascia, a subcuticular skin suture and Dermabond/dressings.

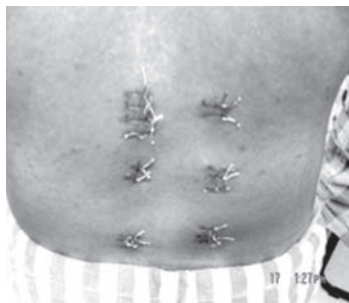

FIGURE 2 : Skin closure

## OUR EXPERIENCE

### Patient Population

Fifteen patients presented with low back pain and occasional leg pain. Appropriate conservative management had failed to relieve patients of their symptoms. There were ten men and five women, with ages ranged from 28 to 60 years.

Clinical indications were correlated with radiological findings. Grade I & II spondylolisthesis was present in six patients; compression fracture LV- 4 in two and LV- 5 in two patients. Four patients had chronic discogenic low back pain and one patient had tuberculosis of LV4. All patients required a single level fusion. Amongst the single level fusions, one was at L3-L4; ten were at L4-L5, and four were at L5-S1.

### RESULTS

Fifteen consecutive patients underwent placement of percutaneous pedicle screws and rod insertion during Jan 2004 to Jun 2005. Datas were collected in a prospective manner. There were no intra operative complications in the form of dural tear, CSF leak and nerve root damage. Post operatively there was no wound infection or neural damage. The implants were in place during 2 and 6 months follow up. Postoperative pain was far less with shorter recovery time and normal activities were resumed early than open method. The initial clinical results using the Sextant system for percutaneous posterior fixation of the lumbar spine have been encouraging.

### DISCUSSION

Lumbar spinal fusion was first performed by Albee<sup>10</sup> and Hibbs<sup>11</sup> in the early 1900's for the surgical management of spinal deformity related to pott's disease. Due to its initial success, the indications for this technique were later expanded to include traumatic injuries and scoliosis. Boucher<sup>12</sup> first described the pedicle screw in 1959 and Roy-Camille et al<sup>13</sup> reported a dorsal construct consisting of a pedicle screw and plate several years later. Spinal pedicle screw fixation has continued to undergo modifications since its inception. Its effectiveness in the management of a variety of spinal disorders has made it a mainstay in the armamentarium of most spine surgeons.

However, an undesired consequence of this technique is the iatrogenic paraspinal muscle injury that occurs during the exposure for screw placement. A number of authors have described the deleterious effects of the extensive muscle stripping and retraction that occur during lumbar fusion surgery<sup>14-19</sup>. Gejo et al<sup>14</sup> analysed postoperative MRI

and trunk muscle strength following lumbar surgery in 80 patients. They determined that damage to the low back muscles was directly related to the muscle retraction time during surgery. The incidence of low back pain was also significantly higher in those who had long muscle retraction times. These conclusions support the studies of Kawaguchi et al<sup>15-16</sup> who examined the effects of retractor pressure on the paraspinal muscles during lumbar surgery. They found that muscle injury, as demonstrated by elevated serum levels of creatine phosphokinase MM isoenzyme, is directly related to the retraction pressure and duration. Similarly, Styf et al<sup>17</sup> reported that the retractor blades may in fact increase intramuscular pressure in the paraspinal muscles to ischaemic levels. Rantanen et al<sup>18</sup> concluded that patients with poor outcomes following lumbar surgery are more likely to have persistent pathological changes within the paravertebral muscles.

Percutaneous lumbar fixation was designed, in part, to minimize the paravertebral muscle injury that occurs with conventional open procedures. Magerl<sup>4</sup> first reported the use of percutaneous pedicle screw combined with an external fixator in 1982. The most obvious limitation of this technique was the risk of infection, not to mention the discomfort of an external appliance. Matthews et al<sup>5</sup> described the use of percutaneous pedicle screws with longitudinal connectors placed under direct vision in the suprafascial, subcutaneous space. This superficial instrumentation was uncomfortable to the patient and associated with a significant non-union rate as well, perhaps secondary to the long lever arms of the hardware.

The Sextant system allows for placement of percutaneous screws and rods through paramedian stab incisions. The conventional anatomic position of the construct avoids the instrumentation-related discomfort that was associated with earlier versions of percutaneous fusion. The geometrically constrained arc produced by the Sextant apparatus simplifies the connection of the percutaneous rods and screws.

There are several distinct advantages of the Sextant system compared to standard open lumbar pedicle fixation. The paraspinal muscles are bluntly separated rather than stripped from their attachments and are minimally retracted using a sequential dilation technique as described by Foley and Smith<sup>9</sup> for microendoscopic discectomy. This results in significantly less intraoperative blood loss, less iatrogenic muscle injury, and less postoperative pain. Patients are therefore able to ambulate and mobilize much more quickly, resulting in a decreased cost<sup>20</sup>. From a technical perspective, it is also easier to achieve the desired lateral to medial pedicle screw trajectory as there is not a

wall of soft tissue that limits the angulation of the instruments (as can be encountered in the open surgery). This is particularly helpful in obese patients, as more extensive exposure and retraction can be avoided. Operative time is also significantly lessened; it takes only one hour for the surgeon to place four screws and two rods.

## CONCLUSION

Minimally invasive approaches for performing lumbar fusion are in their infancy. Other minimally invasive approaches to lumbar fusion are evolving. The goal of these surgeries is to minimize approach-related morbidity while achieving the same result as traditional, invasive approaches. The Sextant system is an emerging component in the rapidly developing field of minimally invasive spine surgery. As the technology continues to evolve the indications for Sextant will certainly expand from primarily degenerative disease to include multi-level fusions for spinal disorders due to trauma and neoplastic conditions. The clinical utility of Sextant system appears promising, as our early experience suggests that the system is able to achieve the same clinical results as conventional open procedures while significantly reducing the exposure-related morbidity.

## REFERENCES

1. Gaines RW. The use of pedicle-screw internal fixation for the operative treatment of spinal disorders. *J Bone Joint Surg (Am)* 2000; 82-A: 1458-76.
2. Yuan HA, Garfin SR, Dickman CA, et al. A historical cohort study of pedicle screw fixation in thoracic, lumbar and sacral spine fusions. *Spine* 1994;19 (Suppl 20) 2279S-96S.
3. Thomsen K, Christensen FB, Eiskjaer Sp, et al : (1997 Volvo Award winner in clinical studies). The effect of pedicle screw instrumentation in functional outcome and fusion rates in posterolateral lumbar spinal fusion: a prospective, randomized clinical study. *Spine* 1977; 22: 2813-22.
4. Magerl F: External skeletal fixation of the lower thoracic and the lumbar spine, in Uthoff HK, Stahl E (eds) : Current concepts of external fixation of fractures. New York : Springer-Verlag, 1982 pp 353-366.
5. Mathews HH, Long BH : Endoscopy assisted percutaneous anterior interbody fusion with subcutaneous suprafascial internal fixation : evolution of technique and surgical considerations. *Orthop Int Ed* 1995; 3 : 496-500.
6. Lowery GL, Kulkarni SS : Posterior percutaneous spine instrumentation. *Eur Spine J* 2000; 9 (Suppl 1) S126-S30.
7. Foley KT, Simon DA, Rampersaud YR : Virtual fluoroscopy. *Op Tech Orthop* 2000;10: 77-81.

8. Foley KT, Simon DA, Rampersaud YEAR : Virtual fluroscopy. Computer assisted fluroscopic navigation. *Spine* 2001; 26: 347-51.
9. Foley KT, Smith MM: Microendoscopic discectomy. *Tech Neurosurg* 1997; 3: 301-7.
10. Albee FH: Transplantation of a portion of the tibia into the spine for pott's disease. *JAMA* 1911; 57:885-6.
11. Hibbs RA: An operation for progressive spinal deformities. *NY Med J* 1911; 93:1013-6.
12. Boucher HH: A method of spinal fusion. *J Bone Joint Surg* 1959; 41-B: 248-59.
13. Roy-Camille R, Saillant G, Mazel C: Internal fixation of the lumbar spine with pedicle screw plating. *Clin Orthop* 1986; 203:7-17.
14. Gejo R, Matsui H, Kawaguchi Y, et al: Serial changes in trunk muscle performance after posterior lumbar surgery. *Spine* 1999; 24 (10):1023-8.
15. Kawaguchi y, Matsui H, Tsuji H: Back muscle injury after posterior lumbar spine surgery. Part 2: Histologic and histochemical analyses in humans. *Spine* 1994;19:2598-602.
16. Kawaguchi Y, Matsui H, Tsuji H: Back muscle injury after posterior lumbar spine surgery. Part 2: Histologic and histochemical analyses in humans. *Spine* 1994;19: 2598-2602,.
17. Styf JR, Willen J: The effects of external compression by three different retractors on pressure in the erector spine muscles during and after posterior lumbar spine surgery in humans. *Spine* 1998; 23: 354-8.
18. Rantanen j, Hurme m, Falck B, Alaranta H, Nykvist F, Lehto M, Einola S, Kalimo H: The lumbar multifidus muscle five years after surgery for a lumbar intervertebral disc herniation. *Spine* 1993;18: 568-74.
19. Sihvonen T, Herno A, Paljivarvi L, Airaksinen O, Partanen J, Tapaninaho A: Local denervation atrophy of paraspinal muscles in postoperative failed back syndrome. *Spine* 1993;18: 575-81.
20. foley KT, Gupta SK, Justis JR, Sherman MC : Percutaneous pedicle screw fixation of the lumbar spine. *Neurosurg Focus* 2001;10: 1-8.