

Pneumocephalus on MRI: Use of gradient imaging

Rahat Brar M D, Abhishek Prasad M D, Tarun Sharma M S*, V K Khosla M Ch*

Departments of Radiology and *Neurosurgery, Fortis Hospital, Sector 62, Phase VIII, Mohali, Punjab-160062

A 30 year old pregnant patient was referred to us for MRI brain for evaluation of headache. T1 and T2 weighted MRI (Figs 1 and 3) of the brain revealed few hypointense foci in the interhemispheric fissure which were initially thought to be dural calcifications. The T2-weighted gradient images (Figs 2 and 4) revealed multiple such lesions in the interhemispheric fissure and also showed additional lesions in the basal cisterns and the right sylvian fissure. These lesions were quite prominent on T2-weighted gradient refocused (GRE) images and showed significant blooming. The non dependent nature of these lesions and a linear tracking pattern of distribution suggested that these could represent air foci in the subarachnoid space. Detailed history revealed that the patient had a history of head trauma two years back for which she had not taken any treatment.

It is well known that air in the magnetic field has very low magnetic susceptibility and can cause signal loss on MRI, especially on GRE sequence¹. This loss of signal can be used to diagnose the presence of subtle intracranial air which is prominently seen on T2 GRE images. This

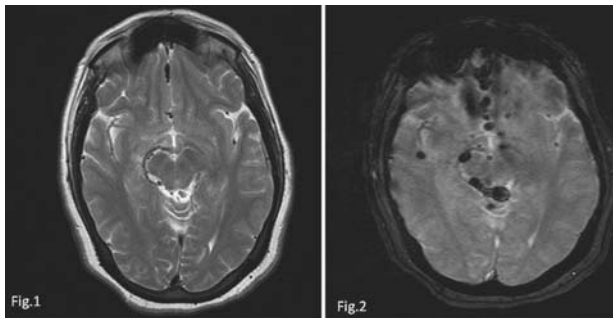


Fig 1: T2-weighted image of brain showing small hypointense foci in the anterior interhemispheric fissure.

Fig 2: GRE image at the same level (as Fig 1) showing prominent multiple hypointense foci in the anterior interhemispheric fissure, right quadrigeminal and ambient cisterns and in the right insular cistern with blooming.

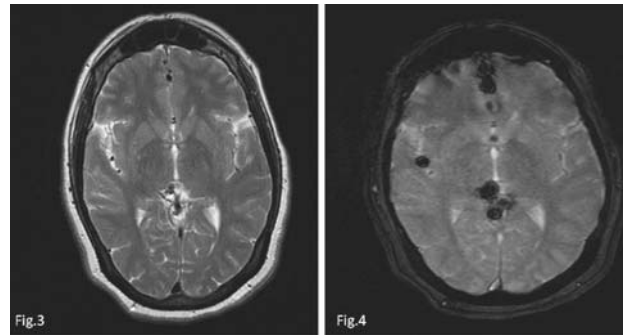


Fig 3: T2-weighted image of brain showing subtle small hypointense foci in the anterior and posterior aspects of interhemispheric fissure.

Fig 4: GRE image at the same level (as Fig 3) showing prominent multiple hypointense foci in the interhemispheric fissure, right insular cistern and the suprapineal cisterns with blooming.

article reinforces the fact that gradient based sequences, like T2-weighted GRE images play a vital role, not only in detecting subtle punctate hemorrhages, calcifications, arteriovenous malformations²; but also help in confirming the presence of air in case of equivocal T2-weighted images. This is particularly useful in cases where CT cannot be done due to the harmful effect of radiations.

REFERENCES

1. Atlas SW. Magnetic resonance imaging of the brain and spine, 3rd ed. Philadelphia: Lippincott Williams & Wilkins, 2002:239-75.
2. de Souza JM, Domingues RC, Cruz LC, et al Susceptibility-weighted imaging for the evaluation of patients with familial cerebral cavernous malformations: a comparison with T2-weighted fast spin-echo and gradient echo sequences. *AJNR Am J Neuroradiol* 2008; 29:154-8.

Address for correspondence :

Rahat Brar MD, DNB
Department of Radiology, Fortis Hospital,
Sector - 62, Phase VIII, Mohali - 160062 (Punjab)
E-mail: dr_rahatarbrar@yahoo.com