

## Unusual mode of cervical spine injury

P Kushwaha MS, DP Sharma MS, H Singh M Ch, D Singh M Ch  
Department of Neurosurgery, G B Pant Hospital, New Delhi

**Abstract:** The common causes of cervical spine injury includes trauma particularly road side accidents. Some time trivial trauma of spine can produce neurological deficits particularly if the spine is already diseased e.g. osteoporosis of tuberculosis. we present an unusual case report of cervical spine injury in a young female with healthy spine The injury resulted by the fall of a flower pot on her head. This resulted in fracture of C 4 vertebra which required surgical intervention.

**Keywords:** cervical spine; cervical spine fracture; cervical spine trauma

### INTRODUCTION

The common causes of cervical spine injury are road side accidents, assaults or fall from height. However lesser known causes of cervical spine injury includes strangulation from *dupatta* (scarf)<sup>1</sup>, threshing machines<sup>1</sup> sport injury e.g. skiing<sup>2</sup> and fall from trees<sup>3</sup>. We report an uncommon cause of cervical spine injury and discuss the possible mechanism of that.

### CASE REPORT

A 21 years old female presented to us with history of fall of flower pot over the head. The earthen pot was around 10 inches diameter, with some small herbs grown in it. Pot fell on her head accidentally from 12 feet height. She had a history of unconsciousness lasting 40 minutes, and vomiting. GCS was E4M4V2, and pupils were NS/NR. There was weakness present over B/L upper limb Rt.> Lt. There was no evidence of bladder bowel involvement. A small laceration 6 cms long over the vertex was stitched. On examination, upper limbs were flaccid, power in right shoulder and elbow was 2/5 at wrists and 3/5 in fingers and hand. Power in left upper limb was 4/5. Reflexes were absent on right side and diminished on left side. Lower limbs had normal power and exaggerated tendon reflexes. Sensations were intact.

X ray of cervical spine revealed a burst fracture of C4 vertebra without evidence of damage to the posterior column. However there was a mild instability on flexion (Fig 1). MRI showed fracture C4 with cord compression and intrinsic changes in the cord (Fig 2). CT head was normal.

*Address for correspondence:*

Daljit Singh  
Department of Neurosurgery  
G B Pant Hospital, New Delhi

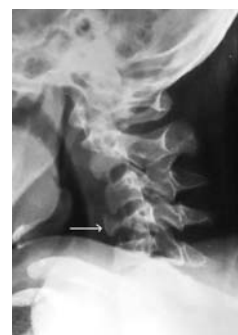

Fig 1: Plain Xray cervical spine showing burst fracture of C4 (arrow) with instability in flexion.

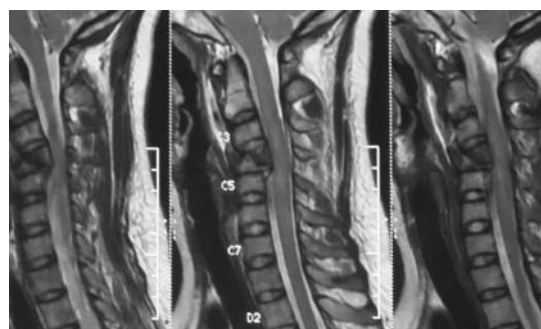


Fig 2: Sagittal MRI section showing cord compression and changes in cord.

Patient was initially managed with injection methyl prednisolone (30mg/kg bolus followed by 5.4mg/kg/hr infusion). She was put on cervical traction and was prepared for surgery. Two days later, she underwent corpectomy C4 and iliac bone grafting and fixation using plate and screw (Medtronic). Post operatively her power gradually improved and she was discharged on eighth postoperative day with grade 4/5 power in all limbs.

### DISCUSSION

Approximately 5-10% of unconscious patients who present to the emergency as the result of a motor vehicle

accident or fall have a major injury to the cervical spine<sup>4</sup>. Most fatal cervical spine fractures occur at C2 level, and one half of injuries occur at the level of C6 or C7<sup>5</sup>. There are three distinct columns: anterior, middle, and posterior which support spine. The anterior column is composed of the anterior longitudinal ligament and the anterior two thirds of the vertebral bodies, the annulus fibrosus and the intervertebral disks. The middle column is composed of the posterior longitudinal ligament and the posterior one third of the vertebral bodies, the annulus and intervertebral disks. The posterior column contains all of the bony elements formed by the pedicles, transverse processes, articulating facets, laminae, and spinous processes.

The anterior and posterior longitudinal ligaments maintain the structural integrity of the anterior and middle columns. The posterior column is held in alignment by a complex ligamentous system, including the nuchal ligament complex, capsular ligaments, and the ligamenta flava.

If single column is disrupted, other columns may provide adequate stability to prevent spinal cord injury. If two columns are disrupted, the spine may move as separate units, increasing the likelihood of spinal cord injury.

Cervical spine injuries are best classified according to several mechanisms of injury. These include flexion,

flexion-rotation, extension, extension-rotation, vertical compression, lateral flexion, and imprecisely understood mechanisms that may result in odontoid fractures and atlanto-occipital dislocation.

The mechanism of fracture in our case is likely to be vertical compression of the spine at C4 level. The axial loading that happened due to fall of the pot resulted in burst fracture of C4. As C4 vertebra forms the central part of the cervical spine, it is likely that the maximum weight was transmitted in axial load at that level resulting in burst fracture of C4 vertebra.

## REFERENCES

1. Jain V, Agrawal M, Dabas V, et al. Dupatta (scarf): a unique cause of cervical spine injury in females. *Injury* 2008; 39:334-8.
2. Grubenhoff JA, Brent A. Case report: Brown Sequard syndrome from ski injury in 7-year-old male. *Current Pediatr* 2008; 20:341-4.
3. Fayssoux RS, Tally W, Sanfilippo JA, et al. Spinal Injuries after fall from hunting trees stands. *Spine J* 2008; 8:522-8.
4. Sengupta DK. Neglected spine injuries. *Clinic Orthoped Relat Res* 2005; 431:93-103.
5. Miranda P, Gomex P, Alday R, et al. Brown Sequard syndrome after blunt cervical spine trauma; clinical and radiological correlation. *Euro Spine* 2007; 16:165-70.