

Unilateral multi-compartmental chronic subdural hematoma in a kabaddi player

Amit Agrawal M Ch

MM Institute of Medical Sciences & Research, Maharishi Markandeshwar University, Mullana, Ambala, Haryana

Kabaddi is a game widely played in India and in many other countries; which combines the actions of wrestling, judo, rugby and gymnastics and the important body movements in this game involve catching, holding, locking and jumping¹. In spite of the wide popularity of this game only few reports address the issue of injuries associated with game^{2,3}. A 24 year male patient presented with the history of headache of 10 days duration. Headache was associated with blurring of vision, neck stiffness and vomiting. There was no history of focal weakness, fever or seizures. He had head-on collision with a fellow player while playing kabaddi two months earlier, and at that time he had transient loss of consciousness followed by recovery. Clinical examination was unremarkable, and funduscopy revealed papilloedema. Coagulation profile was normal. CT brain showed right-sided isodense biconvex temporal collection and a separate right sided fronto-parietal isodense concavo-convex collection with mass effect and midline shift (Figures 1 and 2). He was diagnosed as having right sided multi-compartmental chronic subdural hematoma, and taken for surgery. The sub-dural hematoma was evacuated through a high temporal burr-hole and through a small low temporal craniectomy. After surgery his headache was relieved and he is doing well.

Chronic subdural hematoma (CSDH) is one of the most common types of traumatic intracranial hematoma encountered in daily neurosurgical practice, and often occurs in the elderly⁴⁻⁸. CSDH may be precipitated by minor trauma⁹ and sports related CSDH have been reported in many sports including boxing¹⁰⁻¹³, basketball¹⁴, race walking⁹ and snowboard head injury¹⁵. An extensive search of the literature revealed that a CSDH in kabaddi player have not been reported in the literature. Based on the timing age of the CSDH, timing of imaging based

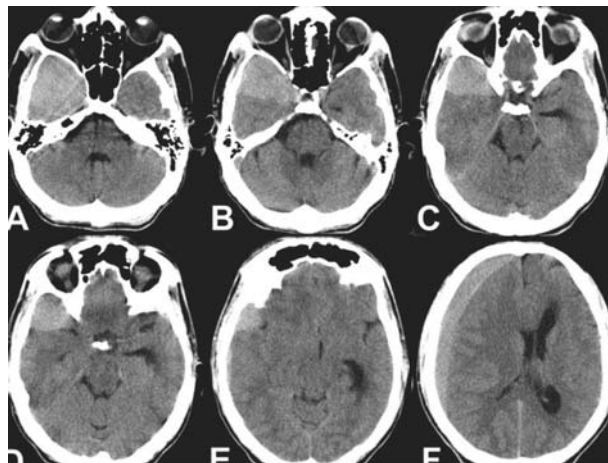


Fig 1: CT scan brain axial images showing crescentic hypo- and isodense fronto-parietal and biconvex temporal-sub temporal collections of chronic subdural hematoma

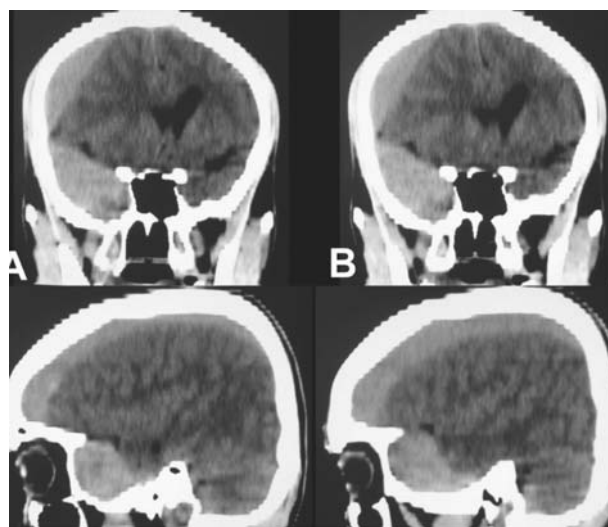


Fig 2: CT scan brain sagittal images showing crescentic hypo- & isodense fronto-parietal and biconvex temporal-sub temporal collections of chronic subdural hematoma

and patterns observed on the conventional views a classification regarding the shape of CSDH has been proposed and it describes the lesions as Type 1 (band), Type 2 (biconvex), Type 3 (diffuse) and Type 4 combined¹⁶. CSDH usually spreads out over the cerebral convexity, and appears as a crescent-shaped lesion^{17,18} and on imaging

Address for correspondence:

Professor of Neurosurgery
MM Institute of Medical Sciences & Research
Maharishi Markandeshwar University
Mullana, Ambala, 133-207 (Haryana). Mobile: +91-7206423180
E-mail: dramitagrawal@gmail.com / dramit_in@yahoo.com

rarely it can be of globular shape¹⁷, albeit subtemporal location of the subdural hemorrhage is not very common^{19,20}. Evaluation of an athlete with a history of head injury, albeit mild, who complains of headaches should include CT and/or MRI if available to allow quick identification of acute or delayed intracranial pathology¹⁵.

REFERENCES

1. Dey SK, Khanna GL, Batra M. Morphological and physiological studies on Indian national kabaddi players. *Br J Sports Med* 1993; 27:237-42.
2. Ganorkar SW, Vaidya VA. Injury incidence among kabaddi players during the two all-India level tournaments. *J Indian Med Assoc* 1973; 60:240-3.
3. Sangwan SS, Aditya A, Siwach RC. Isolated traumatic rupture of the adductor longus muscle. *Indian J Med Sci* 1994; 48:186-7.
4. Ernestus RI, Beldzinski P, Lanfermann H, Klug N. Chronic subdural hematoma: surgical treatment and outcome in 104 patients. *Surg Neurol* 1997; 48:220-5.
5. Stanisic M, Lund-Johansen M, Mahesparan R. Treatment of chronic subdural hematoma by burr-hole craniostomy in adults: influence of some factors on postoperative recurrence. *Acta Neurochir (Wien)* 2005; 147:1249-56; discussion 56-7.
6. Gelabert-Gonzalez M, Iglesias-Pais M, Garcia-Allut A, Martinez-Rumbo R. Chronic subdural haematoma: surgical treatment and outcome in 1000 cases. *Clin Neurol Neurosurg* 2005; 107:223-9.
7. Muzii VF, Bistazzoni S, Zalaffi A, Carangelo B, Mariottini A, Palma L. Chronic subdural hematoma: comparison of two surgical techniques. Preliminary results of a prospective randomized study. *J Neurosurg Sci* 2005; 49:41-6; discussion 6-7.
8. Lee JK, Choi JH, Kim CH, Lee HK, Moon JG. Chronic subdural hematomas : a comparative study of three types of operative procedures. *J Korean Neurosurg Soc* 2009; 46:210-4.
9. Carmont MR, Mahattanakul W, Pigott T. Acquisition of a chronic subdural haematoma during training for competitive race walking? *Br J Sports Med* 2002; 36:306-7.
10. Ross RT, Ochsner MG, Jr. Acute intracranial boxing-related injuries in U.S. Marine Corps recruits: report of two cases. *Mil Med* 1999; 164:68-70.
11. Sawauchi S, Murakami S, Tani S, Ogawa T, Suzuki T, Abe T. [Acute subdural hematoma caused by professional boxing]. *No Shinkei Geka* 1996; 24:905-11.
12. Cruikshank JK, Higgins CS, Gray JR. Two cases of acute intracranial haemorrhage in young amateur boxers. *Lancet* 1980; 1(8169):626-7.
13. Pothe H. [Chronic subdural hematoma in prize fighters]. *Beitr Neurochir* 1964; 8:232-7.
14. Keller TM, Holland MC. Chronic subdural haematoma, an unusual injury from playing basketball. *Br J Sports Med* 1998;32:338-9.
15. Uzura M, Taguchi Y, Matsuzawa M, Watanabe H, Chiba S. Chronic subdural haematoma after snowboard head injury. *Br J Sports Med* 2003; 37:82-3.
16. Sy WM, Weinberger G, Ngo N, Sackler JP. Imaging patterns of subdural hematoma – a proposed classification. *J Nucl Med* 1974;15:693-8.
17. Murata T, Shigeta H, Horiuchi T, Sakai K, Hongo K. Globular subdural hematoma in a shunt-treated infant: case report. *J Neurosurg Pediatr* 2010; 5(2):210-2.
18. Calvo-Romero JM. Bilateral subacute-chronic subdural hematomas. *CJEM* 2008; 10:5.
19. Grinnell V, Mehringer CM, Hieshima GB, Pribram H. Radiology of acute subtemporal subdural hematomas. *Surg Neurol* 1983; 19:438-41.
20. Glickman MG, McNamara TO, Margolis MT. Arteriographic diagnosis of subtemporal subdural hematoma. *Radiology* 1973; 109:607-15.