

## Bilateral sequentially developed asynchronous extradural haematomas

Abrar Ahad Wani M Ch, Anil Dhar MS, Masood Laherwal MS, Altaf Umar Ramzan M Ch,  
Nayil Kkurseed Malik M Ch, Furqan A Nizami MS, M A Wani M Ch

Department of Neurosurgery, Sher-i- Kashmir Institute of Medical Sciences, Srinagar (J & K)

**Abstract:** Bilateral epidural haematomas are rare but sequentially developed asynchronous bilateral extradural haematoma (EDH) is even rarer. We report a case of 30 year-old-male who was operated for EDH on one side and postoperative CT scan was done which revealed EDH on contralateral side which was evacuated.

**Keywords:** asynchronous, extradural hematoma, head injury, trauma

### INTRODUCTION

Sequentially developed EDH is a rare entity<sup>1-5</sup>. Not many cases have been reported in the literature. These hematomas are not present in initial CT head, but these develop later on. Intra operative brain swelling, coagulation abnormalities, vascular necrosis, CSF leakage, hypertension and hyperventilation are said to be the reasons behind the formation of delayed contralateral EDH<sup>4</sup>.

### CASE REPORT

A 25 year-old-male sustained head injury due to assault and was brought to hospital three hours later. He had a Glasgow Coma Score (GCS) of E3V2M5 (10/15). Both pupils were normal sized and reacting normally to light and he was hemodynamically stable. All the baseline investigations including hemogram, coagulogram and liver function tests were normal. Rest of neurological examination was normal. CT scan brain showed an EDH in right fronto temporal region with overlying multiple linear fractures (Fig 1). Patient was operated by frontotemporal approach. There were multiple linear fractures involving the frontal and temporal bones. Fractured segments of the frontal and temporal bones were removed and evacuation of EDH was done and in view of brain swelling intra operatively, bone segments were not put back and were preserved in abdominal wall subcutaneously. In the immediate post operative period patient did not show an expected recovery. CT

brain next day showed EDH in the contralateral (left) temporo-parietal region (Fig 2). Patient was operated once again and left temporo parietal craniotomy with evacuation of EDH was done. Patient improved in immediate post operative period and on discharge patient had a GCS of 15/15. CT scan showed complete evacuation of both haematomas. (Fig 3)

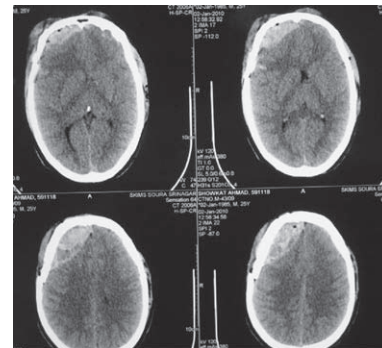


Fig 1: CT head showing EDH in right frontotemporal region with minimal midline shift & there is no sign of EDH on contralateral side

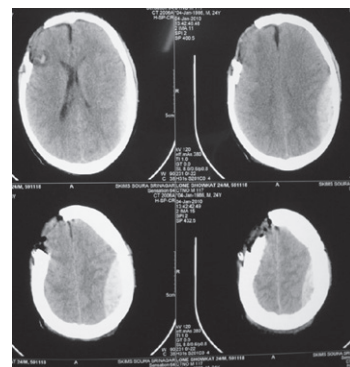


Fig 2 : CT head in immediate post operative period which shows EDH in left temporo-parietal region and complete evacuation of EDH in right frontotemporal region and craniotomy site.

#### Address for correspondence

Dr. Abrar Ahad Wani  
Assistant Professor, Department of Neurosurgery,  
Sher-i- Kashmir Institute of Medical Sciences  
Soura, Srinagar, J&K, India E-mail: abrarwani@rediffmail.com

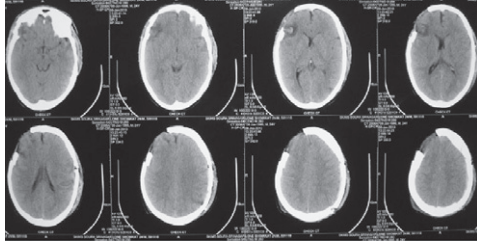


Fig 3 : CT head after second surgery and both hematomas been evacuated completely with both craniotomies

## DISCUSSION

Sequentially developed contralateral EDH is rare<sup>1,2</sup>. The contralateral EDH evolves over a period of time and may not appear in initial CT scan, so patients should be monitored continuously and check CT scan should be done when needed. The reasons for development of contralateral EDH are many, underlying clotting abnormalities, vascular necrosis because of release of enzymes, hypertension, and hyperventilation and CSF leak<sup>4</sup>. The hematoma occurring in absence of skull fractures is commonly due to venous bleeding. Bilateral sequential EDH may arise from injury to superior sagittal sinus resulting in bilateral venous bleeding. The development of first haematoma results in increase of intracranial pressure which prevents the formation of contralateral EDH. When the first hematoma is evacuated it leads to removal of tamponade effect of first EDH and results in the formation of immediate post operative contralateral haematoma<sup>4</sup>. Intraoperative brain swelling or a tense dura (if dura is not cut) once operating on the patient with first EDH gives an indication of presence or a developing hematoma on contralateral side<sup>5</sup>. In our case we had a mild brain swelling at time of surgery,

however we did not anticipate this possibility and attributed this to possible underlying evolving brain contusion. Next day when patient did not improve we repeated a CT scan which revealed a contralateral EDH which was operated. There was overlying fracture line, and we speculate that the hematoma had occurred due to release of tamponade effect of brain on the fracture site following evacuation of the first EDH.

## CONCLUSION

If a patient of operated EDH does not show an improvement as expected or if the condition of patient deteriorates immediate check CT scan brain should be advised, to detect and treat a synchronous contralateral hematoma.

## REFERENCES

1. Rochat P, Johannesen HH, Poulsgard L, Bogeskov L. Sequentially evolved bilateral epidural haematomas. *Clin Neurol Neurosurg* 2002; 105:39-41.
2. Burbridge B: Asynchronous bilateral epidural hematomas. *Can Assoc Radiol J* 1993; 44:390-2. .
3. Balasubramaniam V, Ramesh VG. A case of coup and contrecoup extradural hematoma. *Surg Neurol* 1991; 36:462-4.
4. Piepmeier JM, Wagner FC: Delayed post-traumatic extracerebral hematomas. *J Trauma* 1982; 6:455-60.
5. Matsuno A, Katayama H, Wada H, et al. Significance of consecutive bilateral surgeries for patients with acute subdural hematoma who develop contralateral acute epi- or subdural hematoma. *Surg Neurol* 2003; 60:23-30.