

Extradural hematoma with delayed onset pneumocephalus and *contré-coup* injury

Yashpal S Rathore MS, Deepak Gupta M Ch, G D Satharthi M Ch, A K Mahapatra M Ch
Department of Neurosurgery, JPN Apex Trauma Centre, All India Institute of Medical Sciences, New Delhi

INTRODUCTION

A case of large frontal extradural hematoma with cerebrospinal fluid leak from associated frontal sinus fracture is reported. Patient developed late onset *contré coup* right tentorial subarachnoid hemorrhage and bilateral pneumocephalus. Literature is scant on EDH with cerebrospinal fluid leak and pneumocephalus, and the same is being reviewed. The present case was interesting as he developed late onset *contré coup* injury also. Late onset *contré coup* injury has not been reported in literature.

Keywords: CSF leak, *contré coup* injury, Extradural hematoma, pneumocephalus,

CASE REPORT

A 30 year old male patient sustained facial and frontal impact injury after fall from moving four wheeler. Patient had transient loss of consciousness after the injury. There was no headache, vomiting, nasal discharge/bleed or seizure. Four days later he developed severe headache with multiple episodes of vomiting and cerebrospinal fluid (CSF) rhinorrhea. NCCT scan head revealed left frontal extradural hematoma (5.2 x 2.5 x 4 cm, volume 25 ml) with fracture left frontal bone involving frontal sinus, and air in extradural hematoma. Over next one week headache increased in severity, while CSF leak subsided over four days. Patient was referred to our hospital two weeks after the injury, and was seen to have left pupillary dilatation with left sixth nerve palsy. Repeat cranial NCCT showed there was no change in the left frontal extradural hematoma. There was however bilateral pneumocephalus with fresh right tentorial subdural hemorrhage (*contré coup* injury). Glasgow coma scale on admission was 15/15 (E4V5M6). Results of laboratory

studies, including blood analysis, coagulation tests, and blood chemistry, were normal. Patient was managed conservatively and was kept under observation for one week. There was symptomatic relief with resolution of headache and cessation of CSF rhinorrhea. Subsequent scan showed resolution of pneumocephalus.

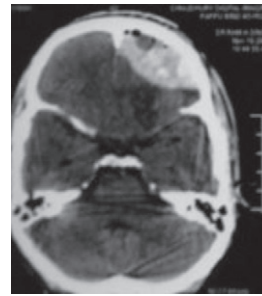


Fig 1a

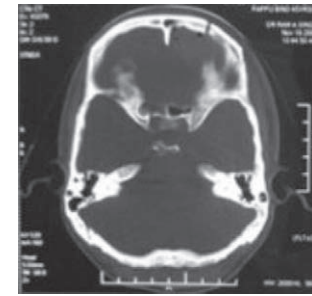


Fig 1b

Fig 1 : Initial NCCT head: Left frontal bone fracture with underlying EDH with small pneumocephalus.

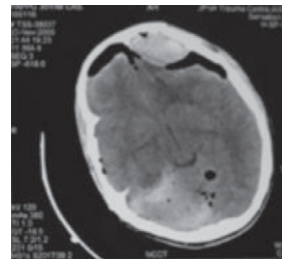


Fig 2a

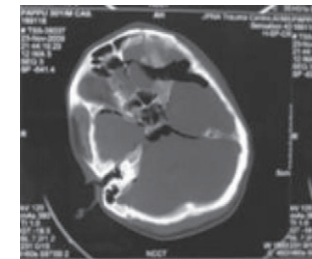


Fig 2b

Fig 2 : Repeat NCCT scan head (one week later): pneumocephalus increases, right tentorial bleed

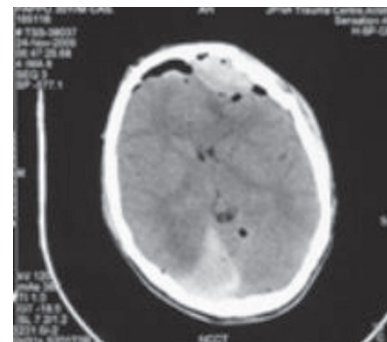


Fig 3: Repeat NCCT head showing decrease in pneumocephalus, and tentorial subdural hemorrhage

Address for correspondence:

Dr Deepak Gupta MS, M.Ch
Assistant Professor Neurosurgery (AIIMS)
Room No 308, 3rd Floor, J.P.N Apex Trauma Centre, AIIMS,
Raj Nagar, New Delhi-110029 E mail: drdeepakgupta@gmail.com

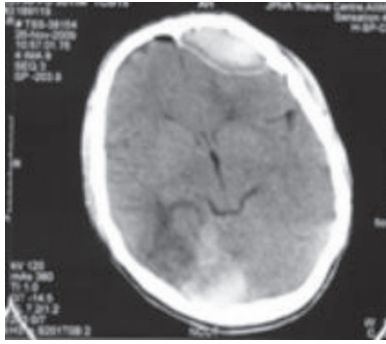


Fig 4 : Repeat NCCT head showing almost resolution of pneumocephalus & right tentorial subdural hemorrhage

DISCUSSION

Traumatic extradural hematoma (EDH) constitutes 1 to 4% of all head injuries¹. Epidural hematomas are contact injuries resulting from blunt trauma to the skull and meninges associated with linear fracture in 30-90 per cent cases. It is thought that the initial impact, with deformation or fracturing of the cranium produces detachment of the dura directly beneath the site of the blow and injures blood vessels (most commonly branches of the middle meningeal artery). Experimental evidence indicates that arterial bleeding into the resulting pocket creates a hydraulic “water press” effect, progressively stripping away the dura from the skull and widening the perimeter of the hematoma. Most traumatic epidural hematomas become rapidly symptomatic, but cases of delayed radiographical and clinical appearance of these lesions have also been documented². Fracture of structures containing air involves the possibility of contamination of the epidural hematoma and an increase in the possibility of pneumocephalus & delayed mass effect³ as was noticed in the present case.

Air in epidural haematoma is not uncommon. It is usually seen if epidural haematoma is associated with fracture involving one of the air sinuses, but can be seen at, times in the absence of any demonstrable fracture on the CT scan⁴. Incidence of air in extradural hematoma varies between 10 -30 %^{5,6}. When EDH is associated with CSF leak and multiple air specs, delayed expansion of EDH may occur⁵ as was noted in the present case.

The contributory factors for delayed extradural hematoma^{7,8} are

1. Hyperventilation
2. Mannitol
3. Pentothal

4. CSF leak (rhinorrhoea or otorrhea)
5. Surgical decompression
6. Shock or low blood pressure

Pneumocephalus occurs in 0.5 to 1.0% of head trauma. Air can gain access into the cranium through a fracture involving a paranasal sinus or the middle ear cavity or more rarely in association with a compound depressed fracture of the vault. Head injury is the most common cause, followed by neoplasm, infection & surgical complications⁹.

Two theories have been proposed for the mechanism behind the development of pneumocephalus. Dandy¹⁰ described a “ball valve” mechanism in which air travels in only one direction. As air enters the cranial cavity, the intracranial pressure rises. The pressure gradient between the atmosphere and intracranial space is therefore reduced, and the osteomeningeal fistula is then tamponaded by brain tissue as was noticed in present case. As a consequence, air is trapped in the intracranial space. The other theory, the “inverted-soda-bottle effect”, was proposed by Horowitz¹¹. He postulated that negative intracranial pressure (ICP) results from excessive loss of CSF through an iatrogenic lumbar drain or settling into the distensible spinal subarachnoid space or simply drainage via normal pathways with physiologic activity such as inspiration or the Valsalva manoeuvre. However, when there are fistulous connections between the intracranial and outer space, air can enter the intracranial space in response to a negative pressure gradient.

Contré coup injury describes contusions at both the site of impact and the tangentially opposite side of the brain. This occurs when the force impacting the head causes the brain to slam to the opposite side of the skull, shearing brain cells. The result is a contusion at the original impact site, and on the opposite side countercoup injury. Contré coup injuries are pathologically similar to coup injuries but are located remote from the point of impact. On impact, the brain moves toward the impact site creating an area of negative pressure directly opposite the impact. Contré coup contusions preferentially occur at the temporal and frontal poles and the Sylvian fissure while the coup contusions occur most commonly at the cerebral convexities. Whether an injury produces a coup or contré coup contusion depends on how much of the impact energy is dissipated by deformation of the skull at the site of impact i.e. a small hard object dissipates most of its energy at the site of impact producing a coup

contusion while a larger object causes less injury at the impact site with most of the energy dissipated by the cessation of head motion favoring countercoup contusions. Coup-contré coup injury is well reported entity but delayed onset contré coup injury has not been reported in literature

CONCLUSION

A rare case of delayed onset counter coup injury in a case of extradural hematoma with associated late onset symptomatic pneumocephalus in minor head injury is presented. The present case highlights the need for repeated neurological examination and CT in management of these patients.

REFERENCES

1. Guillermain P. Traumatic extradural haematomas, in Bigouroux RP (ed): *Advances in Neurotraumatology, Extradural Collections*. Springer-Verlag, 1986, vol 1, pp 2-50
2. Chandrasekaran S, Zainal J. Delayed traumatic extradural haematomas. *Aust NZ J Surg* 1993; 63:780-3.
3. Nobuhiko Aoki. Air in acute epidural hematomas. Report of two cases. *J Neurosurg* 1986; 65:555-6.
4. Tewari MK, Bhatie HS, Thakur RC, Khosla VK, Kak VK, Khandelwal N. Air in Epidural Haematomas. *Australasian Radiology* 1992; 36:127 – 8.
5. Ihm JH. Air Bubble in Acute Extradural Haematomas. *J Korean Neurosurg Soc* 1991; 20:424-9.
6. Shuto T, Kitsuta Y, Yoshida T, Suzuki N, Sugiyama M, Yamamoto I. Clinical study on air in epidural haematomas. *No To Shienkei* 1997; 49:977-81.
7. Alappat JP, Baiju Praveen, Jayakumar K, Sanalkumar P. Delayed extradural hematoma: a case report. *Neurol India* 2002; 50:313-5 .
8. Borovich B, Braun J, Guilburd JN, et al. Delayed onset of traumatic extradural hematoma. *J Neurosurg* 1985; 63: 30-34.
9. Markham JW. The clinical features of pneumocephalus based upon a survey of 284 cases with report of 11 additional cases. *Acta Neurochir (Wien)* 1967; 16:1–78.
10. Dandy WE. Pneumocephalus (intracranial pneumatocele or arocele). *Arch Surg* 1926; 12:949–82.
11. Horowitz M. Intracranial pneumocoele. An unusual complication following mastoid surgery. *J Laryngol Otol* 1964; 78:128–34.