

Unstable dorsolumbar fractures: A prospective series of 94 cases

N Basheer MS, Deepak Gupta M Ch, GD Sathyarthi M Ch, Deepak Aggarwal M Ch, S Sinha M Ch, BS Sharma M Ch, AK Mahapatra M Ch

Department of Neurosurgery, JPNA Trauma Centre, AIIMS, New Delhi.

Abstract: Dorsolumbar trauma is the most common cause of paraparesis or paraplegia. Optimal goals of the management include establishment of a painless, balanced and stable spinal column with vertebral fusion. We reviewed various types of fractures of dorsolumbar spine, their management and outcome in a prospective study of 94 cases of dorsolumbar trauma managed surgically at our centre (Jan 2008 - May 2009). All patients underwent complete neurological examination, CT and MR imaging of the spine. Most common mode of injury was fall from height (66%). Majority of the patients belonged to Frankel grade A (66%). Eighteen patients (19%) were operated using anterior approach and rest by posterior approach. There was no deterioration in neurological status in any of the patients while 26 patients had improvement. Three cases died out of which one was attributed to associated head injury. We conclude that fall from height is the most common cause of dorsolumbar fracture with majority affected belonging to young population and had significant deficits, thus causing significant burden on the society. Surgical management is safe and helps in early mobilization and rehabilitation, thus facilitating possible neurological recovery.

Keywords: dorsolumbar, fracture, paraplegia, transpedicular, rehabilitation

INTRODUCTION

Trauma to the thoracic and lumbar vertebra is one of the most common cause of traumatic paraparesis or paraplegia^{1,2}. These can occur with or without bowel-bladder involvement. Dorsolumbar fractures often cause a neurologic deficit and present a significant economic burden to the family and society. Accepted methods of treatment of dorsolumbar burst fractures include conservative therapy, posterior reduction and instrumentation, and anterior decompression and instrumentation.

Early mobilization and rehabilitation is the most important aim of the management^{1,3}. Majority of the dorsolumbar fractures are unstable. Optimal goals of the management include establishment of a painless, balanced and stable spinal column with fusion of least number of vertebra⁴. The management of dorsolumbar fractures has been the subject of much controversy. There exist different criteria for the choice of the management based on the severity of kyphotic deformity, canal compromise, vertebral height loss, and neurologic status^{1,4,5}. To our knowledge, none of the existing criteria

Address for correspondence:

Dr Deepak Kumar Gupta
Department of Neurosurgery, AIIMS, New Delhi 110029

Manuscript for consideration for best paper award at the 17th Annual Conference of the Neurotrauma Society of India, 06-08 Aug 2009.

for the treatment of dorsolumbar burst fractures are generally accepted.

OBJECTIVE

Objective of the study was to review various types of fractures of dorsolumbar spine, their management and outcome managed by department of neurosurgery, at Jai Prakash Narayan Apex Trauma Centre, AIIMS, New Delhi from January 2008 till May 2009.

MATERIALS AND METHODS

All surgically treated dorsolumbar fractures between January 2008 and May 2009 were reviewed retrospectively. All patients had undergone complete neurological examination, computed tomography scan and magnetic resonance imaging. Clinically Patients were graded using Frankel classification of neurological deficits pre- and postoperatively as follows:

- | | |
|----|---|
| A. | Absent motor and sensory function |
| B. | Sensation present, motor function absent |
| C. | Sensation present, motor function active but not useful (grade 2—3/5) |
| D. | Sensation present, motor function active and useful (grade 4/5) |
| E. | Normal motor and sensory function |

Preoperative plain radio- graphs with sagittal and axial computed tomography (CT) scans were reviewed regarding three separate characteristics of the fracture site.

- 1) The amount of vertebral body actually comminuted by the injury, as best seen in sagittal CT, or lateral plain X-ray.
- 2) The apposition of the fracture fragments, as best seen on axial CT cuts through the fracture site.
- 3) The fractures were categorized to 5 main groups according to mode of injury and pathomorphological uniformity⁶:
 - 1. Compression Fracture
 - 2. Burst Fractures
 - 3. Flexion Distraction Injuries
 - 4. Fracture Dislocations
 - 5. Spondyloptosis

All patients were operated and fixation with fusion was done. Post operatively patients underwent either X-ray or CT and were examined for construct placement, spinal canal decompression and kyphosis correction. All of them were mobilized using dorsolumbar brace from the second postoperative day. Regular physiotherapy was done in all patients after the surgery (Figs 2–4).

Analysis was done using SPSS 13 for windows.

RESULTS

We analyzed all surgically treated dorsolumbar fractures treated by neurosurgery department of this tertiary care trauma centre from January 2008 till May 2009.

Epidemiology: Our patients ranged from 10yrs to 65 yrs (Mean \pm SD 31.5 \pm 12.15) with 71 males and 23 females. Most importantly majority of them belonged to age group of 20- 39 (65%) (Fig 1). Most common mode of injury was fall from height (66 %). Road traffic

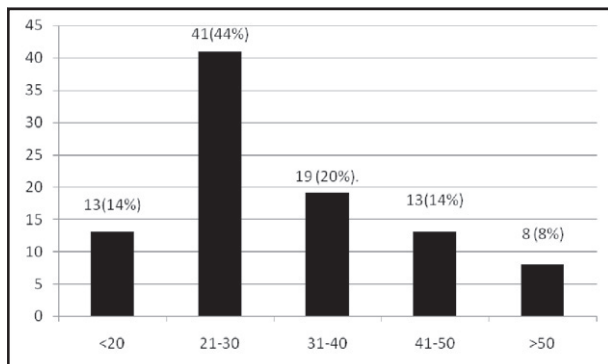


Fig 1: Distribution of age (n = 94)

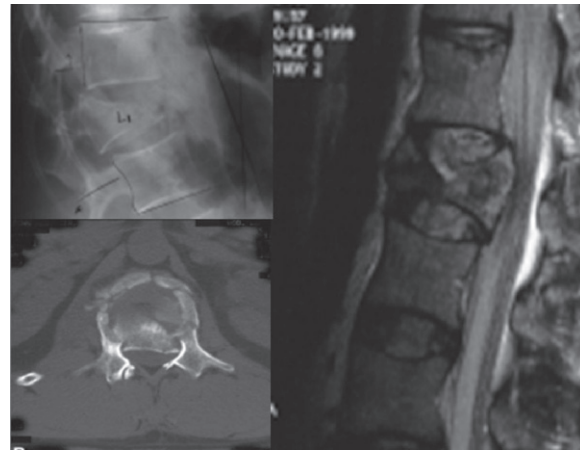


Fig 2: A case of fracture L1, pre op x ray, CT Scan and MRI

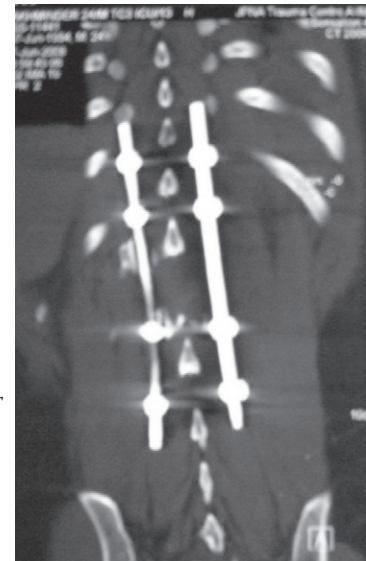


Fig 3: Post operative CT scan of the same patient showing transpedicular rod and screw fixation

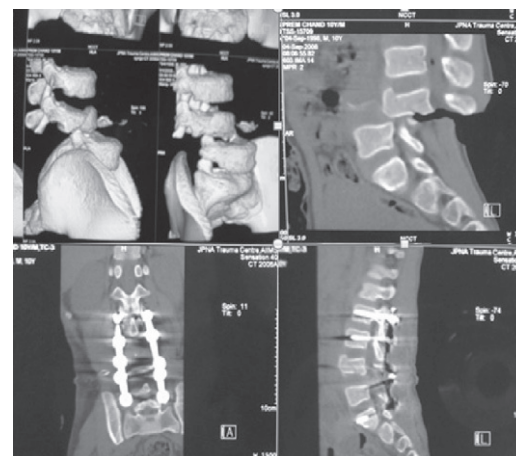


Fig 4: A case of L4-L5 spondyloptosis

accidents accounted for 26 out of which almost all were due to either because of running over by the vehicle or due to high speed acceleration deceleration injury .One patient had fracture due to gunshot injury.

Clinical Profile: Majority of our patient (67%) belonged to Frankel grade A, i.e., complete motor and sensory loss below the injury. Only 20 % of the patients had some useful motor sensory function. Sixty five patients (68%) had bowel bladder involvement. Majority of the patients (90%) had some neurological deficit. Twenty nine patients (32%) had associated systemic injuries (16 out of 35 in high velocity injury compared to 13 out of 59 low velocity injury) with 13 patients having associated head injury. Twenty two patients had multiple level vertebral fractures, (34% and 8 % in high and low velocity group respectively).

Radiology: Most common vertebra involved was L1 vertebral body (36 patients). Common type of fractures were compression and burst fractures both accounting for 26 each (Table 1). There were 7 cases of spondyloptosis. On MR imaging 28 patients (29.8%) showed complete cord transection. Another 43 (45%) showed cord signal changes with 23 (24.3%) showing normal cord.

Surgical Management: Mean duration from injury to surgery was 11 ± 5.6 days. Majority of them (76) were approached posteriorly .Eighteen patients were operated through anterolateral approach. Seven patients were operated through minimally invasive percutaneous screw and rod placement. Short segment fixation was done in 61 patients where as in 33 patients long segment fixation was done. Synthetic graft was used in 42 patients and autologous bone graft was used in remaining 45 patients for fusion. Both anterior and posterior column fusion was done in 20 patients.

Post operative Complications: Most common complication was chest infection (14%). Wound infection was present in 5 patients (6 %). One patient had unilateral vision loss due to prone position. Three

patients developed sepsis with multiorgan dysfunction syndrome. Three patients died in perioperative period, two of them had severe chest infection with sepsis & other one had associated head injury. Four patients had construct failure with screw pullout and had to be operated again.

Early Outcome: Immediate outcome was measured using Frankel grading on post operative day 7. Mean Frankel grading on post operative day 7 was 2.2 ± 1.6 compared to pre operative mean of 1.93 ± 1.4. None of the patient had neurological deterioration. Overall 23 patients had improvement with 12 of them had significant motor improvement. Out of 75 patients belonged to Frankel A- C, 14 patients improved compared to 9 out of 9 in Frankel grade D. But there was no statistical significance for Frankel grade in predicting the improvement of the patient (Table 2). The surprising findings were 3 patients of Frankel grade A also showed improvement in their neurological status.

Fourteen out of 32 (43 %) patients who were operated within 7 days of injury showed improvement compared to 9 out of 62 who were operated after 7 days of injury (Table 3). This figures show that early surgery is beneficial in neurological recovery of these patients. But the P value was not statistically significant (p = 0.16).Our study also showed that there was no correlation of outcome with with the surgical approach (anterior or posterior) preoperative methyl prednisolone, other systemic injury or hypotension (Tables 4 & 5).

Final Outcome: Final outcome was measured at 3 months follow up or at last follow up visit. Mean follow up was 2.3 ± 1.2 with range of 1 to 6 months. Out of 94 patients 34 patients had a follow up of 3 months. Out of 34 patients, 21 (61.6%) showed some improvement,

Table 1

Compression	26 (27.6%)
Flexion distraction	17 (18.1%)
Fracture dislocation	16 (17%)
Burst	28 (29.8%)
Spondyloptosis	7 (7.3%)

Table 2: Correlation of prognosis with Frankel grade on admission

Frankel Grade	Improved	Same	P value
A (n = 63)	3 (4.7%)	60	0.126
B/C(n=12)	11(91.6%)	1	
D (n = 9)	9 (100%)	0	
E (n = 10)	0	10	

Table 3: Correlation with timing of surgery

Duration before surgery	<7 days (N=32)	>7 days (N=62)	P value
improvement	14 (43%)	9 (14.5%)	0.16
Same	18	53	

Table 4: Comparison of anterior and posterior approach & outcome

	Anterior Approach (n=18)	Posterior Approach (n=76)	P value
Improvement	5 (27.78 %)	18 (23.7 %)	0.672(NS)
Same		13	58
Worse		0	0

Table 5: Other prognostic factors

	Improved	Same	P value
Age < 20 (n=13)	3 (23.07%)	10 (77%)	0.763
20-40 (n=60)	14 (24.2%)	46 (75.7%)	
> 40 (n=21)	6 (28.5%)	15 (71%)	
MRI			0.089
Cord Change (n=71)	6 (8.4%)	65 (91%)	
No change (n= 23)	17 (73.9%)	6 (26.1%)	
Single fracture (n=77)	19 (24.6%)	58 (75.4%)	0.912
Multiple fracture (n=17)	4 (23.53%)	13 (76.5%)	
Mechanism of injury			0.84
Low velocity (n=59)	14 (23.72%)	45 (76.3%)	
High velocity (n=35)	9 (25.71%)	26 (74.28%)	
Systemic injury (n=29)	6 (20.6%)	23 (79.3%)	0.231
Hypotension (n=12)	3 (25%)	9 (75%)	0.169
Methyl prednisolone(n=30)	7 (23.3%)	23(76.7%)	0.693

16 (47.5 %) of them showing significant motor improvement. None of the patient had deterioration.

The only factor which was significant in deciding the outcome was pre operative Frankel score, with almost all patients who had preoperative frankel of C, D or E showing improvement (P Value.032). None of the other factors such as age, time of surgery, pre operative hypotension, or other associated injury showed significant association with final outcome. (See Tables 6, 7 & 8)

Majority of the patients (27) were still voiding through urinary catheter. Bedsore was present in 6 (17.6%) patients.

Table 6: Frankel grade and final outcome

Frenkel Grade	Improved	Same	P value
A (n=13)	5 (38.4%)	8	0.032
B/C(n=10)	9 (90 %)	1	
D(n=7)	7(100%)	0	
E(n=4)	0	4	

Table 7: Correlation with Timing of surgery: final outcome

Duration before surgery	< 7 days (N= 11)	> 7 days (N=23)	P value
improvement	8 (72 %)	13 (56.5 %)	0.417
Same	3	10	

Table 8: Other factors in prognosis: final outcome

	Improved	Same	P value
Age <20 (n=5)	3 (60%)	2 (40%)	0.663
20-40 (n=19)	12 (63%)	7 (37%)	
> 40 (n=10)	6 (60%)	4 (40%)	
MRI			0.09
Cord Change (n=27)	16 (59%)	11 (41%)	
No change (n= 7)	5 (71.4%)	2 (29.61%)	
Single fracture (n=21)	17 (80.1%)	58 (19.86%)	0.74
Multiple fracture (n=13)	4 (30.73%)	13 (69.26%)	
Mechanism of injury			0.85
Low velocity (n=23)	14 (60.86%)	9 (39.13%)	
High velocity (n=11)	7 (63.65%)	4 (36.31%)	
Systemic injury (n=10)	4 (40%)	6 (60%)	0.43
Methyl prednisolone (n=7)	3 (42.85%)	4 (58.15%)	0.69

DISCUSSION

Dorsolumbar fractures account for the most common cause of traumatic paraplegia. Most of the affected belong to the productive age group, thus having a major economic burden on the society. The aim of treatment is restoration of function of the patient by creating a healing environment to allow a stable pain free spinal column, with the minimal risk to the patient^{7,8,9}.

The management of fractures in the thoracolumbar region is a controversial subject. Disadvantages of conservative treatment include deterioration in neurological status in 17% of the patients, progressive kyphotic deformity in 20%, persistent backache, decubitus ulcer and deep venous thrombosis. Most of these complications can be avoided by early mobilization and decreased hospital stay by early surgery^{7,9,10}. Patients which we operated ,majority had severe neurological deficits, with our pre op mean Frankel score being 1.93 ± 1.4. This is very low compared to all the studies conducted previously as shown in the table. This could explain the lower percentage of neurological improvement compared to others in our study (See Table 9). As shown with other studies pre operative Frankel score was the single most important factor deciding the neurological outcome^{5,6}. Even though statistically insignificant, greater fraction of patients

Table 9: Management of dorsolumbar spine trauma in the literature

Study	(n)	Mean Frankel grade	Improved	Worse
Patrick w. Hitchon etal ⁸	63	3.7 ± 1.1	23	2
Mohammad F. Butt et al ¹¹	50	2.2± 1.21	24	0
Present study 2009	94	1.93 ± 1.4	23	0

operated within 7 days showed improvement compared to those who were operated after 7 days. As shown by other studies there was no correlation of outcome with the different surgical approaches⁶.

The study showed that almost all patients with incomplete cord injury improved with time. Only factor which was significant in deciding the outcome was preoperative Frankel score, with almost all patients who had preoperative Frankel of C, D or E showing improvement (P Value.032) as shown by other studies as well^{6,7}. Even in complete cord injury the incidence of complication due to immobilization of patients was reduced dramatically with improved quality of life. Thus early surgery can help in rehabilitation and mobilization of patients thus preventing the complications such as decubitus ulcers, chest infection deep venous thrombosis etc. This also makes patients independent on others for their daily activities¹².

CONCLUSION

Fall from height is the most common cause of dorsolumbar fracture with majority affected belonging to young population and presenting with significant deficits, thus causing significant burden on the society. Surgical management is safe and helps in early mobilization and rehabilitation, thus facilitating possible neurological recovery. Long term follow up of patients are awaited.

REFERENCES

- Hassan Dashti, Haw Chou Lee, Eldin E Karaikovic, Robert W. Gaines Jr. Decision making in dorsolumbar fractures. *Neurology India* 2005; 53:Issue 4.
- Denis F. Spinal Instability As Defined by the Three-Column Spine Concept in Acute Spinal Trauma. *Clin Orthop* 1984;189:65-76.
- Denis F. The Three Column Spine and Its Significance in the Classification of Acute Thoracolumbar Spinal Injuries. *Spine* 1983;8:817-31.
- Panjabi MM, Oxland TR, Kifune M, Arand M, Wen L, Chen A. Validity of the Three-Column Theory of Thoracolumbar Fractures. A Biomechanic Investigation. *Spine* 1995;20:1122-7.
- Alvine GF, Swain JM, Asher MA, Burton DC. Treatment of thoracolumbar burst fractures with variable screw placement or Isola instrumentation and arthrodesis: Case series and literature review. *J Spinal Disord Tech* 2004; 17:251-64.
- Gertzbein SD. Spine update. Classification of thoracic and lumbar fractures. *Spine* 1994; 19:626-8.
- Lemons VR, Wagner FC, Montesano PX. Management of thoracolumbar fractures with accompanying neurological injury. *Neurosurgery* 1992; 30:667-71.
- Hitchon PW, Torner JC, Haddad SF, Follett KA. Management options in thoracolumbar burst fractures. *Surg Neurol* 1998; 49: 619-27.
- Rechtine GR II, Cahill D, Chrin AM. Treatment of thoracolumbar trauma: comparison of complications of operative versus nonoperative treatment. *J Spinal Disord* 1999; 12:406-9.
- Hitchon PW, Torner JC. Recumbency in thoracolumbar fractures. *Neurosurg Clin N Am* 1997; 8:509-17.
- Mohammad F. Butt, Munir Farooq, Bashir Mir, et al. Management of unstable thoracolumbar spinal injuries by posterior short segment spinal fixation. *International Orthopaedics* 2007; 31: 259-64.