

Blepharocoele following Head Injury in a Child

Harjinder Singh Bhatoe M S, M Ch

Department of Neurosurgery, Army Hospital (R & R), Delhi Cantt 110010

Abstract: Periorbital swelling is a common accompaniment of head injury. However, blepharocoele is a rare complication of skull base injury involving the orbital roof. We present one 2-year-old child who developed blepharocoele due to orbital rim fracture and basal dural tear. Her vision had remained intact. The lesion resolved completely after surgical repair of the basal dura.

Keywords: blepharocoele, eye injury, head injury, skull base fracture, ocular encephalocoele

INTRODUCTION

Periorbital ecchymosis is a common accompaniment of head injury involving the anterior skull base. CSF collection or brain herniation into the upper eyelid ('blepharocoele') following fracture of the orbital roof is rare, and only six such well documented cases have been reported in world literature so far¹⁻⁶. We report one such case. Relevant literature is briefly reviewed.

CASE REPORT

A two-year-old female child was admitted in a state of altered sensorium after she had sustained head injury in fall from a bicycle. On examination, she was conscious, and had laceration over the right frontal scalp with periorbital ecchymosis. Glasgow coma score (GCS) was 12/15. There was no CSF rhinorrhea. Pupils were normal and there was no focal motor deficit. CT brain showed fracture of the right orbital roof with involvement of orbital rim, and isodense collection in the right upper eyelid (Fig 1), with a small area of hemorrhagic contusion of frontal lobe without any mass effect. There was no injury to the eyeball or retrobulbar hematoma. Child was given antibiotics, cold compresses locally, and was closely observed for deterioration.

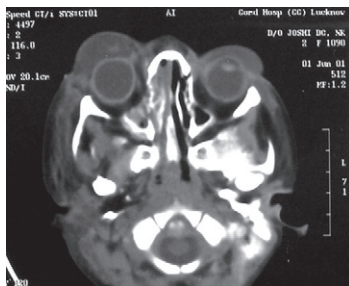


FIGURE 1. NCCT brain showing swelling of right eyelid

Address for correspondence: Harjinder Singh Bhatoe M S, M Ch
Department of Neurosurgery, Army Hospital (R & R), Delhi
Cantt-110010, Tel: 91-11-25668095, Fax: 91-11-25681893
E-mail: hsbhatoe@indiatimes.com; harjinderbhatoe@yahoo.co.in

There was gradual improvement in her sensorium, and GCS improved to 15/15 after 72 hours. She was continent and was able to take oral fluids and semisolids. Meanwhile, swelling of the eyelid had become more apparent and there was chemosis of the conjunctiva (Fig 2). There was mild proptosis, but no pulsations of the globe were noticed. MRI brain showed herniation of brain matter into the right upper eyelid with CSF collection (Fig 3, 4,5). A diagnosis of post-head injury blepharocoele was made and the child was taken up for surgery.

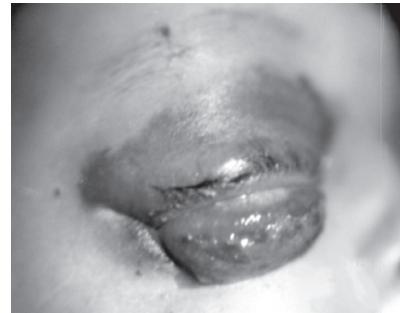


FIGURE 2. Clinical appearance of the right upper eyelid and conjunctiva

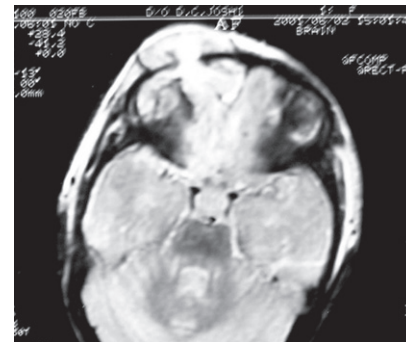


FIGURE 3: MRI (T1WI, axial) showing brain matter herniating under the scalp

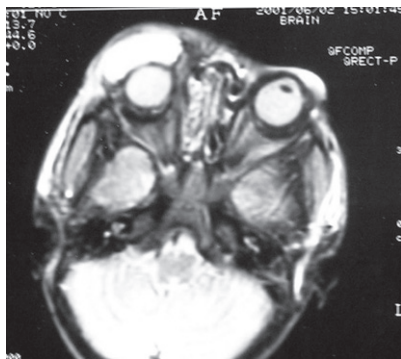


FIGURE 4: MRI (T2WI, axial) showing CSF collection in right eyelid. The eyeball is normal in its position.

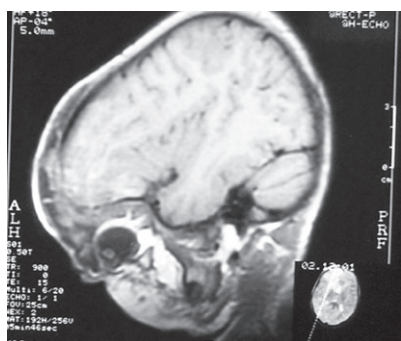


FIGURE 5: MRI (T1WI, sagittal) showing CSF collection in the right upper eyelid

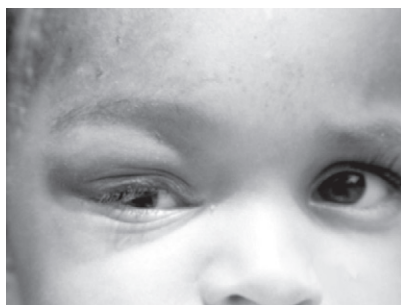

FIGURE 6: Postoperative appearance

Right frontobasal region was exposed by a bicoronal scalp flap and right frontal craniotomy. Multiple dural tears with pulped brain matter were seen on lifting the comminuted bone fragments. There was fracture of the orbital rim, through which brain matter and CSF had herniated into the upper eyelid. Necrotic brain was suctioned out, orbital rim was wired together and basal dura repaired with pericranium. Postoperatively, she was given cerebral decongestants for two days and cefotaxime and amikacin for ten days. Proptosis and blepharocoele gradually resolved thereafter (Fig 4). When reviewed one year later, she was asymptomatic.

DISCUSSION

Head injury with orbital fracture along with dural injury may rarely be associated with leakage of CSF through the orbit ('*CSF orbitorrhea*'), often confused with lacrimation^{7,8}. CSF in such situations may remain trapped in the orbit ('*orbital encephalocele* or *orbitocele*')⁹⁻¹². Rarely, such communication of brain or CSF may lead to the upper eyelid ('*blepharocoele*')^{1-6,13}. Blunt injuries of the superior orbital ridge and facial bones as in a Le Forte type II fracture can also result in CSF collection within the orbit. CSF tracks along the fracture of the cribriform plate through the paranasal sinuses and across the broken lamina papyracea into the orbit, producing periorbital swelling with or without proptosis. Such swelling should be differentiated from an intraorbital hematoma, mucocele, foreign body mucocele and orbital abscess⁷. In cases anterior skull base fracture involving the orbital rim with dural tear and eyelid injury, CSF and pulped brain matter may track into the upper eyelid causing blepharocoele. The rare configuration of this injury can be explained by direct impact to the orbital rim. If the content is only CSF, the eyelid swelling may be transilluminant⁴; transillumination may not be demonstrable in presence of pulped and necrotic brain matter. In an extensive injury to the orbital roof, there may be direct communication of the orbit with the lateral ventricle¹⁴.

Most of the injuries of the orbit associated with orbitocele or blepharocoele have been reported in children^{1,9,10,12}, and adults are rarely affected^{4,5}. An awareness of the lesion is essential to diagnose the condition, and the diagnosis should be suspected when the palpebral swelling does not resolve, or there is persistent 'lacrimation'⁸. There are no sequential changes of resorption of hematoma in the eyelid as seen following periorbital ecchymosis⁴. Proptosis may be seen in patients with fracture of orbital roof with orbitocele. The case reported by Galzio et al² had unilateral agenesis of frontal sinus, and the authors concluded that fracture of the frontal over this region allowed direct egress of CSF into the upper eyelid following head injury. Garza-Mercado et al³ did not find any dural breach in their patient, who was operated upon after three months of injury because of persistent palpebral swelling.

Traumatic CSF collections within the orbit have been evaluated by computed tomography (CT), which shows the fracture involving the orbital roof and rim, frontal and sphenoid regions, intraorbital CSF collection with forward extrusion of the eyeball^{4,12}. MRI is the investigation of choice and should be supplemented by high resolution CT to study the fracture. MRI shows the communication of the brain with the eyelid, especially in T2-weighted

sequence; traction of the anterior horn of lateral ventricle was detected in our patient.

Periorbital swellings following head injury should never be aspirated or incised. After diagnosis, blepharocoele usually requires surgical correction. After exposing the anterior skull base by an appropriately placed craniotomy, pulped and necrotic brain matter is suctioned away to define the torn dural margins and basal fracture. Orbital rim is wired together, and dural repair carried either primarily, or by using a dural substitute. Cerebral decongestants are administered post-operatively, along with antibiotics. There is gradual resolution of swelling, and the cosmetic result is satisfactory.

CONCLUSION

Anterior skull base with orbital rim fracture rarely may be accompanied by CSF loculation within the upper eyelid. Patient usually presents with persistent, non-resolving eyelid swelling. CT may show fracture involving the orbital rim and anterior skull base. MRI is diagnostic, showing herniation of brain matter and CSF into the upper eyelid. Surgical repair of dura and orbital rim is required for resolution of swelling. Cosmetic and functional results of surgery are reported to be excellent.

REFERENCES

1. Bagolini B. Leakage of spinal fluid into upper lid following trauma. *Arch Ophthalmol* 1957, 57:454-456.
2. Galzio RJ, Lucantoni D, Zinobii M, et al. Traumatic craniopalpebral cerebrospinal fistula. *J Neurosurg Sci* 1981, 25:105-107.
3. Garza-Mercado R, Argon-Lomas J, Martinez Garza J, Hernandez L. Cerebrospinal blepharocoele. An unusual complication of head injuries. *Neurosurgery* 1982, 11:525-526.
4. Mathew JM, Haran RP, Chandy MJ. Post-traumatic blepharocoele. *Neurology India* 1997, 45:46-47.
5. Bhatoe HS. Blepharocoele following head injury. *Skull Base* 2002; 12:73-5.
6. Arslantas A, Vural M, Atasoy MA, Ozsandik A, Topbas S, Tel E. Post-traumatic cerebrospinal fluid accumulation within the eyelid: A case report and review of the literature. *Child's Nervous System* 2003; 19:54-6.
7. Salame K, Segev Y, Fliss DM, Ouknine GE. Diagnosis and management of posttraumatic oculorrhea. *Neurosurg Focus* 2000, 9:1-4.
8. Till JS, Marion JR. Cerebrospinal fluid masquerading as tears. *South Med J* 1987; 80:639-40.
9. King AB. Traumatic encephaloceles of the orbit. *Arch Ophthalmol* 1951, 46:49-56.
10. Bhandari Y S. Traumatic orbital pseudomeningocele. *J Neurosurg* 1969, 30:612-614.
11. Greenwald MJ, Lissner GS, Tomita T, Nadich TP. Isolated orbital roof fracture with traumatic encephalocele. *J Ped Ophthalmol & Strabismus* 1987, 24:141-143.
12. Das Laxman, Bhandari S. Isolated orbital roof fracture leading to encephalocele: A case report. In, Khosla VK & Kak VK (eds). *Brain Protection & Neural Trauma*. Narosa Publishing House, New Delhi 2000. pp 316-320.
13. Sibony PA, Anand AK, Keuskamp PA, Zippen AG. Post-traumatic cerebrospinal fluid cyst of the orbit. *J Neurosurg* 1985, 62:922-924.
14. Sato O, Kamitani H, Kokunai T. Blow in fracture of both orbital roofs caused by shear strain to the skull. *J Neurosurg* 1978, 49:734-738.