



# Fetal Flat-Facies on Prenatal Ultrasound: Is it Chondrodysplasia Punctata? A Retrospective Chart Review of 62 Fetuses

Ashwini J. Authreya<sup>1,2</sup>  · Dhruva Rajgopal<sup>3,4</sup> · Adinarayana Makam<sup>1</sup>

Received: 25 August 2021 / Accepted: 17 January 2022 / Published online: 20 April 2022  
© Society of Fetal Medicine 2022

**Abstract** Binder's or flat facies is one of the consistent features of Chondrodysplasia Punctata (CDP). However, it is yet unclear if isolated flat facies is a distinct entity or they represent a milder form of CDP. We aimed to study the prenatal ultrasound features in all fetuses with flat-facies and its association with CDP. We retrospectively reviewed 62 fetuses with flat-facies in the second/ third - trimester for the presence of ultrasound (US) features of CDP. Significant maternal medical history, genetic tests and pregnancy outcomes, where available, were retrieved from hospital records. Forty-one cases had isolated flat-facies, 10 had flat-facies with other structural abnormalities, and 11 had all features of CDP. Epiphyseal stippling was found in all cases of CDP, with the proximal femur being the most common site. The karyotype, chromosomal microarray and clinical exome sequencing data, where available, were reported normal. Maternal systemic lupus erythematosus was positive in one CDP case. About one-third of fetuses with isolated flat-facies and nearly half of the CDP cases chose termination. Although isolated flat-facies may appear as a distinct entity, more post-natal follow-up data is required to ascertain if they are milder forms of CDP. Given the varied genetic and non-genetic

causes of CDP, we formulated a diagnostic approach in fetal flat-facies to aid prenatal detection and counseling of CDP.

**Keywords** Fetal flat facies · Midfacial hypoplasia · Binders phenotype · Chondrodysplasia punctata · Rhizomelia · Clinical exome sequencing · Chromosomal microarray

## Introduction

Binder's facies [1] is described as hypoplasia of the maxilla, resulting in a flat, vertical and short nose with a flattened nasal bridge. The nostrils are semilunar in shape with a short columella. Noyes described the first case of this facial phenotype, and later, Binder reported this as a syndrome in three unrelated children [2]. Binder's facies may be an isolated facial malformation or can be syndromal, most characteristically in Chondrodysplasia Punctata (CDP) [3].

CDP refers to a heterogeneous group of conditions that share certain radiological features detectable by prenatal ultrasound. A consistent feature of CDP that is identifiable by prenatal ultrasound is the flat-facies or Binder's facies (also known as midfacial hypoplasia). Other radiological features of CDP include epiphyseal stippling, premature ossification, short proximal long bones, and vertebral abnormalities. These features occur due to abnormal calcium deposition during enchondral bone ossification.

The finding of flat-facies with or without punctate calcifications on prenatal ultrasound does not constitute a diagnosis but represents a common feature observed in clinically, etiologically and genetically heterogeneous groups of disorders. In most cases, the finding of flat-facies

✉ Ashwini J. Authreya  
dr.ashwini2009@gmail.com

<sup>1</sup> ADI's Advanced Centre for Fetal Care, Rajajinagar, Bangalore 560010, India

<sup>2</sup> Cloudnine Hospital, Kanakapura Road, Bangalore 560062, India

<sup>3</sup> Vishwa Guru Scanning and Diagnostic Center, Gandhinagar, Tumkur 572102, India

<sup>4</sup> Subbaiah Institute of Medical and Dental Sciences, Shivamogga 577201, India

on prenatal ultrasound raises the index of suspicion for CDP. It is yet unclear whether flat-facies in these fetuses is an isolated finding with no other associated genetic/non-genetic abnormalities or represents mild forms of CDP [4]. Therefore, we conducted a retrospective study to characterize the clinical and radiological profile of fetal flat-facies and its association with CDP. As CDP has varied etiology, we review the literature and formulate an approach to a patient with fetal flat-facies.

## Methodology

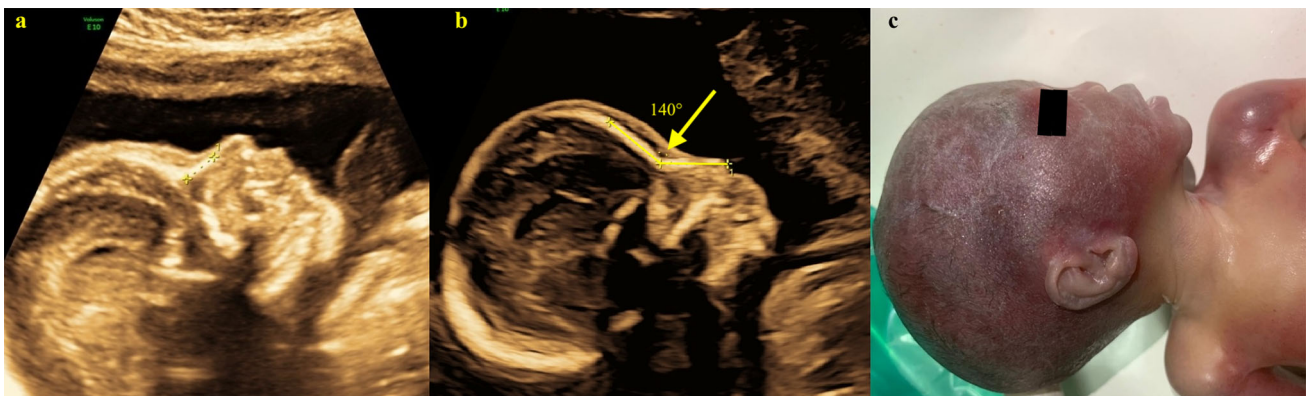
The study was a single-centre retrospective chart review of all fetuses diagnosed with flat-facies in the second/ third trimester from January 2017 to March 2021. Fetuses with a confirmed gestational age from the first-trimester scan were included in the study and had single/ twin pregnancies. All scans were performed on GE Voluson™ E8 and E10 ultrasound systems.

The normal profile of the face is convex (Fig. 1a). The nose and lips lie outside a line joining the nasion and the

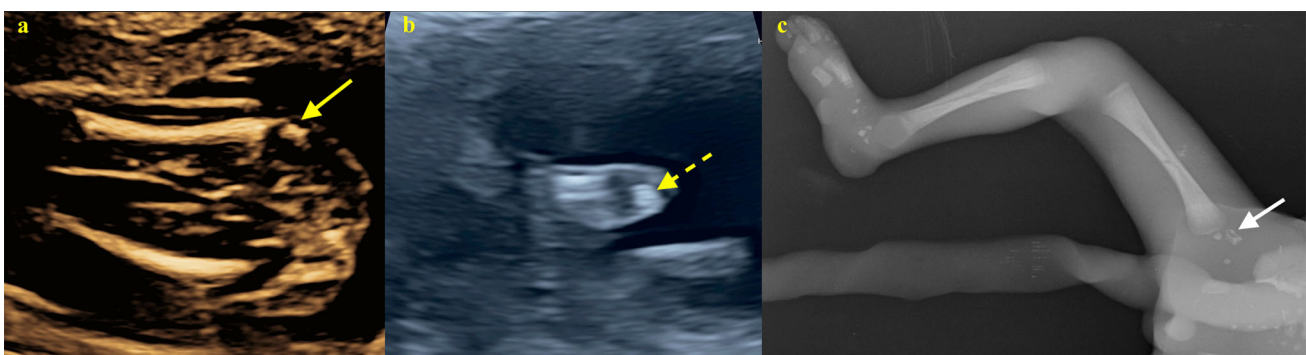
mentum. In fetuses with flat-facies, these structures lie on or inside this line. On a subjective suspicion of fetal flat-facies, the fetal nasofrontal angle (NFA), the angle between the nasal bone and the frontal bone in the midsagittal plane (Fig. 1b), was measured. The 5th and 95th centile for NFA are 117 degrees and 140 degrees, respectively, independent of gestational age [5]. Therefore, we diagnosed fetal flat-facies when the NFA was > 140 degrees.

With a diagnosis of fetal flat-facies, we recorded the presence or absence of the following ultrasound features of CDP: epiphyseal stippling of long bones, rhizomelia, premature ossification of calcaneus and talus, coccygeal calcification, and vertebral stippling. We also recorded the presence of any other structural abnormalities. In addition, maternal history was reviewed for any maternal drug intake like warfarin or phenytoin, features of vitamin K deficiency, hyperemesis gravidarum in early gestation and maternal autoimmune disease like systemic lupus erythematosus (SLE).

The long bone epiphyses do not ossify in fetal life. Rarely, the lower femoral and the upper tibial epiphysis is ossified by 34–36 weeks of gestation [6]. In the second



**Fig. 1** a The normal facial profile, b flat-facies seen in a fetus at 20 weeks of gestation with a nasofrontal angle (solid yellow arrow) of 140 degrees, c The lateral profile of the abortus at 21 weeks showing flat-facies



**Fig. 2** a Proximal femoral stippling (solid yellow arrow) and b calcaneal calcification seen in a fetus at 16 weeks of gestation (yellow dotted arrow), c X-ray of the abortus at 21 weeks of gestation showing proximal femoral stippling (solid white arrow)

trimester, any ossification of long bone epiphysis was recorded as premature epiphyseal stippling (Fig. 2a). Premature ossification of the calcaneus was diagnosed (Fig. 2b) if ossification occurred before 18 weeks, and premature ossification of talus was diagnosed if ossification occurred before 22 weeks of gestation [7].

Vertebral clefts are common in CDP, which may be coronal or sagittal (Fig. 3). The presence of coronal/sagittal clefts was recorded. The vertebral body develops from two chondrification centres at the eighth week of gestation [8] and is described to ossify from one or more ossification centres and begins by ten weeks. The ossification centres are thought to fuse by the second trimester. Arrest in the fusion of the chondrification and ossification centres are likely to be the reason for vertebral clefts [9].

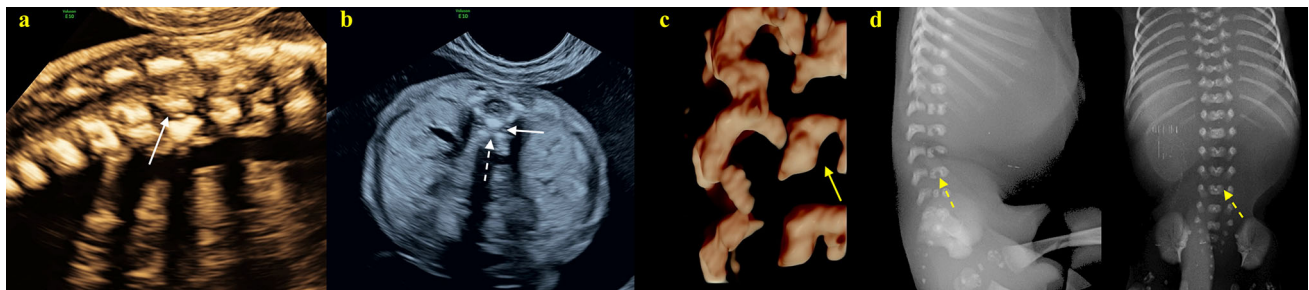
The ossification centres for sacral vertebrae appear on US by 11 weeks for sacral vertebra 1 (S1), 14-weeks for S2, 18-weeks for S3, 21-weeks for S4 and 24 weeks for S5 [10]. S1 is at the intersection of two tangents to the last sacral and lumbar ossification nuclei in the sagittal plane (Fig. 4b). Premature ossification of sacral vertebrae was diagnosed if the sacral vertebrae appeared before the respective gestational age (Fig. 4). Any calcification of the coccyx was considered premature ossification (Fig. 4).

For patients with isolated flat-facies, karyotype and microarray were offered to rule out chromosomal abnormalities. In addition, clinical exome sequencing (CES) was offered to patients with CDP. Genetic test results and follow up data were collected from hospital records in all these patients. Informed consent was obtained for the publication of clinical photographs.

### Results

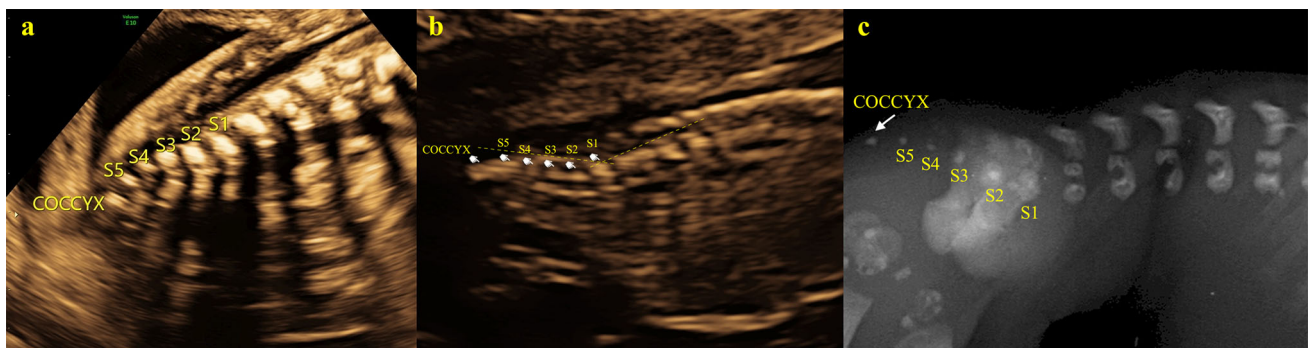
Sixty pregnant women had fetuses with flat-facies, 54 were singletons, and 6 were twins. Five were dichorionic diamniotic (DCDA), and one of the twins had flat-facies in four patients. Both fetuses had flat-facies in the other DCDA case. One was monochorionic diamniotic (MCDA), and both fetuses had flat-facies, making 62 fetuses with flat-facies. The mean age of the mother, the NFA, GA at diagnosis is presented in Table 1.

Of the 62 cases of flat-facies, forty-one were isolated. Eleven of 62 fetuses had CDP. Approximately 6150 second-trimester scans were performed during this period. The incidence of flat-facies was approximately one-per-cent, and the incidence of CDP was 1.7 per 1000 in the second-



**Fig. 3** Vertebral clefts in a fetus at 20 weeks of gestation. Transvaginal scans with **a** sagittal view showing coronal clefts (solid white arrow) and **b** axial view showing coronal (solid white arrow) and sagittal clefts (white dotted arrow). **c** Three-dimensional rendered

view showing coronal clefts (solid white arrow). X-ray of abortus at 21 weeks of gestation with lateral **d** and AP views showing the coronal and sagittal clefts (yellow dotted arrow)



**Fig. 4** Coccygeal calcification is seen in a fetus at 20 weeks of gestation, sacral vertebra S1-5 in **a** transvaginal and **b** transabdominal scans and in **c** X-ray of the abortus at 21 weeks of gestation

**Table 1** Clinical profile and pregnancy outcomes in fetuses with Flat-facies

	Isolated FF <sup>a</sup> (N = 41)	FF with structural abnormalities without CDP (N = 10)	FF with features of CDP <sup>b</sup> (N = 11)
Age of the mother in years, M(SD) [Range]	28.2 (5.6) [18–32]	28.2 (3.7) [23–36]	29.1 (4.4) [22–34]
NFA <sup>c</sup> in degrees, M(SD) [Range]	149.2 (5.7) [140–169]	150.6 (9.6) [140–169]	153.1 (7.5) [141–165]
GA <sup>d</sup> at diagnosis in weeks, M(SD) [Range]	21.1 (2.1) [16–27]	23.3 (2.9) [18–26]	21.2 (3.1) [16–27]
<b>Outcome</b>			
Termination of pregnancy	13	4	6
Live birth	14	2	1
Neonatal death	1	0	0
Ongoing pregnancy	3	0	0
No data available	10	4	4

<sup>a</sup>FF, Flat-facies<sup>b</sup>CDP, Chondrodysplasia punctate<sup>c</sup>NFA, Nasofrontal angle<sup>d</sup>GA, Gestational age

trimester prenatal scan. However, as we are a tertiary centre for fetal medicine, these numbers should be interpreted with caution as there is a high risk for referral bias.

Seven cases of CDP were singletons. CDP was present in one fetus of the DCDA twins in two cases, co-twin with normal facies in one and isolated flat-facies in the other. Both fetuses of the MCDA pair had CDP. In one case, the mother was diagnosed with SLE in pregnancy.

Epiphyseal stippling was present in all eleven CDP cases, and the most common site was proximal femoral stippling present in 10 fetuses. Coccyx calcification was present in 5, vertebral clefts in 2, premature talar ossification in 2, and premature calcaneal ossification in one (Fig. 5). All cases of CDP were non-rhizomelic type at the time of diagnosis with a normal length of long bones. Other structural abnormalities were present in 10 of 62 fetuses and are listed in supplementary table 1.

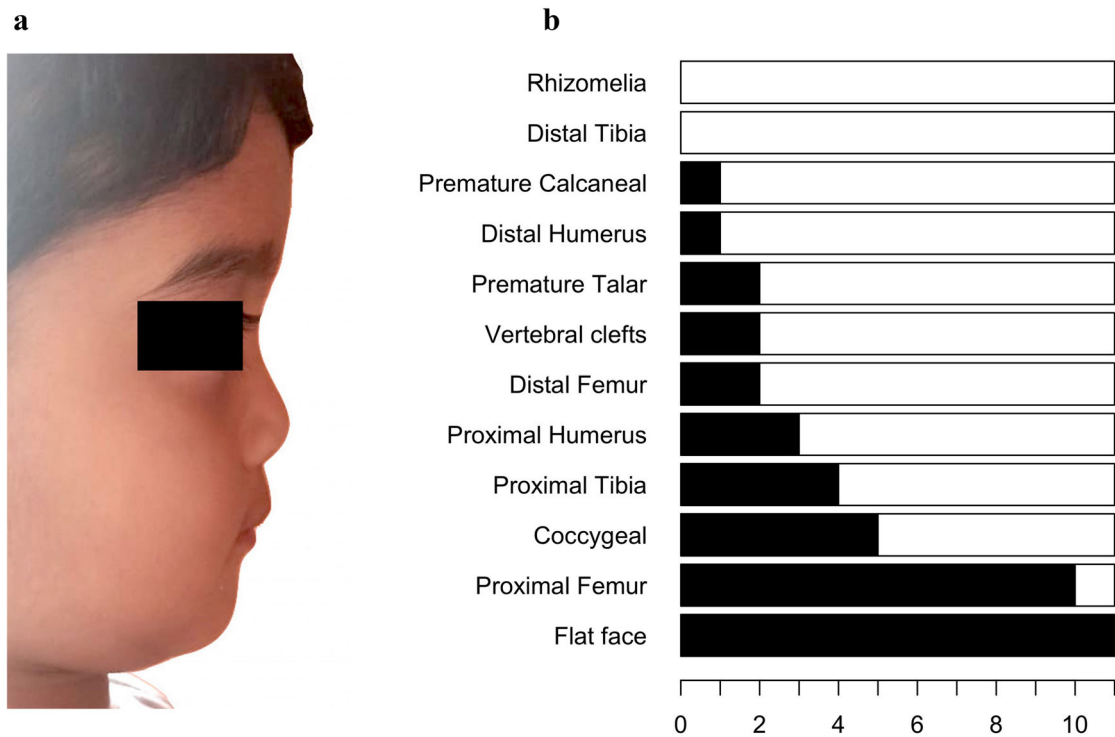
Karyotype and microarray results were available in 18 fetuses with isolated flat-facies, and no abnormalities were detected. Of the ten fetal CDP pregnancies (one MCDA pregnancy where both fetuses had CDP), five chose to do CES, and one opted to terminate the pregnancy without testing. No data on genetic testing was available in the remaining four pregnancies.

In cases of CDP, the clinical and ultrasound features were communicated to the lab with a request to look for associated candidate genes. No pathogenic variants were found in CES in four cases. There was one case with two variants of unknown significance (heterozygous missense variants in FLNB chr3:57994302C > T and MYH3

chr17:10535959G > T). The implications were discussed with geneticists and was thought to be an unrelated variant for the CDP phenotype. Genetic counseling was arranged for the couple. However, regardless of genetic testing results, four out of five couples chose termination of pregnancy. No post-mortem was performed on any fetus. The pregnancy that continued was a DCDA twin where one twin had a flat-face and CDP, and the other had normal facies and no CDP. The above case was the only instance of reported live birth in the CDP group in our series. At the age of 3.5 years, the normal twin had a normal development as told by the parents, and the affected twin was reported to have normal skeletal growth but was diagnosed to have mild 'hyperactivity' but is attending regular schools like his twin brother. The clinical photo of the facial profile of the child is presented in Fig. 5. No radiologic investigations were performed after birth. The outcomes of pregnancy were available in 43 of the 61 cases and are detailed in Table 1.

## Discussion

In this retrospective chart review of 62 cases of fetal flat-facies, we found that most cases have isolated flat-facies (66.1%), and about one-sixth of the cases were associated with CDP. On prenatal ultrasound, epiphyseal stippling is the most common feature of CDP. In our sample, the non-rhizomelic type of CDP is more common than the rhizomelic type. With a diagnosis of CDP, we found that



**Fig. 5** a Facial profile of the child at 3.5 years with prenatal ultrasound features of flat face and Chondrodysplasia punctata. b Frequency of ultrasound features in eleven fetuses with Chondrodysplasia punctata on prenatal ultrasound

many couples chose termination of pregnancy. In isolated cases of flat-facies on ultrasound, there were no other abnormalities reported postnatally.

**Sonological Features of CDP**

After an original description of maxillo-nasal hypoplasia by Binder [11], several workers have described the association of midfacial hypoplasia or flat-facies with CDP and other syndromes [3]. Sheffield and colleagues [4] described the clinical and radiologic features of CDP in the pediatric and adult population, of which midfacial hypoplasia or flat-facies was the most consistent and striking feature. The other radiologic features described by them are punctate calcification of the calcaneus and talus, coronal and sagittal clefts of the vertebral bodies, hypoplasia of distal phalanges, distortion of epiphyses of the femoral head and small stature. Of these, most radiological features are detectable on prenatal ultrasound, as observed in our series. However, we did not have any fetuses with short, long bones and short terminal phalanges. A possible reason for this could be that the short, long bones, short stature, short terminal phalanges could become more evident as gestation advances and skeletal growth proceeds after birth. Evaluating terminal phalanges in the fetus in prenatal ultrasound can be challenging [1] as it is limited by the hand’s position and flexed nature of the phalanges in utero.

Some workers have described Binder’s syndrome as a distinct entity comprising midfacial hypoplasia/ flat-facies and cervical spinal abnormalities [3]. In contrast, others have described it as a milder form of CDP [4]. They argue that other radiological features, such as the epiphyseal stippling, disappear once the ossified epiphysis enlarges sufficiently to include the region of cartilage involved. Our series found that flat-facies was an isolated finding at the time of examination in 66% of cases in the second trimester of pregnancy. In these isolated cases of flat-facies, it is unclear whether epiphyseal stippling can appear later in gestation and disappear again after the baby is born and skeletal development progresses. However, in our series, in three cases diagnosed with isolated flat-facies in the second trimester, follow-up data of ultrasound findings in the third trimester showed no fresh appearance of stippling. In addition, no postnatal abnormalities were reported in the above cases after birth. Thus, whether Binder’s syndrome is genuinely an isolated entity or a mild form of CDP can be determined by more extensive studies that follow cases of prenatally detected isolated flat-facies into adulthood.

**Etiological Classification of CDP**

The etiology and prognosis are varied in CDP cases [12]. At one end of the spectrum are the most severe forms that are lethal prenatally and in early childhood [13], and at the

other end, there are some milder forms with near-average intelligence and life span.

In an updated CDP classification based on etiology, Irving and colleagues have provided a comprehensive classification that can aid clinicians to choose appropriate targeted genetic testing to reach an accurate diagnosis when CDP is detected [12]. As per this classification, the first category is due to inborn errors of metabolism, the second is disruption of Vitamin K metabolism and the third is chromosomal abnormalities. There are few forms of CDP where the etiology is still unknown, like the CDP- Tibia Metacarpal type. The diagnosis is commonly achieved in the first few years of life by the characteristic phenotype [14].

### Inborn Errors of Metabolism Associated with CDP

This category includes three further sub-types based on the pathway involved, including (i) defect in peroxisomal function, (ii) post-squalene cholesterol synthesis, and (iii) lysosomal storage disorders.

*The first IEM subtype with abnormal peroxisomal function* comprises of the Rhizomelic type of CDP (RCDP) and Zellweger syndrome spectrum (ZSS) and are termed as the Peroxisomal Biogenesis disorders (PBD) inherited in autosomal-recessive (AR) pattern. Essential functions of peroxisomes include beta-oxidation of long-chain fatty acids and plasmalogen synthesis. Infants born with Rhizomelic CDP have joint contractures, bilateral cataracts and severe growth, psychomotor and neurodevelopmental delays. Survival beyond the first decade of life is rare in RCDP. There are five types of RCDP based on the various genes involved in peroxisome biogenesis [15].

ZSS shares flat-facies and punctate calcification with RCDP, whereas proximal limb shortening is distinctly absent [16]. In ZSS, one of the 12 different human Peroxisomal Biogenesis Factors is affected. Infants born with ZSS usually do not survive beyond one year of age [17].

*The second IEM subtype with abnormalities affecting post-squalene cholesterol synthesis* comprises of the Greenberg dysplasia [18], an AR disorder associated with Lamin B receptor (*LBR*) gene mutation, the Conradi-Hunermann (CDPX2), an X-linked dominant (XLD) disorder associated with Emopamil Binding Protein (*EBP*) gene mutation and the Congenital Hemidysplasia with Ichthyosiform erythroderma and limb defects syndrome (CHILD) syndrome [19] associated with NSD(P) Dependent Steroid Dehydrogenase-Like (*NSDHL*) gene mutation and which is an XLD disorder. CDPX2 has various clinical features, such as intra- and inter-familial variation and incomplete penetrance due to skewed lyonization of the X chromosome [20]. Therefore, the parent can be an

asymptomatic carrier of the genetic mutation. Studies have shown that cholesterol has a complex role in bone metabolism, and therefore these disorders are associated with skeletal abnormalities.

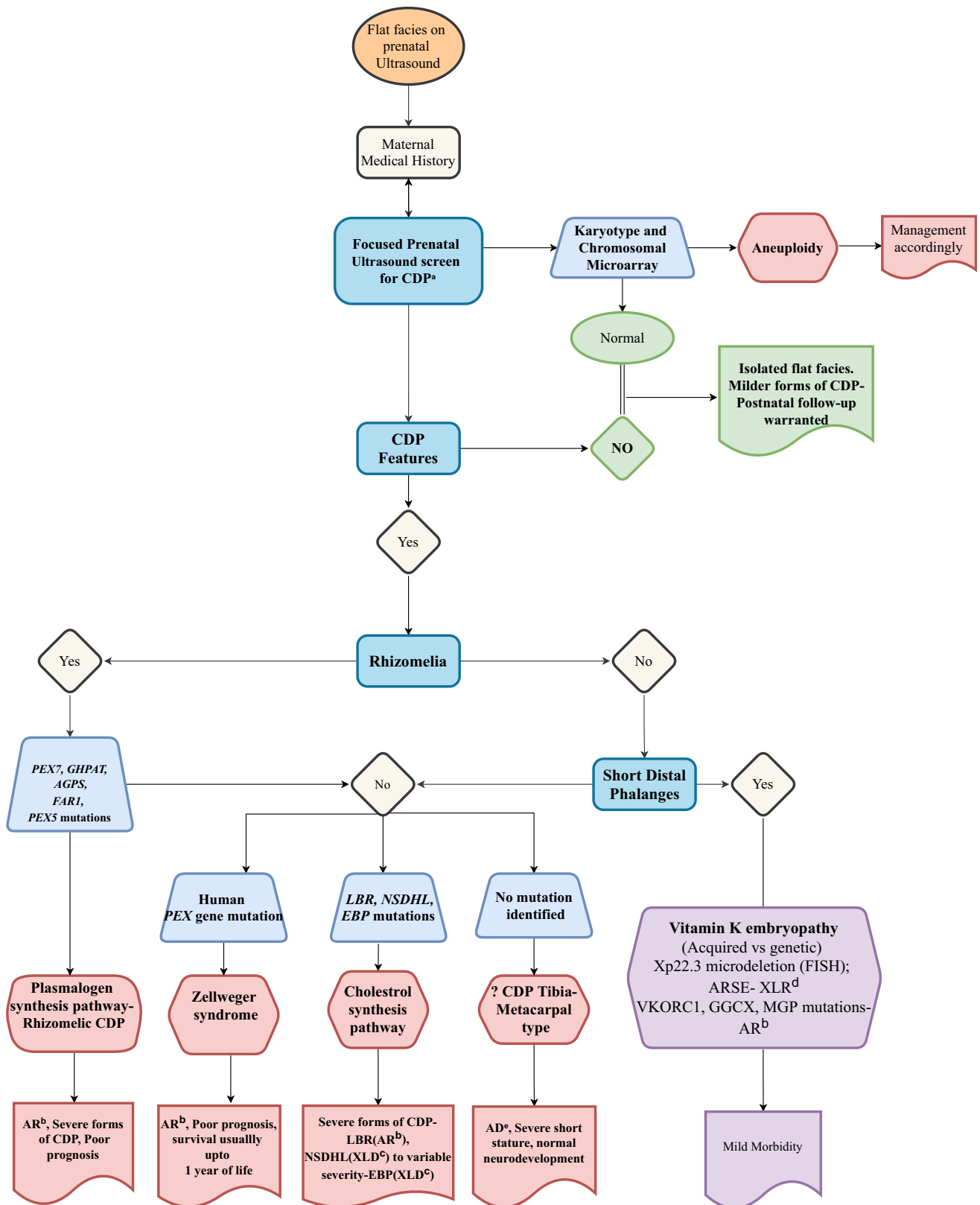
*The third IEM subtype includes the lysosomal storage disorders (LSD).* Stippling can be a feature of these forms of inborn errors of metabolism [12]. Prenatal diagnosis is often achieved after an affected child in a previous pregnancy.

### Disruption of Vitamin K Metabolism

Both genetic and acquired causes that lead to disruption of Vitamin K metabolism can be associated with CDP. Genetic causes include familial multiple coagulation factor deficiency, Keutel syndrome, and Brachytelephalangi CDP (CDP X1). Acquired causes include maternal intake of drugs such as warfarin and phenytoin, maternal Vitamin K deficiency and maternal autoimmune diseases such as SLE. Vitamin K is essential for carboxylation of the matrix Gla protein (MGP) and bone Gla protein (BGP) which inhibit cartilage calcification and bone formation [21]. Deficient carboxylation of these two proteins is possibly responsible for the skeletal and cartilaginous manifestations in CDP.

Familial multiple coagulation factor deficiency is caused by X linked recessive mutations of Vitamin K epoxide reductase (*VKORC1*) and Gamma-glutamyl carboxylase (*GGCX*) genes [12]. The brachytelephalangi CDP is an X-linked recessive form characterized by short distal phalanges, short stature, vertebral abnormalities, midfacial hypoplasia/ flat-facies, mixed conductive and sensorineural hearing loss. Arylsulfatase-A enzyme (*ARSE*) gene mutation is the etiology. Lifespan and intelligence is normal in most affected individuals. Nevertheless, severe morbidity, cognitive delays, and respiratory distress secondary to cervical spinal cord compression are reported [22]. The exact mechanism by which *ARSE* deficiency causes CDP is unknown but is thought to be mediated through disruption of Vitamin K function as warfarin is known to inhibit the activity of *ARSE* in vitro [23]. Keutel syndrome is caused due to autosomal recessive mutations in the *MGP* gene.

Warfarin inhibits Vitamin K epoxide reductase enzyme that converts Vitamin K epoxide to Vitamin K. Phenytoin is thought to cause disrupted Vitamin K activity through Vitamin K epoxide reductase enzyme [21]. Vitamin K deficiency secondary to severe hyperemesis gravidarum in the mother can be associated with flat-facies with or without CDP features in the fetus [24]. The mechanism through which maternal autoimmune diseases cause CDP is thought to be through inhibition of Vitamin K activity by the maternal autoantibodies that cross the placenta and



**Fig. 6** Diagnostic approach for prenatal diagnosis in fetuses with flat-facies. <sup>a</sup>CDP, Chondrodysplasia punctata; <sup>b</sup>AR, Autosomal recessive; <sup>c</sup>XLD, X linked Dominant; <sup>d</sup>XLR, X linked recessive, <sup>e</sup>AD, Autosomal dominant

target the matrix Gla protein, ARSE and the bone Gla protein [25].

### Approach to a Patient with Fetal Flat-Facies

Given the varied etiology and the clinical presentation, we present a diagnostic approach for a case with flat-facies (Fig. 6).

### Conclusion

It is not uncommon to encounter fetal flat-facies on prenatal ultrasound. Isolated flat-facies or Binder's syndrome is a diagnosis of exclusion. Apart from testing for chromosomal abnormalities, active and vigilant search for rhizomelia, epiphyseal stippling, calcaneal and talar ossification, vertebral clefts, and distal short phalanges can identify fetuses with CDP. A thorough maternal history and targeted genetic testing can ascertain the etiology and prognosis in these fetuses. Fetuses with isolated flat-facies generally have a good prognosis. As the prognosis in CDP depends on etiology, counseling depends on the findings in the history and genetic testing.

**Funding** This work did not receive any funding from any government/ non-government agency.

### Declarations

**Conflict of interest** None of the authors has any conflict of interest to declare.

### References

- Blask AR, Rubio EI, Chapman KA, Lawrence AK, Bulas DI. Severe nasomaxillary hypoplasia (Binder phenotype) on prenatal US/MRI: an important marker for the prenatal diagnosis of chondrodysplasia punctata. *Pediatr Radiol*. 2018;48(7):979–91.
- Quarrell OW, Koch M, Hughes HE. Maxillonasal dysplasia (Binder's syndrome). *J Med Genet*. 1990;27(6):384–7.
- Delaire J, Tessier P, Tulasne JF, Resche F. Clinical and radiologic aspects of maxillonasal dysostosis (Binder syndrome). *Head Neck Surg*. 1980;3(2):105–22.
- Sheffield LJ, Danks DM, Mayne V, Hutchinson AL. Chondrodysplasia punctata-23 cases of a mild and relatively common variety. *J Pediatr*. 1976;89(6):916–23.
- Oztürk H, Ipek A, Tan S, YenerÖztürk S, Keskin S, Kurt A, et al. Evaluation of fetal nasofrontal angle in the second trimester in normal pregnancies. *J Clin Ultrasound JCU*. 2011;39(1):18–20.
- Gentili P, Trasimeni A, Giorlandino C. Fetal ossification centers as predictors of gestational age in normal and abnormal pregnancies. *J Ultrasound Med*. 1984;3(5):193–7.
- Goldstein I, Reece EA, Hobbins JC. Sonographic appearance of the fetal heel ossification centers and foot length measurements provide independent markers for gestational age estimation. *Am J Obstet Gynecol*. 1988;159(4):923–6.
- Dias MS. Normal and Abnormal Development of the Spine. *Neurosurg Clin N Am*. 2007;18(3):415–29.
- Wardinsky TD, Pagon RA, Powell BR, McGillivray B, Stephan M, Zonana J, et al. Rhizomelic chondrodysplasia punctata and survival beyond one year: a review of the literature and five case reports. *Clin Genet*. 1990;38(2):84–93.
- Mottet N, Chaussy Y, Auber F, Guimiot F, Arbez-Gindre F, Riethmuller D, et al. How to explore fetal sacral agenesis without open dysraphism: key prenatal imaging and clinical implications. *J Ultrasound Med*. 2018;37(7):1807–20.
- Binder KH. Disostosis maxillo-nasalis, ein arhinencephaler Missbildungscomplex. *Dtsch. Zahnärztlz*; 1962.
- Irving MD, Chitty LS, Mansour S, Hall CM. Chondrodysplasia punctata: a clinical diagnostic and radiological review. *Clin Dysmorphol*. 2008;17(4):229–41.
- White AL, Modaff P, Holland-Morris F, Pauli RM. Natural history of rhizomelic chondrodysplasia punctata. *Am J Med Genet A*. 2003;118A(4):332–42.
- Shukla A, Phadke SR. Chondrodysplasia punctata tibia metacarpal type: report of a 1.5 year old child with severe short stature and extensive calcific stippling. *Clin Dysmorphol*. 2015;24(3):118–21.
- Mortier GR, Cohn DH, Cormier-Daire V, Hall C, Krakow D, Mundlos S, et al. Nosology and classification of genetic skeletal disorders: 2019 revision. *Am J Med Genet A*. 2019;179(12):2393–419.
- Krause C, Rosewich H, Gärtner J. Rational diagnostic strategy for Zellweger syndrome spectrum patients. *Eur J Hum Genet*. 2009;17(6):741–8.
- Johnson JM, Babul-Hirji R, Chitayat D. First-trimester increased nuchal translucency and fetal hypokinesia associated with Zellweger syndrome. *Ultrasound Obstet Gynecol*. 2001;17(4):344–6.
- Gregersen PA, McKay V, Walsh M, Brown E, McGillivray G, Savarirayan R. A new case of Greenberg dysplasia and literature review suggest that Greenberg dysplasia, dappled diaphyseal dysplasia, and Astley-Kendall dysplasia are allelic disorders. *Mol Genet Genomic Med*. 2020;8(6):e1173.
- Porter FD, Herman GE. Malformation syndromes caused by disorders of cholesterol synthesis. *J Lipid Res*. 2011;52(1):6–34.
- Shirahama S, Miyahara A, Kitoh H, Honda A, Kawase A, Yamada K, et al. Skewed X-chromosome inactivation causes intra-familial phenotypic variation of an EBP mutation in a family with X-linked dominant chondrodysplasia punctata. *Hum Genet*. 2003;112(1):78–83.
- Wessels MW, Den Hollander NJ, De Krijger RR, Nikkels PGJ, Brandenburg H, Hennekam R, et al. Fetus with an unusual form of nonrhizomelic chondrodysplasia punctata: case report and review. *Am J Med Genet A*. 2003;120A(1):97–104.
- Braverman NE, Bober MB, Brunetti-Pierri N, Suchy SF. Chondrodysplasia Punctata 1, X-Linked. In: Adam MP, Ardinger HH, Pagon RA, Wallace SE, Bean LJ, Mirzaa G, et al., editors. *GeneReviews®* [Internet]. Seattle (WA): University of Washington, Seattle; 1993 [cited 2021 Jul 16]. Available from: <http://www.ncbi.nlm.nih.gov/books/NBK1544/>
- Matos-Miranda C, Nimmo G, Williams B, Tysoe C, Owens M, Bale S, et al. A prospective study of brachytelephalangic chondrodysplasia punctata: identification of arylsulfatase E mutations,



- functional analysis of novel missense alleles, and determination of potential phenocopies. *Genet Med.* 2013;15(8):650–7.
24. Toriello HV, Erick M, Alessandri J-L, Bailey D, Brunetti-Pierri N, Cox H, et al. Maternal vitamin K deficient embryopathy: association with hyperemesis gravidarum and Crohn disease. *Am J Med Genet A.* 2013;161A(3):417–29.
25. Alrukban H, Chitayat D. Fetal chondrodysplasia punctata associated with maternal autoimmune diseases: a review. *Appl Clin Genet.* 2018;11:31–44.

**Publisher's Note** Springer Nature remains neutral with regard to jurisdictional claims in published maps and institutional affiliations.