



Congenital Intracranial Teratoma—An Intractable Enigma: A Case Report and Review of Literature

Brinda Sabu¹ · Tazeen Khan¹ · Vidyaleshmy R¹ · Naveen Jain²

Received: 25 June 2021 / Accepted: 3 August 2021 / Published online: 31 August 2021
© Society of Fetal Medicine 2021

Abstract Congenital intracranial tumors are rare, accounting for 0.5–1.9% of pediatric tumors. Though antenatal detection rates have improved with ultrasound (US) and MRI, histopathology gives a definite diagnosis. Prognosis is guarded as there is no effective postnatal treatment. We present a fetus incidentally diagnosed with intracranial teratoma by US and MRI at 36 weeks of gestation. Elective cesarean was performed for anticipated labor dystocia. A female baby with head circumference > 99th centile was delivered. Due to the invasive growth potential of the tumor, the baby succumbed at 4 months of palliative care. Further research is required for devising new treatment modalities to tackle this intractable condition.

Keywords Prenatal intracranial tumor · Congenital intracranial teratoma · Fetal MRI · Mature teratoma · Brain neoplasms

Introduction

Hoff et al. were the first to diagnose this abnormality prenatally in 1980 (1). The most common fetal brain tumor is intracranial teratoma followed by glioma. Though the etiology of this condition is not clear, developmental errors

during the embryonic period are said to predispose to these tumors (2), (3). Most fetuses with prenatally diagnosed teratomas die before or shortly after birth. The prognosis worsens with increasing tumor size and decreasing gestational age at diagnosis. Based on several case reports and a population-based study, the most common intracranial tumors and their mortality rates are given in Table 1. The outcome for infants with intracranial teratomas remains guarded despite early detection, advancement in surgical techniques and chemotherapeutic regimens.

Case Report

We report a case of a 30 year old primigravida whose scan at 36 weeks showed both lateral ventricles enlarged upto 30 mm and filled with heterogeneous mass with cystic areas of varying size and minimal vascularity (Fig. 1). Posterior fossa structures were compressed due to the pressure effect of the mass. Her first trimester US, targeted anomaly scan at 20 weeks and growth scan at 32 weeks were normal.

A probable diagnosis of congenital intracranial teratoma was made. Further evaluation with antenatal MRI showed a 10 × 7.5 × 8.5 cm ill-defined supratentorial mass with bilateral intraventricular extension causing hydrocephalus with effacement of bilateral parietooccipital neuroparenchyma suggestive of germ cell tumor (Fig. 2). In light of the immense growth potential of the tumor, the patient was counseled regarding the high risk of malignancy. The need for elective cesarean section in view of large head circumference (> 99th centile), anticipated labor dystocia and immediate postnatal intervention was emphasized. Multidisciplinary inputs were obtained and the parents were also counseled regarding the possible need for early

✉ Brinda Sabu
brinda_sabu@yahoo.co.in

¹ Department of High-Risk Pregnancy and Perinatology, KIMS Health, 1, Vinod Nagar road, Anayara, Trivandrum, Kerala 695029, India

² Department of Neonatology, KIMS Health, 1, Vinod Nagar road, Anayara, Trivandrum, Kerala 695029, India

Table 1 Distribution and mortality rates of the most common intracranial tumors (4–10)

Tumor type	Distribution	Mortality
Teratoma	50%	88%
Ependymoma	25%	91%
Astrocytoma		64–68%
Primitive neuroectodermal tumor (PNET)	25%	88%
Craniopharyngioma		76%
Choroid plexus papilloma		27%

neonatal surgery, risk of mortality and neuromuscular disability which includes hypothalamic and autonomic dysfunction.

A female baby was born by elective term LSCS with normal APGARs and an Occipitofrontal circumference (OFC) of 41 cm (> 99th centile). Postnatal MRI confirmed the antenatal findings of a germ cell tumor–Teratoma

(Figs. 3 and 4). Tumor marker showed elevated AFP–83,970 ng/ml, pointing towards immature teratoma. Surgical intervention was not advised by the oncologists given the high risk of neonatal mortality. After 6 weeks of life, the baby was started empirically on oral Dexamethasone as palliative management because of progressive hydrocephalus and parents' reluctance for surgery based on anecdotal neonatal brain tumor cures.

OFC was rapidly increasing at the rate of approximately 1 cm per week. The baby had poor weight gain and failure to thrive with delay in motor and social milestones. At 3 months of age, she developed a cystic swelling over the left parietal bone with possible tumor invasion. After 4 months of palliative care, she succumbed. Histological diagnosis was not feasible as parents had declined biopsy/surgery and no autopsy was performed. Prenatal USG, MRI and postnatal MRI images are illustrated below.

Fig. 1 (a) 2D US-Axial section of the fetal head at 36 weeks showing echogenic mass with cystic areas filling the ventricles with gross ventriculomegaly and (b) minimal vascularity on color flow mapping

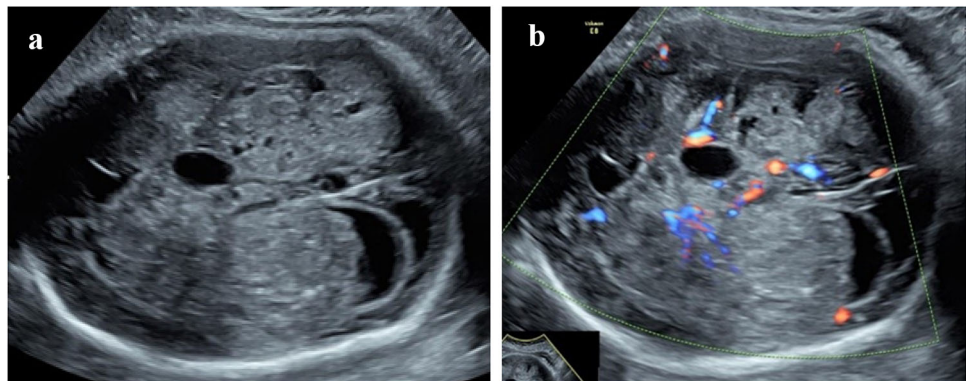
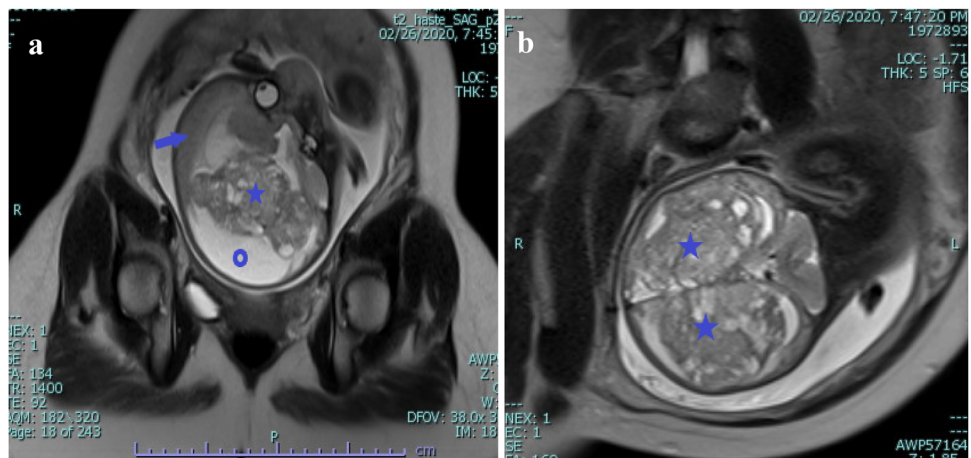


Fig. 2 MRI Sagittal (a) and coronal (b) T2 weighted image of fetal brain showing an ill-defined large supratentorial mass lesion (star) with bilateral intraventricular extension causing obstructive hydrocephalus (arrow) and mass effect on the midbrain and 3rd ventricle which are displaced anteriorly and effacement of bilateral parieto-occipital neuroparenchyma (circle)



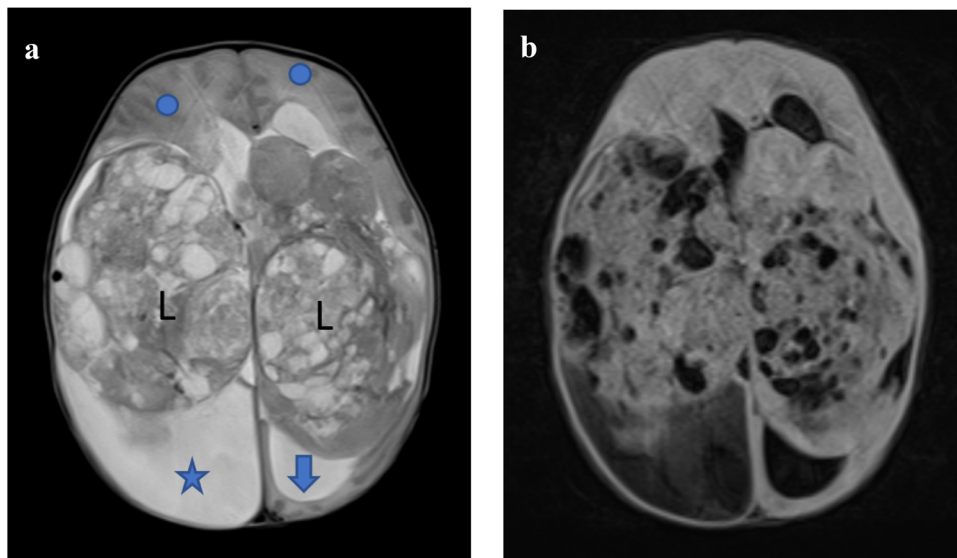


Fig. 3 (a) Axial T2 weighted image of neonatal brain depicting large heterogeneous hyperintense lesion (L) with extension with the lateral ventricles. Large peritumoral cysts (stars) with total rarefaction of the right occipital parietal lobe parenchyma and near total rarefaction in left occipitoparietal lobe parenchyma with subcortical sparing seen.

Gross dilatation of occipital horn of left lateral ventricle (thick arrow). Bilateral frontal and temporal lobe parenchyma show hyperintense T2 signals representing vasogenic edema (circles). (b) Axial FLAIR image shows hypointense lesion within the region of 3rd ventricle with significant dilatation of bilateral lateral ventricles

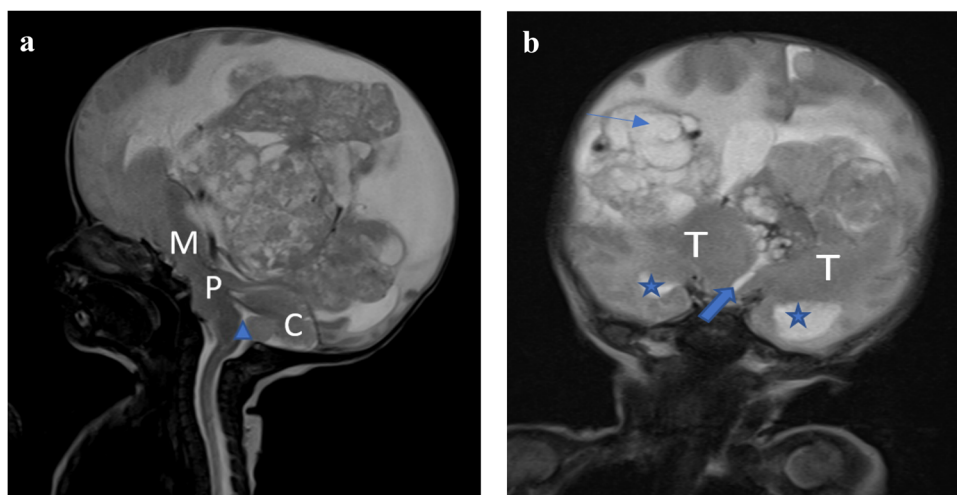


Fig. 4 (a) Sagittal and (b) Coronal and T2-Weighted images of neonate brain show large well-defined irregular heterogeneously hyperintense mass lesion with intralesional (thin arrow) and peritumoral cystic areas noted at posterosuperior aspect of 3rd ventricle (arrow) region causing significant mass effect and anterior

displacement of brainstem structures mainly midbrain (M) and bilateral thalami (T) and capsuloganglionic structures. The cerebellum(C) and 4th ventricle (triangle) appear normal. Coronal image shows dilatation with temporal horns (stars) with vasogenic edema in the surrounding parenchyma

Discussion

Fetal intracranial tumors are rare and account for 0.5%–1.9% of all pediatric tumors with an incidence of 0.34 per million live births. The suspicion of this kind of lesion arises when it is observed as a space occupying mass in the fetal brain. Fetal intracranial tumors are classified into teratomas or nonteratomatous tumors. The nonteratomatous tumors are neuroepithelial tumors like choroid plexus

papilloma, medulloblastoma and astrocytoma; mesenchymal tumors like craniopharyngioma; lipoma of the corpus callosum and tuberous sclerosis (11). Teratomas are supratentorial and contribute to 62% of all congenital tumors diagnosed prenatally (12). Buetow et al. in their review of 45 cases, found that supratentorial tumors account for two-thirds of cases and infratentorial tumors contribute to the remaining one-third (8). Our fetus also had a supratentorial mass with origin from the third

ventricle with infiltration and mass effect on surrounding structures.

The presence of intralesional fat, which is almost pathognomonic for teratomas, is difficult to detect with certainty by prenatal imaging. US-2D imaging is the main modality of diagnosis during pregnancy and the findings include an intracranial mass with solid, cystic or mixed pattern with or without vascularity which can be confirmed by color doppler imaging (1). Other features associated are macrocrania, hydrocephalus, intracranial hemorrhage, epignathus, polyhydramnios, heart failure due to high cardiac output, and hydrops (14). The role of MRI is complimentary and helps to assess the rest of the brain structures, the exact localization of the tumor and differentiating between tumors and hemorrhages (15).

Histopathologically, teratomas are categorized as mature or immature with the former being more common and the latter having a poor prognosis, due to their malignant behavior and early presentation (13). Mature teratomas more often contain cystic components, calcification/mineralization and fat, thus depicting heterogeneous morphology. However, immature or malignant teratomas are usually solid and more homogeneous and can develop necrotic foci and hemorrhage giving a heterogeneous appearance. Most malignant tumors are centrally located, rapidly growing large lesions occupying more than one cranial fossa, resulting in significant destruction of cerebral tissue. Rapidly growing intracranial teratomas can also destroy the cranium, leading to devastating outcomes (9, 16–21). Histopathological confirmation could not be done in our study as the mass was nonresectable. However antenatal as well as postnatal MRI features were suggestive of a malignant nature.

Schwartz S et al. had suggested that karyotyping is not mandatory for all congenital CNS tumors, but should be discussed if other malformations are present (22). Milani HJ et al. in their review article suggested that when an intracranial tumor is suspected, the option for termination of pregnancy should be offered, if legally possible (1). Schlembach D et al. also described that large tumors may be associated with fetal hydrops and in view of anticipated labor dystocia, may necessitate cesarean section for delivery which is seen in 60% of cases (12) including ours.

The prognosis for intracranial teratomas is usually poor and the survival rate is < 10%, mainly dependent on the time of diagnosis and the size of the teratoma (23). These tumors are usually hemorrhagic and hence have limited surgical success. However, adjuvant chemotherapy can be used in immature teratomas when surgical resection is incomplete due to the larger size and involvement of pertinent brain structures (24).

Gkasdaris G et al. reported successful management of an antenatally diagnosed intracranial teratoma where the

neonate underwent right temporal craniectomy and total excision of the tumor (25). Fukuoka et al. suggested that chemotherapeutic treatment diminished the aggressiveness and hemorrhagic nature of the tumor and allowed a complete resection of the tumor. They presented a case of congenital intracranial immature teratoma of the posterior fossa which differentiated into mature teratoma, after completion of 8 courses of neoadjuvant chemotherapy (26). However, surgical/chemotherapeutic intervention was deferred for our baby in view of the immense growth potential of the tumor and her failure to thrive.

Other differential diagnosis include glioma (astrocytoma, ependymoma, oligodendroglioma) Primitive neuroectodermal tumor (PNET), craniopharyngioma, choroid plexus papilloma, neuroblastoma and gangliocytoma. Although 2D/3D US and antenatal MRI help us to suspect the lesion, definitive diagnosis is done only after birth by histology. In general, the prognosis of congenital intracranial teratoma is poor and the diagnosis has a tremendous impact on the family including psychological, social and financial aspects. Multidisciplinary team involvement with inputs from perinatologist, neonatologist, neurosurgeon, oncosurgeon and other involved specialties is essential to counsel the parents regarding prognosis, perinatal management, mode of delivery, surgical treatment, chemotherapy or palliative options.

Implications on Clinical Practice

Congenital intracranial tumors identified prenatally by US are usually diagnosed in the third trimester as an incidental finding. Nevertheless, there is no effective treatment procedure. Many infants succumb even post surgically considering the tremendous invasive potential of the tumor. Early and accurate diagnosis, timely delivery and management in a tertiary centre with multidisciplinary input will help to ensure optimal assistance and support for these infants and the family. Further research and robust studies are required which aim at devising new modalities of treatment and to establish recommendations to tackle this intractable condition.

Authors Contribution All the authors have equally contributed to the article.

Funding No funding was received from any source to support the publication of this case report.

Declarations

Conflict of interest The authors declare that they have no conflict of interest regarding the publication of this case report and review of literature.

Ethics Approval Not required for publication of this case report.

Patient Consent Obtained.

References

- Milani HJ, et al. Fetal brain tumors: prenatal diagnosis by ultrasound and magnetic resonance imaging. *World J Radiol.* 2015;7(1):17–21.
- Court BWM, et al. Incidence of leukaemia after exposure to diagnostic radiation in utero. *Br Med J.* 1960. <https://doi.org/10.1136/bmj.2.5212.1539>.
- Becker LE. Central neuronal tumors in childhood: relationship to dysplasia. *J Neurooncol.* 1995. <https://doi.org/10.1007/BF01052652>.
- Isaacs H. Perinatal (congenital and neonatal) neoplasms: a report of 110 cases. *Pediatr Pathol.* 1985;3:165–210.
- Isaacs H Jr. Congenital and neonatal malignant tumors: a 28-year experience at children hospital of Los Angeles. *Am J Pediatr Hematol/Oncol.* 1987;9:121–9.
- Parkes SE, et al. Neonatal tumors: a 30-year population-based study. *Med Pediatr Oncol.* 1994;22:309–17.
- Lornegan GJ, et al. Neuroblastoma, ganglioneuroblastoma and ganglioneuroma: radiologic pathologic correlation. *Radiographics.* 2002;22:911–34.
- Buetow PC, et al. Congenital brain tumors: a review of 45 cases. *AJR Am J Roentgenol.* 1990;155:587–93.
- Isaacs H. Perinatal brain tumors: a review of 250 cases I. *Pediatr Neurol.* 2002;27:249–61.
- Alamo L, et al. Congenital tumors: imaging when life just begins. *Insights Imaging.* 2011;2:297–308. <https://doi.org/10.1007/s13244-011-0073-8>.
- Volpe J J. Brain tumors and vein of Galen malformation. In: *Neurology of the newborn.* 4th ed. WB Saunders: Philadelphia, 2001.
- Schlembach D, et al. Fetal intracranial tumors detected by ultrasound: a report of two cases and review of the literature. *Ultrasound Obstet Gynecol.* 1999. <https://doi.org/10.1046/j.1469-0705>.
- Desai K, et al. Midline posterior fossa teratoma-case report. *Neurol Med Chir.* 2001;41(2):94–6.
- Pooh R K et al; Antenatal assessment of CNS anomalies, including neural tube defects. In: *Fetal and neonatal neurology and neurosurgery.* 4th ed. Philadelphia: Elsevier, 2009.
- Garel C. MRI of the Fetal Brain: normal development and cerebral pathologies. Berlin: Springer, 2004.
- Cassart M, et al. Fetal intracranial tumors: a review of 27 cases. *Eur Radiol.* 2008;18:2060–6.
- Isaacs H. Fetal brain tumors: a review of 154 cases. *Am J Perinatol.* 2009;26:453–66.
- Washburne JF, et al. Massive congenital intracranial teratoma with skull rupture at delivery. *Am J Obstet Gynecol.* 1995;173:226–8.
- Bolat F, et al. Congenital intracranial teratoma with massive macrocephaly and skull rupture. *Fetal Diagn Ther.* 2008;23:1–4.
- Köken G, et al. Prenatal diagnosis of a fetal intracranial immature teratoma. *Fetal Diagn Ther.* 2008;24:368–71.
- O’Grady J et al; ‘Teeth in the brain’ — a case of giant intracranial mature cystic teratoma. *BMJ case rep* 2012: bcr0320126130
- Schwartz S et al; An unusual mosaic karyotype detected through prenatal diagnosis with duplication of 1q and 19p and associated teratoma development. *Teratology* 1992; 46: 399–404 [PMID: 1384156 DOI: <https://doi.org/10.1002/tera.1420460410>]
- Saada J, et al. Early second-trimester diagnosis of intracranial teratoma. *Ultrasound Obstet Gynecol.* 2009. <https://doi.org/10.1002/uog.6231>.
- Shari G et al; A Massive Congenital Intracranial-orbital Immature Teratoma Tracing Trigeminal Nerve Pathway in One monozygotic Twin: Report of a Case and Review of the Literature. *Journal of neurology and neuroscience* ISSN 2171–6625, 2016, DOI: <https://doi.org/10.21767/2171-6625.100079>.
- Gkasdaris G, et al. Congenital intracranial mature teratoma: the role of fetal MRI over ultrasound in the prenatal diagnosis and the perinatal management. *BMJ Case Rep.* 2019;12: e229774. <https://doi.org/10.1136/bcr-2019-229774>.
- Fukuoka K, et al. Successful treatment of hemorrhagic congenital intracranial immature teratoma with neoadjuvant chemotherapy and surgery. *J Neurosurg: Pediatrics PED.* 2014;13(1):38–44.

Publisher’s Note Springer Nature remains neutral with regard to jurisdictional claims in published maps and institutional affiliations.