




Ultrasonic Diagnosis of Lissencephaly: Literature Review and A Case Report

Shu-Wang Peng² · Ke-Ping Peng³ · Gui-Xiang Tian¹  · Xue-Ying Cao¹ · Ming-Hui Liu¹ · Qing-Yi Dong⁴

Received: 21 June 2021 / Accepted: 12 July 2021 / Published online: 3 October 2021
© Society of Fetal Medicine 2021

Abstract Lissencephaly is a malformation of cortical development associated with deficient neuronal migration and abnormal formation of gyri. The natural course includes developmental delay, mental retardation, epileptic seizures, and microcephaly. Early diagnosis of lissencephaly is very important to give couples reproductive choices. Cranial ultrasonography is often used for the initial evaluation of intracranial abnormalities in fetuses and infants, and we believe that it is a safe and cost-efficient alternative to MRI and CT in many cases. This study

combines a case of lissencephaly in our hospital and related literature review, to explore the clinical manifestations, epileptic seizures and ultrasonographic features of the disease, in order to improve the understanding of the disease.

Keywords Lissencephaly · Imaging examination · Ultrasound

Introduction

Lissencephaly was first described by Owen in 1868 [1]. It is a cortical development deformity, which is caused by abnormal neuronal displacement, which leads to cortical thickening and white matter thinning, and reduced gyration. The migration of neurons from the progenitor zones of the developing central nervous system to form the complex layers within the cortical regions represents an important but incompletely understood, feature of brain development [2]. The development of the fetal central nervous system includes neuroectodermal development (3 ~ 4 weeks gestation), forebrain development (8 ~ 12 weeks gestation), neuronal proliferation (12 ~ 16 weeks gestation), neuronal migration (12 ~ 20 weeks gestation), differentiation and tissue (20 weeks gestation to birth), and myelination [3–6]. Neuronal migration is controlled by a strict genetic program, precise time and space regulation, and studies have found that during pregnancy, many harmful factors such as radiation, infection, and metabolic abnormality may lead to a neuronal migration disorder [7, 8]. Genetic tests may be negative. In addition to external factors, specific genetic mutations are also important causes of neuronal migration disorders, such as *PAFAH1B1* [9] and *DCX* gene defects [7, 8], abnormal

✉ Gui-Xiang Tian
tianguixiang@csu.edu.cn

Shu-Wang Peng
pengshuwang@126.com

Ke-Ping Peng
499192561@qq.com

Xue-Ying Cao
457477165@qq.com

Ming-Hui Liu
liuminghui03@aliyun.com

Qing-Yi Dong
121526545@qq.com

¹ Department of Ultrasonic, The Second Xiangya Hospital, Central South University, Changsha 410011, China

² Department of Gastrointestinal and Thyroid and Vascular Surgery, The First Hospital, Hunan University of Chinese Medicine, Changsha 410007, Hunan Province, People's Republic of China

³ Department of Ultrasound, The First Hospital, Hunan University of Chinese Medicine, Changsha 410007, Hunan Province, People's Republic of China

⁴ Department of Neonatology, The Second Xiangya Hospital, Central South University, Changsha 410011, China

ARX [10], TUBA1A and TUBGCP gene mutation [2, 11], FLNA and ARGEF2 gene mutations [12].

Clinical Manifestation

Although gestation is usually of normal duration or prenatal ultrasound scanning showed bilateral ventriculomegaly. Many infants with lissencephaly are small for gestational age and head circumference at birth varies between 0-7SD [13], the majority within -1SD or -2SD. All patients displayed facial dysmorphism, hypotonia, language impairments, and autistic features; severe psychomotor retardation, seizures, muscle spasticity, and failure-to-thrive [14, 15]. However, these features varied greatly from child to child, depending on the degree of brain malformation and seizure control [16]. For example, recurrent subtle seizures and tonic seizures were the only clinical manifestation in our case during the first few days of life.

Diagnosis and Management

In the past, lissencephaly has been diagnosed mainly at autopsy, by computed tomography (CT) and magnetic resonance imaging (MRI). In previous reports, most lissencephaly cases have been diagnosed via MRI [17, 18]. MRI can provide a more complete and global depiction of cerebral sulci and gyri than can ultrasound, due to its excellent contrast differentiation and multiplanar capabilities, and visibility is not restricted by cranial bones or fetal position [19]. The classic MRI of lissencephaly shows ventriculomegaly, globular and vertically oriented hippocampi, agenesis of the corpus callosum, and severe cerebellar and brainstem hypoplasia. Consistent with a diagnosis of lissencephaly, our patient showed obvious agyria, thickening of gray matter, qualitatively thin white matter, and non-specific ventricular enlargement [20, 21]. In 1983, Babcock [22] showed for the first time that lissencephaly can be diagnosed by real-time head ultrasound, raising the possibility of early diagnosis of this condition by noninvasive techniques. This is important because real-time sonography is often the first screening method for the evaluation of neonatal intracranial disease. Further experience may demonstrate the feasibility of in utero diagnosis of this condition by sonography.

It has been reported that most ultrasound examinations have examined fetuses of different gestational ages to demonstrate the normal cortical structure of this particular gestational age [23, 24]. They have published an ultrasound of fetal cortical development and confirmed prenatal ultrasound can observe the development of fetal sulci and gyri, gestational week and its depth, which provide an

effective basis for prenatal early evaluation of sulcus gyri dysplasia.

However, these studies suggest that the prenatal ultrasound diagnosis of lissencephaly is not possible until 27 ~ 28 weeks, and claim that ultrasound is less accurate in detecting cortical abnormalities than MRI [25]. However, the development of fetal sulci can be observed by prenatal ultrasonography at 16 ~ 19 weeks of gestation, and it can dynamically monitor the development of fetal sulci [26]. In addition, the progressive appearance of cerebral fissures and sulci on prenatal ultrasound images may allow estimation of the extent of brain maturation in a fetus. The absence or abnormal appearance of a particular sulcus at the appropriate fetal age should raise suspicion about the possibility of abnormal or delayed cortical development. Furthermore, fetal neurosonography was compared with MRI diagnosis of brain abnormalities, and it was found that MRI diagnosis of common brain abnormalities was not superior to ultrasound examination [26]. This study demonstrates that both ultrasound and MRI can show the development of the sulci and gyri and, in some cases, the cortical structure can be depicted more quickly by ultrasound.

Electroencephalogram (EEG) is a better predictor of clinical status and outcome, which pattern is associated with severe developmental delay and drug resistant epilepsy [27]. This study found that less severe lissencephaly might appear to be more epileptogenic than severe lissencephaly producing poor clinical correlation. Thus, there is no clear correlation between epileptic seizures and the severity of lissencephaly malformation.

In previous reports, most lissencephaly cases have been definitively diagnosed by MRI [28]. However, cranial ultrasonography is often used for the initial evaluation of intracranial abnormalities in infants, and we believe that in many cases it is a safe and cost-efficient alternative to MRI and CT [28]. Ultrasound examination can not only be carried out in the neonatal period, but also in the fetal period, and early detection of the existence of the malformation can be made. MRI, CT and EEG are complementary to this examination.

There is no cure for lissencephaly. Treatment for children with lissencephaly is symptomatic. However, these features vary greatly from child to child, depending on the degree of brain malformation and seizure control. Seizures may be controlled with medication and hydrocephalus may require shunting [19, 29]. A gastrostomy tube may be considered in patients with feeding difficulty. Since there are no effective therapy options, the prognosis for children with lissencephaly is poor. Aspiration and respiratory disease are the most common causes of illness or death [30].

This study combined a case of lissencephaly in our hospital with related literature review, to explore the

clinical manifestations, epileptic seizures and ultrasonographic features of the disease, in order to improve the understanding of the disease, in order to better diagnose and treat, and to provide a basis for prognosis.

Case Presentation

This report had received informed consent from the patient's family members. All procedures were approved by the Center for Medical Ethics Central South University and followed institutional guidelines.

A 25-day-old term newborn, male and small for gestational age, presented with recurrent subtle seizures and tonic seizures after birth. He was born to a 30-year-old woman, gravida 1 para 1, by vaginal delivery. The pregnancy and delivery were uncomplicated, with Apgar scores of 9 and 9, respectively, at 1 and 5 min. Gestational age was 38 weeks + 5 days.

A diagnostic prenatal ultrasound showed ventriculomegaly during the fetal period. There was no family history of neonatal seizure or epilepsy. The physical examination revealed that the boys' weight (2.085 kg) and head circumference (31 cm) were each in the lower third percentile. There was no fever. Notable neurologic examination findings included paroxysmal generalized hypertonia and absent Moro reflex. Otherwise, the physical examination was unremarkable. There was no obvious dysmorphic anomaly.

The laboratory examination showed a peripheral blood infection, with normal myocardial enzyme and hepatic and renal functions.

Radiographic Appearance and Treatment

CT showed lateral ventricular dilatation at the local county hospital.

The ultrasound examination showed few sulci, thickening of gray matter and thinning of white matter, and bilateral lateral ventricular dilatation (Fig. 1a, white arrow). Most notably, multiple cystic spaces were seen under the ventricular wall and ependyma, and there were diffuse calcifications around the ventricles of the brain (Fig. 1a, black arrow). Color Doppler flow imaging showed a striped-color blood flow signal on the wall of the capsule (Fig. 1b, black arrow). In the coronal section of the ultrasound the bilateral lateral ventricular dilatation can be clearly seen (Fig. 1c, black arrow) and there was a slight hyperechoic group near the choroid plexus in both sides of the ventricle (Fig. 1c, white arrow). We also found that part of the cerebellum vermis was poorly developed (Fig. 1d, black arrow).

A later MRI showed the absence of gyri (agyria), thickening of gray matter, qualitatively thin white matter, and non-specific ventricular enlargement (Fig. 2). An electroencephalogram (EEG) showed irregular burst suppression and delayed maturity (Fig. 3). On interictal EEG the following were noted: delayed maturation, and frontal and temporal regions visible behind the tip region were significantly affected, such as δ brush, hypsarrhythmia, and irregular explosion-suppression. On EEG, there was a continuous release of θ activity from the origin of the right or both sides of the head, a small amount of sharp wave emission in the temporal region, whole brain extensive high amplitude 1–2 Hz activity, and high amplitude slow wave. Moreover, it showed δ -wave complex low amplitude fast motion in the thick cranium.

Finally, the patient was given a clinical diagnosis of early-onset infantile epileptic encephalopathy induced by lissencephaly. That is, severe brain malformation characterized by the lack of normal cortical folds and an abnormally thick cortex with deficient cortical layering. Seizures were treated with phenobarbital but were still attacking at the 1-month follow-up.

Discussion

Real-time cranial ultrasonography is often the first screening method for the evaluation of fetal and neonatal intracranial disease. In addition, it can follow the progression of lesions and can be more valuable than either CT or MR.

For example, our case showed only lateral ventricular dilatation in prenatal ultrasound images, head circumferencences (31 cm) all in the lower third percentile, no facial malformation, no reproductive system malformation and only repeated mild seizures after birth. Postnatal CT examination results were the same as prenatal ultrasound and only found ventricular dilatation and did not indicate abnormal sulcal development. MRI examination was not possible because of repeated epileptic seizures after birth and early cranial ultrasound examination was the only choice. In our case, ultrasound gave more information than MRI, by not only clearly showing the periventricular structures, gray matter thickening, white matter thinning, the dense distribution of spots in the white matter around the ventricle (Fig. 1a, black arrow). This image is very sharp. We consider that the diffuse calcifications around the ventricles are fiber tracts that remain after the abnormal migration of nerve cells. This was first detected on the ultrasound. Ultrasound revealed abnormal periventricular cysts located within the germinal matrix. These are compatible with subependymal cysts/germinolysis (Fig. 1a, b), and may reflect sequela of germinal matrix insult in utero

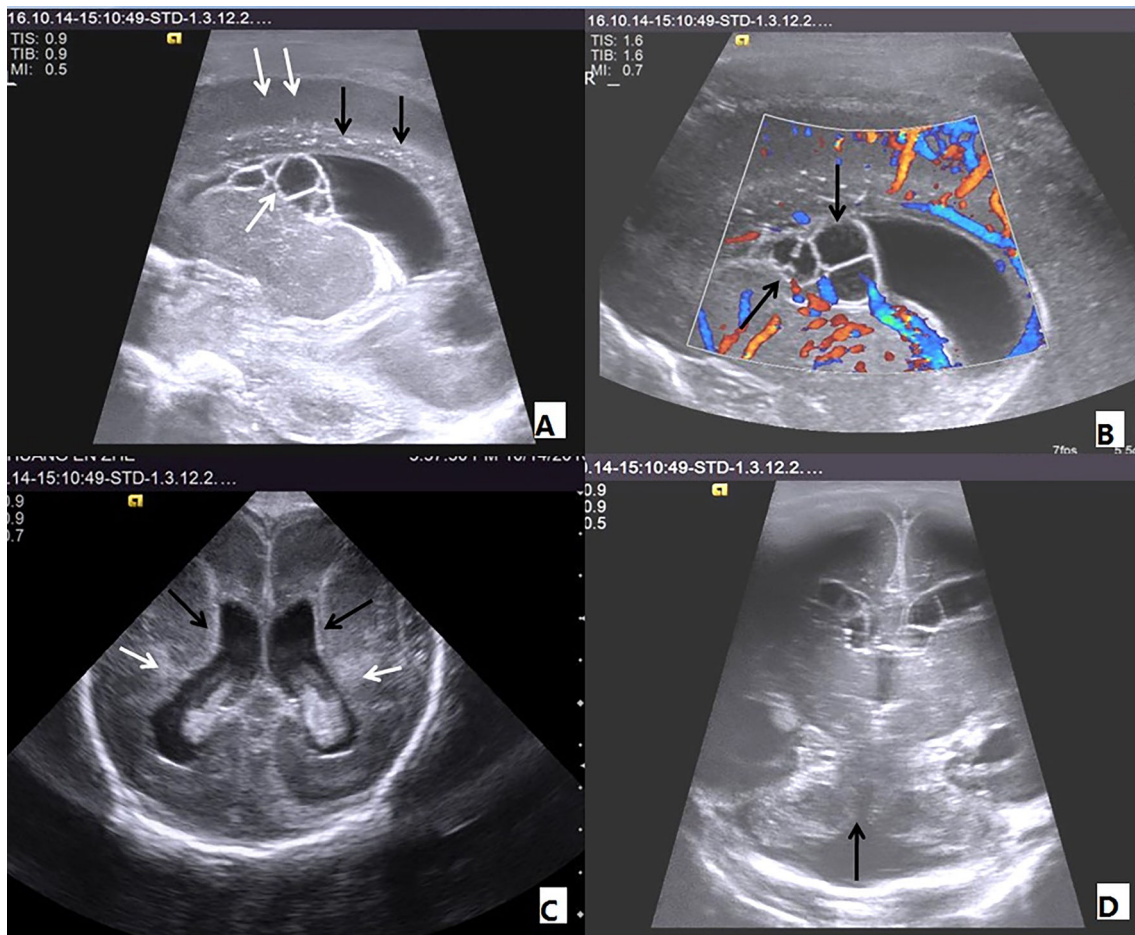


Fig. 1 Cranial ultrasound of a 25-day-old male baby with lissencephaly. **a** Abnormal periventricular cysts located within the germinal matrix and abnormal smooth appearance of the brain with a lack of sulcation (white arrow), consistent with a disorder of neuronal migration such as lissencephaly and diffuse calcifications around the ventricles of the brain (black arrow). **b** Color Doppler flow imaging

showed a striped-color blood flow signal on the wall of the capsule (black arrow). **c** Bilateral lateral ventricle dilation, bilateral ventricle ventral horn (black arrow). There was a slight hyperechoic group near the choroid plexus on both sides of the ventricle (white arrow). **d** Cerebellar vermis with abnormal development (black arrow)

such as ischemia or an infection. We also found a linear echo loss in the vermis of the cerebellum, suggesting partial dysplasia of the vermis of the cerebellum (Fig. 1d). Thanks to the evolution of modern ultrasonic technology, consequent malformations of the brain are detectable on both pre- and postnatal examination with greater frequency. Ultrasonography can be used to provide diagnostic information as sensitively as CT or MRI, especially in the neonatal period. Cranial ultrasound has some advantages for the display of the ventricular system and white matter in the surrounding brain of the newborn and can be applied early and frequently during disease progression, with no radiation and no sedation. Moreover, lissencephaly has characteristic manifestations on ultrasound images. Therefore, through efficient image analysis, cranial ultrasound is beneficial for the early detection of the disease and

its better understanding. It is our belief that familiarity with both the MRI and ultrasonography images of these conditions can be of considerable value for adequate disease management.

Conclusion

Both prenatal ultrasound and MRI have certain characteristic features, which can be combined with the case history, clinical manifestation, laboratory examination, EEG and imaging characteristics to make a diagnosis of Lissencephaly.

There is currently no effective treatment plan for lissencephaly, and the improvement of epilepsy control and intelligence development is poor. Therefore, prenatal

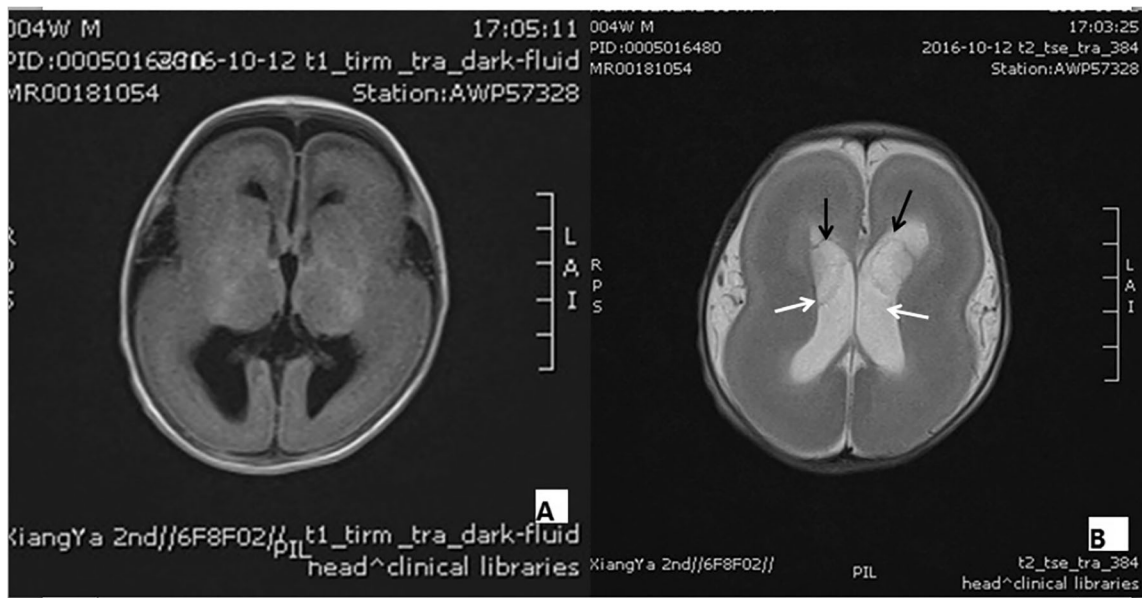


Fig. 2 MRI of the 25-day-old male baby with lissencephaly. **a** There is an overall immature sulcation pattern with thickening of the cortex compatible with lissencephaly generalized throughout the brain.

b Bilateral colpocephaly (white arrow) with no interventricular hemorrhage and abnormal periventricular cysts located within the germinal matrix (black arrow)

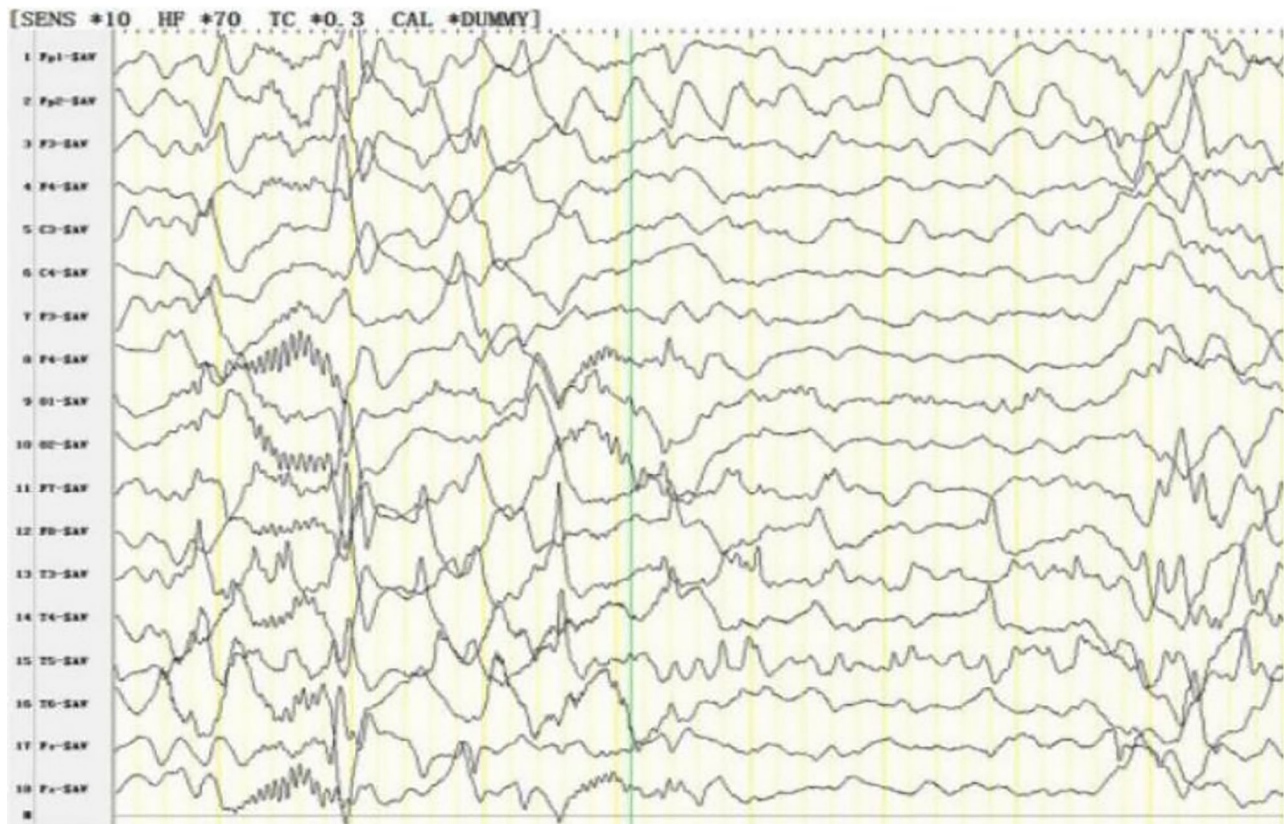


Fig. 3 EEG manifestations of epileptic seizures and interictal seizures in this baby with lissencephaly

ultrasound diagnosis of Lissencephaly is of great clinical and social significance, and can reduce the number of newborns with lissencephaly.

Funding This work was supported by grants from the National Natural Science Foundation of China (Grant No. 82002397).

Declarations

Conflict of interest No potential conflicts of interest relevant to this article were reported.

References

1. Flower WH. On the affinities and probable habits of the extinct Australian Marsupial, *Thylacoleo carnifex*, Owen. *Q J Geol Soc.* 1868;24:307–19.
2. Mitani T, Punetha J, Akalin I, Pehlivan D, Dawidziuk M, Coban AZ, Yilmaz S, Aslan E, Hunter JV, Hijazi H, Grochowski CM, Jhangiani SN, Karaca E, Fatih JM, Iwanowski P, Gambin T, Wlasienko P, Goszczanska-Ciuchta A, Bekiesinska-Figatowska M, Hosseini M, Arzhanghi S, Najmabadi H, Rosenfeld JA, Du H, Marafi D, Blaser S, Teitelbaum R, Silver R, Posey JE, Ropers HH, Gibbs RA, Wiszniewski W, Lupski JR, Chitayat D, Kahrizi K, Gawlinski P. Bi-allelic pathogenic variants in *TUBGCP2* cause microcephaly and lissencephaly spectrum disorders. *Am J Hum Genet.* 2019;105:1005–15.
3. Francis F, Cappello S. Neuronal migration and disorders - an update. *Curr Opin Neurobiol.* 2020;66:57–68.
4. Buchsbaum IY, Kielkowski P, Giorgio G, O'Neill AC, Di Giaino R, Kyrousi C, Khattak S, Sieber SA, Robertson SP, Cappello S: *ECE2* regulates neurogenesis and neuronal migration during human cortical development. *EMBO REP* 2020;21:e48204.
5. Roberts B. Neuronal migration disorders. *Radiol Technol.* 2018;89:279–95.
6. Santana J, Marzolo MP. The functions of Reelin in membrane trafficking and cytoskeletal dynamics: Implications for neuronal migration, polarization and differentiation. *BIOCHEM J.* 2017;474:3137–65.
7. Kolbjør S, Martin DA, Pettersson M, Dahlin M, Anderlid B. Lissencephaly in an epilepsy cohort: Molecular, radiological and clinical aspects. *Eur J Paediatr Neuro.* 2021;30:71–81.
8. Fischl B, Dale AM: Measuring the thickness of the human cerebral cortex from magnetic resonance images. *P NATL ACAD SCI USA* 2000;97
9. Dobyns WB, Das S: *PAFAH1B1*-Associated Lissencephaly/Subcortical band heterotopia. 1993
10. Kitamura K, Yanazawa M, Sugiyama N, Miura H, Iizuka-Kogo A, Kusaka M, Omichi K, Suzuki R, Kato-Fukui Y, Kamiirisa K. Mutation of *ARX* causes abnormal development of forebrain and testes in mice and X-linked lissencephaly with abnormal genitalia in humans. *Nat Genet.* 2002;32:359.
11. Poirier K, Keays DA, Francis F, Saillour Y, Chelly J. Large spectrum of lissencephaly and pachygyria phenotypes resulting from de novo missense mutations in tubulin alpha 1A (*TUBA1A*). *Hum Mutat.* 2010;28:1055–64.
12. Guerrini R, Marini C: Genetic malformations of cortical development., 2018.
13. Yadav S, Rustogi D. Small for gestational age: Growth and puberty issues. *Indian Pediatr.* 2015;52:135–40.
14. Di Donato N, Jean Y, Maga A, Krewson B, Shupp A, Avrutsky M, Roy A, Collins S, Olds C, Willert R: Mutations in *CRADD* result in reduced Caspase-2-Mediated neuronal apoptosis and cause megalencephaly with a rare lissencephaly variant. *Am J Hum Genet* 2016;99
15. Pilu G, Falco P, Gabrielli S, Perolo A, Sandri F, Bovicelli L: The clinical significance of fetal isolated cerebral borderline ventriculomegaly: Report of 31 cases and review of the literature. *Ultrasound Obstet Gynecol* 1999
16. Haverfield EV, Whited AJ, Petras KS, Dobyns WB, Das S. Intragenic deletions and duplications of the *LIS1* and *DCX* genes: A major disease-causing mechanism in lissencephaly and subcortical band heterotopia. *Eur J Hum Genet.* 2009;17:911–8.
17. Alhasan M, Mathkour M, Milburn JM. Clinical images: Postterm newborn with lissencephaly presented with seizure: Case report and review of literature. *Ochsner J.* 2015;15:127–9.
18. Aissa A, Kherifech M, Alouini R, Ouheibi I, Chermy K, Allani A. Genotype and MRI phenotype in classical lissencephaly. *J Neuroradiol.* 2013;40:219–21.
19. Bamba Y, Shofuda T, Kato M, Pooh RK, Tateishi Y, Takanashi J, Utsunomiya H, Sumida M, Kanematsu D, Suemizu H, Higuchi Y, Akamatsu W, Gallagher D, Miller FD, Yamasaki M, Kanemura Y, Okano H. In vitro characterization of neurite extension using induced pluripotent stem cells derived from lissencephaly patients with *TUBA1A* missense mutations. *MOL Brain.* 2016;9:70.
20. Hosny IA, Elghawabi HS. Ultrafast MRI of the fetus: An increasingly important tool in prenatal diagnosis of congenital anomalies. *Magn Reson Imaging.* 2010;28:1431–9.
21. Pugash D, Brugger PC, Bettelheim D, Prayer D. Prenatal ultrasound and fetal MRI: The comparative value of each modality in prenatal diagnosis. *Eur J Radiol.* 2008;68:214–26.
22. Babcock DS. Sonographic demonstration of lissencephaly (agyria). *J Ultrasound Med Offic J Am Instit Ultrasound Med.* 1983;2:465.
23. Cohen-Sacher B, Lerman-Sagie T, Lev D, Malinger G. Sonographic developmental milestones of the fetal cerebral cortex: A longitudinal study. *Ultrasound Obstet Gynecol.* 2006;27:494–502.
24. Toi A, Lister WS, Fong KW. How early are fetal cerebral sulci visible at prenatal ultrasound and what is the normal pattern of early fetal sulcal development? *Ultrasound Obstet Gynecol.* 2004;24:706–15.
25. Greco P, Resta M, Vimercati A, Dicuonzo F, Loverro G, Vicino M, Selvaggi L. Antenatal diagnosis of isolated lissencephaly by ultrasound and magnetic resonance imaging. *Ultrasound Obstet Gynecol.* 1998;12:276–9.
26. Malinger G, Lev D, Lerman-Sagie T. Is fetal magnetic resonance imaging superior to neurosonography for detection of brain anomalies? *Ultrasound Obstet Gynecol.* 2002;20:317–21.
27. Jauhari P, Farmania R, Chakrabarty B, Kumar A, Gulati S. Electrographic pattern recognition: A simple tool to predict clinical outcome in children with lissencephaly. *Seizure.* 2020;83:175–80.
28. Syed AE: A case of lissencephaly in a 5-month-old infant. *Case Reports* 2015;2015:r2014206522.
29. Verloes A, Elmaleh M, Gonzales M, Laquerriere A, Gressens P. Genetic and clinical aspects of lissencephaly. *Rev Neurol (Paris).* 2007;163:533–47.
30. Pavone L, Rizzo R, Dobyns WB. Clinical manifestations and evaluation of isolated lissencephaly. *Childs Nerv Syst.* 1993;9:387–90.

Publisher's Note Springer Nature remains neutral with regard to jurisdictional claims in published maps and institutional affiliations.