



Prenatal Diagnosis of Agnathia/Otocephaly: Associations and Outcomes-Large Case Series and Review of Literature

Brinda Sabu¹ · Vijayalakshmi Raja¹ · Lata Srinivasan¹ · Indrani Suresh¹ · Suresh Seshadri¹

Received: 28 October 2020 / Accepted: 28 November 2020 / Published online: 19 January 2021
© Society of Fetal Medicine 2021

Abstract Agnathia/Otocephaly is a rare lethal syndrome characterised by mandibular hypoplasia/aplasia, ventromedial malposition or fusion of ears, microstomia and microglossia/aglossia. We present 26 cases of prenatally diagnosed agnathia/otocephaly, the largest published series so far, with a broad review of available literature and updated concepts on the etiopathogenesis. This is a retrospective case series identified between May 2000 and April 2018 in a tertiary fetal medicine centre in South India where we evaluated the ultrasound features of agnathia/otocephaly and assessed the associated anomalies and syndromes. Out of 26 cases identified, 42% were isolated and 58% were associated with other anomalies. The most common associations were skeletal (7) followed by central nervous system anomalies (4) and genitourinary anomalies (2). Syndromes identified were Nager acrofacial dysostoses, Treacher Collins, Al Awadi Raas Rothschild and Femoral Facies syndrome. A simple method of observing the mandibular dot in-line with the maxilla in the sagittal view and the absence of the same would help to raise the suspicion of agnathia/severe micrognathia. The difference

between these two and syndromic associations may not be brought out in ultrasound. Postnatal clinical assessment or pathologic diagnosis is mandatory as it helps in the counselling process and in the guidance of subsequent pregnancies.

Keywords Agnathia · Otocephaly · First arch syndrome

Background

Agnathia/otocephaly is an extremely rare lethal anomaly with an estimated prevalence of less than 1 in 70,000 births [1]. Theodor Kerckring, a Dutch physician had made anatomical observations of this condition in his historical notes *Spicilegium Anatomicum* in 1670 [2]. It is characterized by mandibular hypoplasia or agnathia, ventromedial auricular malposition (melotia) and/or auricular fusion (synotia), and microstomia with oroglossal hypoplasia or aglossia [3]. Agnathia is defined as a defect of blastogenesis with structural defects primarily involving the first branchial arch derivatives due to failed mesenchymal migration of the maxillary prominence and atrophy in the development of the mandibular prominences. This embryological insult between the fourth and seventh week of development gives rise to an otocephalic association of abnormalities involving the ears, mouth and mandible [4–7]. These babies have very poor prognoses and may succumb shortly after birth due to respiratory problems if airway management is not appropriate. Hence prenatal diagnosis of agnathia is pertinent, considering the extreme lethality of the condition. It helps in appropriate counseling of parents.

Diagnosis tends to be delayed because of the absence of polyhydramnios in the second trimester. However, due to

✉ Brinda Sabu
brinda_sabu@yahoo.co.in
Vijayalakshmi Raja
vijayalakshmi.raja@gmail.com
Lata Srinivasan
latamurli@gmail.com
Indrani Suresh
drindrani57@gmail.com
Suresh Seshadri
ssmediscan@gmail.com

¹ Place of Study- Mediscan Systems, 197, Dr. Natesan road, Mylapore, Chennai 600004, Tamil Nadu, India

the incorporation of routine midsagittal view for documenting nuchal translucency in the first trimester, more cases are diagnosed earlier. In addition, three dimensional ultrasonography (3D US) helps to depict the facial structures in more detail. In our study, we aimed to evaluate the ultrasound features of agnathia and to assess associated anomalies and syndromes. Figure 1 shows the normal midsagittal view of an 11–14 weeks old fetus where the mandibular dot is seen in line with the maxilla. Figure 2 shows a fetus with agnathia where the mandibular dot is absent.

Materials and Methods

This work is a retrospective case series identified between May 2000 and April 2018 in a tertiary fetal medicine centre in South India. The data was collected from Sonocare database using appropriate search string words agnathia, otocephaly and first arch syndrome. Prenatal diagnosis was based on the US detection of an abnormal profile in the sagittal view of the face in which the mandible was not identified. Observation of the chin and the mandibular dot in line with the proximal tip of the maxilla helped to raise suspicion of agnathia. The position of the ears was imaged in these cases because of the presence of facial abnormalities even though it is not routinely imaged during the targeted scan. Melotia was defined when the ears were seen fused together or too close to each other. Low set ears were defined when the helix is attached to the cranium at a level below that of a horizontal plane with the corner of the orbit [8]. 3D US was used to confirm abnormal findings. Transvaginal US was done in first trimester cases. Details on maternal demographics and ultrasound features were obtained from the database by reviewing reports and images. A three generation pedigree analysis which was done

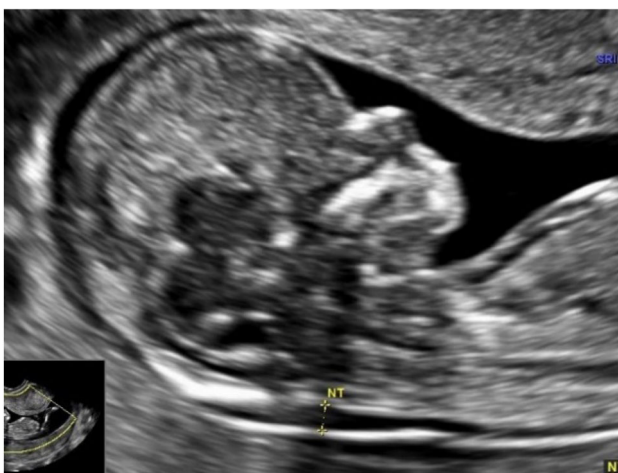

Fig. 1 Fetus showing normal profile view

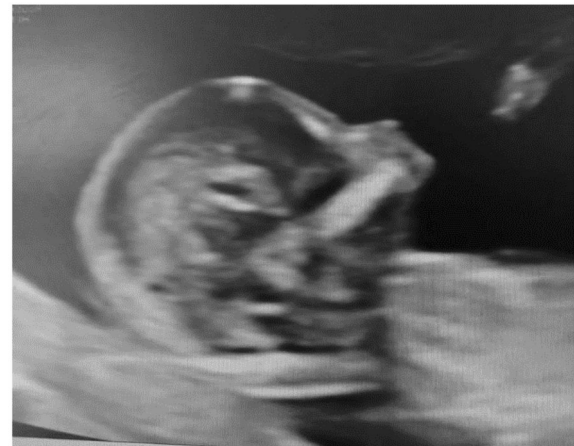

Fig. 2 Fetus showing agnathia

routinely for all patients with congenital anomaly and results of prenatal invasive testing which was offered to patients with agnathia associated with other anomalies were also reviewed. Information about the antenatal course, and perinatal outcome was obtained through telephonic conversations with obstetricians or the patients. Perinatal pathology records were analysed in patients who discontinued the pregnancy.

Results

A total of 26 cases were identified in the above mentioned period. 4, 15 and 7 were the number of cases identified in the first, second and third trimesters respectively. All four first trimester cases were identified after 2008. All the second and third trimester cases were referred for expert opinion or first time late referrals.

The mean gestational age at detection was 23 weeks. Consanguinity was noted in 7 cases. The most common indication for referral was for facial abnormalities and polyhydramnios. 42% (11) of the cases were isolated and 58% (15) were associated with other anomalies. The most common associated abnormalities were skeletal (7) followed by central nervous system (CNS) (4) and genitourinary anomalies (2). There was one case each of situs inversus totalis, congenital diaphragmatic hernia and atrioventricular septal defect. The skeletal anomalies were focal femoral dysplasia, limb hypogenesis, lumbosacral dysgenesis and skeletal dysplasias. Common CNS anomalies were holoprosencephaly and occipital encephalocele. Facial anomalies included bilateral cleft lip/palate and renal anomalies were mainly low placed kidneys. Regarding the location of the ears, 12 were identified to have low set ears, 2 fetuses had melotia, 3 were noted in a normal position, 1 abnormal in appearance and 1 had anotia. In 7 patients the status of the location of

ears was not mentioned due to unreliable prediction in advanced GA and inadequate fetal position.

Information about outcomes was obtained from 23/26 patients. 20 (87%) underwent termination of pregnancy, 2 had preterm delivery out of which one was a stillbirth and the other one succumbed on day 2. One baby who was delivered full term, was diagnosed with Treacher Collins syndrome clinically and by postnatal Xrays, succumbed at 2½ months of age. Out of 20 patients who underwent termination of pregnancy, 11 fetuses had perinatal pathology examination. Four were confirmed as agnathia. Though US had reported the absence of mandible in all these cases, fetogram identified the presence of a hypoplastic mandible in 7 cases changing the diagnosis to severe micrognathia. Syndromes identified by clinical phenotype, US, pathology and fetogram were Nager acrofacial dysostoses, Treacher Collins, Al Awadi Raas Rothschild and Femoral facies syndrome.

Detailed summary and features of the 26 cases are given in Table 1. The images of these fetuses are shown in Figs. 3–16. Figures 3–8 show agnathia and Figures 9–14 show severe micrognathia diagnosed by USG and pathology. A review of the literature was also performed through a computerized search of the PubMed/ MEDLINE database combining the terms “agnathia,” “otocephaly,” “first arch syndrome” and “case series” without restrictions of language and dates. Studies were identified and compared.

Discussion

The etiology of agnathia-otocephaly is clearly classified as a consequence of genetic and teratogenic factors. The genetic basis of agnathia-otocephaly is attributed to gene mutations in the paired related homeobox genes (PRRX1) [9] and unbalanced translocation involving chromosomes 6p24 and 18p11.2 [10]. Orthodenticle homeobox-genes (OTX2) also play an important role in determining the length of the mandible during development thus modifying the severity of mandibular atrophy in otocephaly [11]. A familial autosomal recessive transmission of the condition also has been explained in the literature [3, 12]. Using genetically engineered mouse models it has been found that aberrant signalling of Sonic hedgehog (SHH), bone morphogenic protein (BMP) and WNT pathways also induce first pharyngeal arch malformations. Unfortunately, these mechanisms are yet to be validated in humans [11]. Teratogens linked to inducing abnormalities of facial development are smoking, alcohol and exposure to radiation [11, 13, 14]. Drugs like streptomycin antibiotics, trypan blue, theophylline, beclomethasone, salicylates, amidopyrine, mycophenolate and phenytoin may increase the risk among pregnancies [15–17].

Leech et al. [18], proposed the classification system of agnathia and its associations as.

1. agnathia.
2. agnathia with holoprosencephaly.
3. agnathia, situs inversus, with visceral anomalies.
4. agnathia, holoprosencephaly, situs inversus, and visceral anomalies.

The most frequent associated malformation is holoprosencephaly, though anomalies in skeletal, genitourinary, and cardiovascular systems including situs inversus have also been reported. In our experience, we had all these associations. Though autopsy examination reclassified the diagnosis as severe micrognathia in 7 cases, studies have shown a considerable overlap between these two conditions. Moreover the subtle difference does not alter the management since both have poor outcomes. We had one case of recurrent agnathia but a detailed pedigree evaluation failed to show any similar cases in the family. No external manifestations were found in the parents. Though invasive testing was offered for agnathia with other anomalies, only one patient had undergone amniocentesis and triploidy was detected which was antenatally suspected because of growth restriction, clenched hands and disproportion of head to trunk.

If severe micrognathia/agnathia is suspected, a systematic and careful search for additional anomalies should be done as it is associated with more than 200 genetic conditions. The differential diagnoses include chromosomal abnormalities, neuromuscular abnormalities, skeletal dysplasia, teratogen exposure and Pierre Robin sequence. Syndromes associated with micrognathia include Deletion 22q11.2, Stickler, Treacher Collins, Goldenhahr, Nager, Miller, cerebrocostomandibular syndrome and the oromandibular limb hypogenesis spectrum [19].

There are no currently available diagnostic genetic tests for pregnancies at risk for agnathia-otocephaly which can assist genetic counsellors in assessing risks and prognostic outcomes [11].

We compared the associations and outcomes of a large case series done by Kajiwara et al. [20]. In this series, there were 22 cases identified prenatally over a period of 39 years by means of various case reports. They suggested that in addition to routine facial screening, mandibular arch screening on the sagittal section of the face in the first or early second trimester may guide clinicians to consider agnathia [20].

Case series by Rodriguez et al. (2018) were reviewed and compared. This was an analysis of 7 cases of agnathia identified in the first trimester by means of 3 case reports and 4 cases from three fetal medicine centres. They concluded that diagnosis of agnathia/otocephaly complex can be confidently done in the first trimester based on an

Table 1 Summary of all 26 cases diagnosed prenatally, their associations and autopsy correlation

S.No	GA	Liquor	USG Diagnosis	Position of ears	Associated anomalies	Pathology diagnosis	Outcome
1	29w3d	P	AGN/OTO/MSA	<u>Melotia</u>	CNS/RENAL	ND	TOP
2	26w	P	AGN/OTO	LSE	Isolated	ND	NO FU
3	21w4d	N	AGN/OTO/MSA	LSE	CNS	ND	TOP
4	20w6d	P	AGN/OTO	LSE	Isolated	ND	TOP
5	30w2d	P	FAS/OTO	LSE	Isolated	ND	Still born
6	17w3d	N	AGN/Triploidy	LSE	IUGR/Cl hands	ND	TOP
7	22w3d	P	AGN/OTO	Melotia	Isolated	Agnathia,Otocephaly	TOP
8	32w3d	P	FAS	LSE	Isolated	ND	NO FU
9	11w5d	N	FAS/MSA	LSE	Facial	Sev retromicrognathia	TOP
10	28w2d	P	FAS	Abnormal	Isolated	ND	Treacher Collin syndrome Died at 21/2 months
11	24w5d	P	AGN/MSA	NA	Skeletal/ Renal	ND	TOP
12	19w5d	N	AGN/MSA	Anotia	Skeletal	Nagers acrofacial dysostoses	TOP
13	20w3d	P	AGN/MSA	N	Skeletal	ND	TOP
14	27w3d	P	AGN/MSA	N	Skeletal	ND	TOP
15	20w5d	N	AGN/MSA	LSE	CDH	Sev. Micrognathia CDH	TOP
16	23w	N	AGN	LSE	Isolated	Agnathia/Otocephaly	TOP
17	29w5d	P	AGN	LSE	Isolated	Sev Micrognathia	TOP
18	18w4d	N	AGN/Short Long Bones	NA	Skeletal	ND	NO FU
19	29w4d	P	AGN	NA	Isolated	ND	NND day 2
20	15w4d	N	AGN/MSA	LSE	CNS,CVS	ND	TOP
21	23w6d	N	AGN	N	Isolated	Sev. Micrognathia	TOP
22	13w5d	N	AGN/MSA	NA	Facial	Agnathia,Cleft Palate	TOP
23	13w2d	N	AGN/MSA	NA	Facial/skeletal	Sev. Micrognathia (FFS)	TOP
24	28w3d	N	AGN	NA	Isolated	ND	TOP
25	20w1d	N	AGN/MSA	NA	CNS/Skeletal	Al Awadi Raas Rothschild/ Sev Micrognathia	TOP
26	13w6d	N	AGN/MSA	LSE	Situs inversus totalis	Agnathia/Situs inversus totalis	TOP

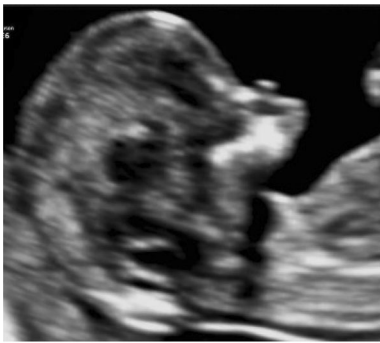GA, Gestational Age; P, Polyhydramnios; N, Normal; Agn, Agnathia; MSA, Multisystem anomaly; FAS, First Arch syndrome; SIT, Situs Inversus totalis; FFS, Femoral facies syndrome; NA, Non available; LSE, Low set Ears; CDH, Congenital Diaphragmatic Hernia; TOP, Termination of pregnancy; NND, Neonatal Death; ND, Not done

examination of the fetal profile and focusing on the abnormally small or absent mandible and this condition should be added to the increasing list of anomalies that can be diagnosed by US in the first trimester of gestation [21]. Our study is the largest case series published so far with 26 cases which were diagnosed prenatally and had information about the outcome in 89%. We had a case of agnathia with situs inversus totalis diagnosed in the first trimester which was confirmed by perinatal pathology and will be the thirteenth case published [3]. Though 4/11 were confirmed by pathology examination as agnathia, we had identified three more syndromes and 1 case of triploidy

antenatally. We had a case of recurrence suggesting a possible genetic etiology. The details of the comparative analysis are given in Table 2:

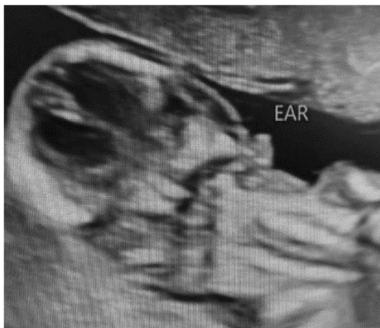Implications for Clinical Practice

Agnathia/ otocephaly complex appears to be a spectrum of lethal disorders ranging from severe micrognathia, retro-micrognathia to complete absence of the mandible (agnathia) and overlap between these have been noted in a small percentage of cases. A simple method of observing



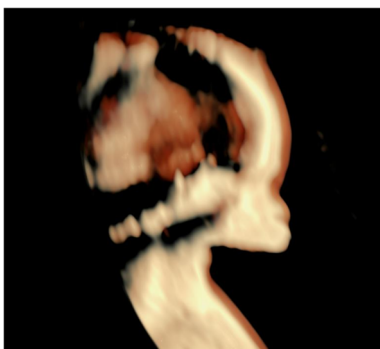
Absent mandible - Agnathia

Fig. 3 Absent mandible—Agnathia



Displaced fused ears-Melotia

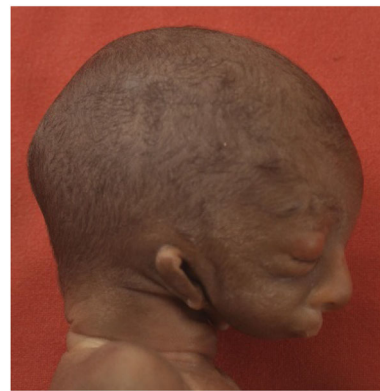Fig. 4 Displaced fused ears-Melotia



3D image of Agnathia

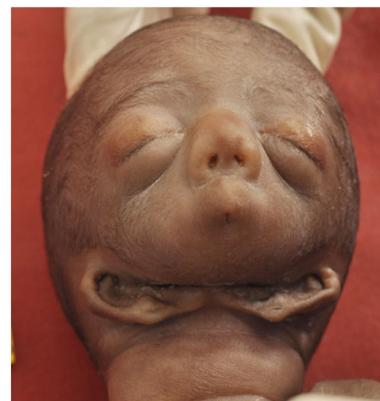Fig. 5 3D image of Agnathia

the mandibular dot in line with the maxilla in the sagittal view as shown in Fig. 1 and the absence of the same as shown in Fig. 2 would help to raise the suspicion of agnathia/severe micrognathia. Absence of the mandible as shown in the coronal plane (the retranasal triangle view) of the face (Fig. 16) will help to clinch the diagnosis. The differentiation between agnathia and severe micrognathia may not be evident on US and postnatal clinical/radiological or perinatal pathologic examination is mandatory. In



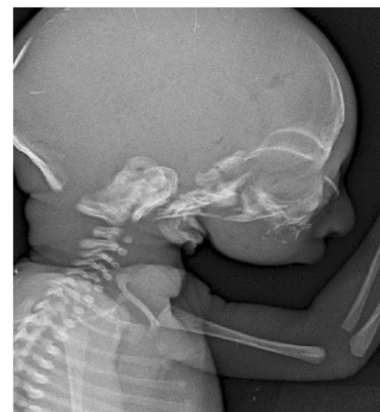Autopsy image-Agnathia

Fig. 6 Autopsy image-Agnathia



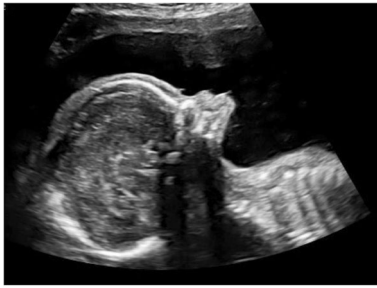Melotia,microstomia

Fig. 7 Melotia,microstomia

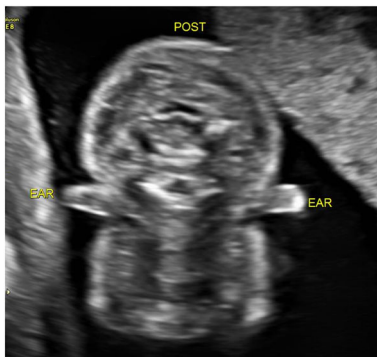


Fetogram-agnathia

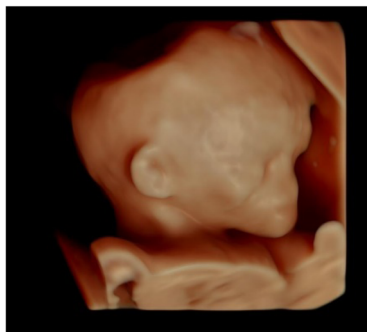Fig. 8 Fetogram-agnathia



Severe micrognathia -profile

Fig. 9 Severe micrognathia-profile

Low set ears

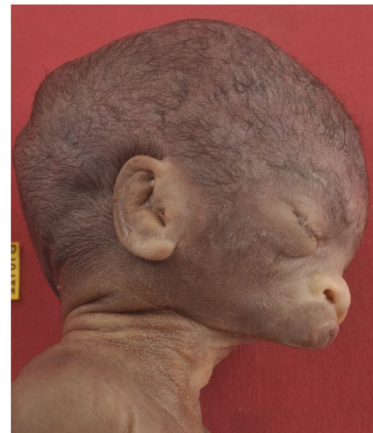Fig. 10 Low set ears

3D image -Severe micrognathia

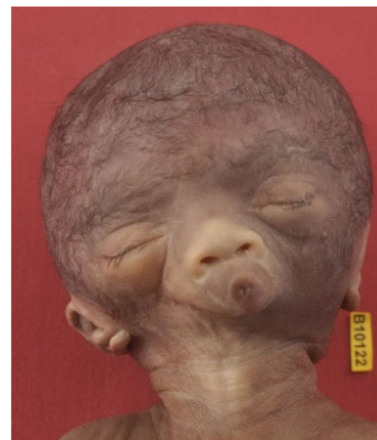Fig. 11 3D image -Severe micrognathia

agnathia, holoprosencephaly which is the most common association [22, 23] can reliably be diagnosed in the first trimester. Considering the rare recurrence of agnathia in certain families, prenatal testing to rule out chromosomal abnormalities along with storage of DNA for further genetic evaluation should be encouraged. This helps in the counselling process and in the guidance of subsequent pregnancies, as the mode of inheritance can be studied only after identifying the genetic syndrome.

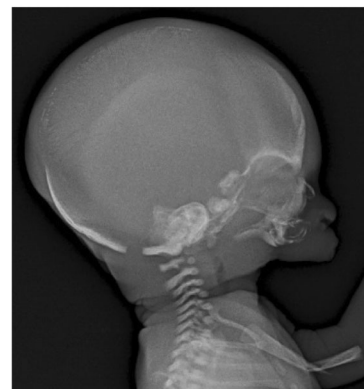
To conclude, agnathia/otocephaly is a rare, essentially lethal disorder. Severe mandibular abnormalities like



Autopsy -Sev micrognathia

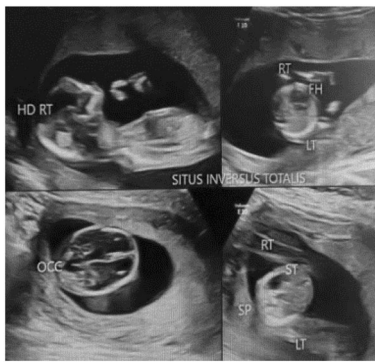Fig. 12 Autopsy -Sev micrognathia

Low set ears

Fig. 13 Low set ears

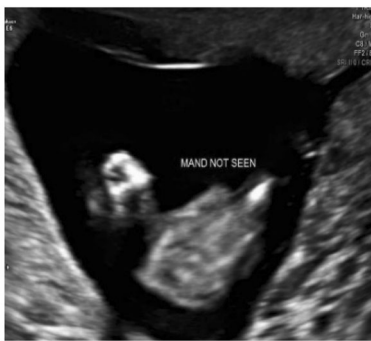Fetogram- presence of hypoplastic mandible

Fig. 14 Fetogram- presence of hypoplastic mandible



Situs inversus totalis

Fig. 15 Situs inversus totalis



Absent mandible in retranasal triangle view

Fig. 16 Absent mandible in retranasal triangle view

micrognathia are more common than complete absence of mandible. These conditions should be identified in the first trimester and attempts should be made to locate the position of the ears. Though recurrence is rare, syndromic identification after delivery would help in counselling the families. A detailed clinical and radiological evaluation supplemented by pathological examination should be considered.

Table 2 Comparison of studies between Kajiwara et al., Rodriguez et al. and the present study

Variable	Kajiwara et al	Rodriguez et al	Our study
Type of study	Multiple case reports	3 case reports + 1 case series (3 centres)	Single centre
Year of study	1977–2016	2006–2016	2000–2018
No of cases	22	7	26
Mean GA at diagnosis	26 weeks	12 weeks 4 days	23 weeks
First trimester diagnosis	1	7	4
Polyhydramnios	59%	Not Available	46%
Isolated	64%	43% (3)	42%
Associations	36%	57% (4)	58%
Skeletal	14%	50%	47%
CNS	18%	100% (4)	27%
Renal	5%	0%	13%
Situs Inversus Totalis	0%	0%	6.7%
CDH	5%	0%	6.7%
Cardiac	5%	25%	6.7%
Termination of Pregnancy	41	86%	87
Neonatal death	50%	14%	4.3%

Funding Nil

Compliance with Ethical Standard

Conflicts of interest The authors declared that they have no conflict of interest

References

1. Ibba RM, Zoppi MA, Floris M, Putzolu M, Monni G, Toddo PF, Sardu G. Letter to the editor. Otocephaly: prenatal diagnosis of a new case and etiopathogenetic considerations. *Am J Med Genet.* 2000;90:427–9.
2. Kerkring T. Spicilegium Anatomicum. *Obs.* 1917;60:122–3.
3. Faye-Petersen O, David E, Rangwala N, Seaman JP, Hua Z, Heller DS. Otocephaly: report of five new cases and a literature review. *Fetal and Pediatric Pathology.* 2006;25(5):277–96.
4. Pauli RM, Graham JM Jr, Barr M Jr. Agnathia, situs inversus, and associated malformations. *Teratology.* 1981;23:85–93.
5. Opitz JM. The developmental field concept in clinical genetics. *J Pediatr.* 1982;101:805–9.
6. Opitz JM, Zanni G, Reynolds JF, Gilbert-Barness E. Defects in blastogenesis. *Am J Med Genet.* 2002;115:269–86.
7. Le Douarin NM, Brito JM, Cruzet S. Role of the neural crest in face and brain development. *Brain Res Rev.* 2007;55:23e7247.
8. Wei Jun, Ran Suzhen, Yang Zhengchun, Lin Yun. Prenatal ultrasound screening for external ear abnormality in the fetuses. *Bio Med Res Int.* 2014;6:357564. <https://doi.org/10.1155/2014/357564>.

9. Donnelly M, Todd E, Wheeler M, Winn VD, Kamnasaran D. Prenatal diagnosis and identification of heterozygous frameshift mutation in PRRX1 in an infant with agnathiaotocephaly. *Prenat Diagn.* 2012;32(9):903–5.
10. Krassikoff N, Sekhon GS. Familial agnathia- holoprosencephaly caused by an inherited unbalanced translocation and not autosomal recessive inheritance. *Am J Med Genet.* 1989;34:255–7.
11. Gekas BL, Kamnasaran D. Current perspectives on the etiology of agnathia-otocephaly. *Eur J Med Genet.* 2010;53(6):358–66.
12. Pauli RM, Pettersen JC, Arya S, Gilbert EF. Familial agnathia-holoprosencephaly. *Am J Med Genet.* 1983;14:677–98.
13. Zhu H, Kartiko S, Finnell RH. Importance of gene-environment interactions in the etiology of selected birth defects. *Clin Genet.* 2009;75:409–23.
14. Buhimschi CS, Weiner CP. Medications in pregnancy and lactation: Part 1. Teratology. *Obstet Gynecol.* 2009;113:166–88.
15. Warkany J, Takacs E. Congenital malformations in rats from streptonigrin. *Arch Pathol.* 1965;79:65–79.
16. Zawoiski EJ. Prevention of trypan blue-induced exencephaly and otocephaly in gestating albino mice. *Toxicol Appl Pharmacol.* 1975;31:191–200.
17. Merlob P, Stahl B, Klinger G. Tetrad of the possible mycophenolate mofetil embryopathy: a review. *Reprod Toxicol.* 2009;28:105–8.
18. Leech RW, Bowlby LS, Brumback RA, Schaffer GB. Agnathia, holoprosencephaly, and situs inversus: report of a case. *Am J Med Genet.* 1988;29:483–90.
19. Gorlin RJ, Cohen MM Jr, Hennekam RCM. *Syndromes of the head and neck.* 4th ed. Oxford: Oxford University Press; 2001.
20. Kazuhiro Kajiwara, Tomohiro Tanemoto, Chie Nagata and Aikou Okamoto, prenatal diagnosis of isolated agnathia-otocephaly: a case report and review of the literature, Vol. 2016, Hindawi Publishing Corporation, Case reports in obstetrics and gynecology
21. Rodriguez N, Casasbuenas A, Andreeva E, Odegova N, Wong AE, Sepulveda W. First trimester diagnosis of agnathia otocephaly complex- a series of 4 cases and review of the literature. *J Ultrasound Med.* 2018;38:1–5.
22. Sepulveda W, Wong AE. First trimester screening for holoprosencephaly with choroid plexus morphology (“butterfly” sign) and biparietal diameter. *Prenat Diagn.* 2013;33:1233–7.
23. Blaas HG, Eriksson AG, Salvesen KA, et al. Brains and faces in holoprosencephaly: pre- and postnatal description of 30 cases. *Ultrasound Obstet Gynecol.* 2002;19:24.

Publisher’s Note Springer Nature remains neutral with regard to jurisdictional claims in published maps and institutional affiliations.