



# Interstitial Laser Occlusion of the Systemic Feeding Vessel in a Hybrid Lung Lesion: Technique, Clinical Course, Perinatal Outcome and a Review of Literature

Vidhika Berwal<sup>1</sup> · Sarala Sreedhar<sup>2</sup> · Mohan Abraham<sup>3</sup> · Vivek Krishnan<sup>1</sup>

Received: 12 May 2020 / Accepted: 28 November 2020 / Published online: 3 January 2021  
© Society of Fetal Medicine 2021

**Abstract** The two most common fetal lung lesions include Bronchopulmonary sequestration (BPS) and Congenital pulmonary airway malformation (CPAM). Their co-existence is known as a hybrid lesion. Fetal hydrops in such cases is associated with very high morbidity and mortality. Several fetal interventions have been recommended over the past years to treat the same, with varying success rates. We describe a case of a hybrid CPAM complicated by hydrops which was successfully treated by interstitial laser coagulation of the systemic feeder artery. We also review current literature on the available interventions and conclude that interstitial laser has emerged as the preferred modality of treatment over the years.

**Keywords** Hybrid lesion · CPAM · Bronchopulmonary sequestration · Prenatal intervention · Interstitial laser · Fetal surgery

## Introduction

The most common hyperechoic fetal lung lesions are bronchopulmonary sequestration (BPS) and congenital pulmonary airway malformation (CPAM).

Bronchopulmonary sequestration is a rare developmental anomaly in which a non-functional mass of bronchopulmonary tissue is fed by a systemic vessel. The descending aorta typically, or occasionally splenic, celiac or costal artery, may provide the blood supply to this mass.

CPAM, on the other hand, is a developmental anomaly of the lower respiratory tract. Abnormal airway branching during lung development results in lung cysts.

Rarely these two entities may co-exist as a hybrid lesion.

In cases of microcystic CPAM, regression is seen in over 80% cases during the third trimester. This is not always a true resolution because postnatal CT scans show a residual mass after birth in many cases.

Likewise, BPS has an unpredictable antenatal course. More than 30% of BPS cases are known to regress antenatally towards the third trimester. Some remain static, whilst a few, particularly the large ones, progress to pleural effusion/fetal hydrops secondary to mediastinal compression and occlusion of venous return to the heart [1]. Serial ultrasound monitoring of such cases is warranted. For the lesions that do show signs of progression to hydrops, various prenatal treatment options have evolved over the years including interstitial laser, alcohol injection, pleuroamniotic shunts and amnio-reduction under multiple-dose steroid cover [2–5].

We report a case of hybrid CPAM causing fetal hydrops that was successfully treated in utero with interstitial laser coagulation.

## Case Report

A 29 year old third gravida was referred to our centre at 21 weeks gestation for a second opinion on a thoracic mass. Fetal US done with us revealed a multicystic

✉ Vivek Krishnan  
drvivekkrishnan@gmail.com

<sup>1</sup> Division of Fetal Medicine and Perinatology, Amrita Centre of Excellence in Fetal Care, AMRITA Institute of Medical Sciences, AIMS Ponekkara PO, Kochi, Kerala 682 041, India

<sup>2</sup> Obstetrics and Gynaecology, AMRITA Institute of Medical Sciences, Kochi, India

<sup>3</sup> Paediatric and Fetal Surgery, AMRITA Institute of Medical Sciences, Kochi, India

echogenic mass measuring 4.9 cm × 4.4 × 3.7 cm in the right hemi thorax, displacing the heart to the left (Fig. 1). Colour Doppler interrogation revealed a systemic feeding artery originating from the descending aorta (Fig. 2). The CPAM volume ratio [6] (CVR) calculated was 2.1. No other structural abnormalities were noted. However, there was significant fetal hydrops. Based on these findings, a diagnosis of BPS with CPAM type II (Hybrid lesion) was made.

The risks to the fetus and the mother were explained in detail to the family and the various management options including fetal intervention and the choices therein were discussed. The family opted for interstitial laser ablation of the feeder artery, understanding the benefits and risks of the procedure and the need for possible definitive surgery postnatally. A pre-procedure genetic testing was offered and accepted, which returned a normal QFPCR for aneuploidy and later, a normal karyotype in the fetus.

## Procedure

Interstitial photocoagulation of the feeder artery was performed at 21 weeks +5 days. Fetal paralysis was achieved with Pancuronium (0.2 ml of 1 mg/ml) intramuscularly into the fetal thigh using a 22 gauge needle. An 18 gauge needle was then introduced into the fetal thorax directed towards the fetal lung mass, close to the feeding artery and perpendicular to it, in such a manner that the heart or any other vessel (particularly the descending aorta and right pulmonary artery) would not come in the “line of fire”. A safe radius of at least 2–3 cms was maintained between the target vessel and the surrounding vasculature and heart.

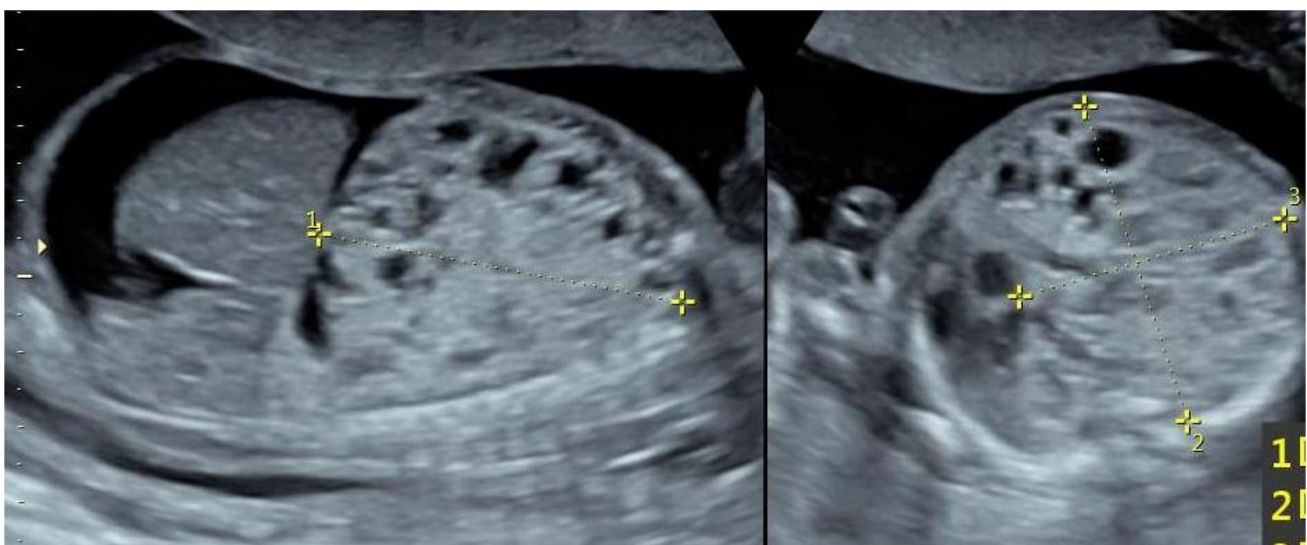
This orientation of the needle was best achieved with the transverse section of the thorax in view (Figure 3a, b). A 300 nm laser (Neodymium-doped Yttrium Aluminium Garnet) fibre was then introduced through this needle and the artery was ablated using standard ablation, continuous firing mode, with the power set to 30 watts. Complete cessation of flow in the feeder artery was achieved with two cycles of 5–10 s each. Pulmonary artery flow was undisturbed (Fig. 3c). The fetal heart activity was documented following the procedure. A follow up scan after 24 h confirmed the absence of flow in the feeder vessel.

## Clinical Course

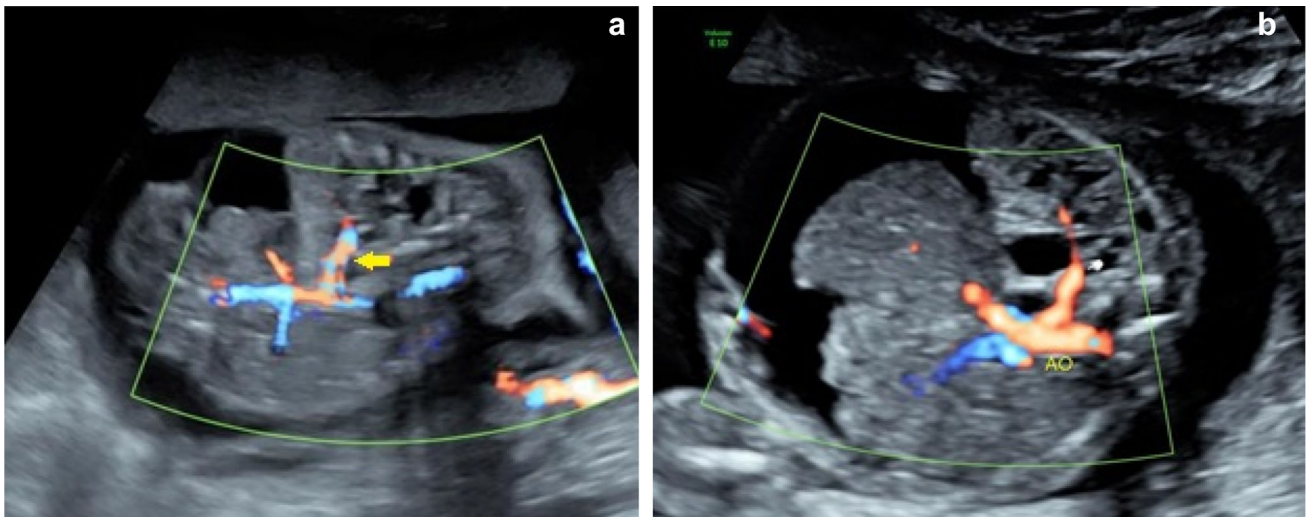
In the subsequent weeks there was a progressive decrease in the size of the lesion and the CVR. Fetal hydrops disappeared in 2 weeks (Fig. 4). The rest of the pregnancy was uneventful.

## Perinatal Outcome and Follow Up

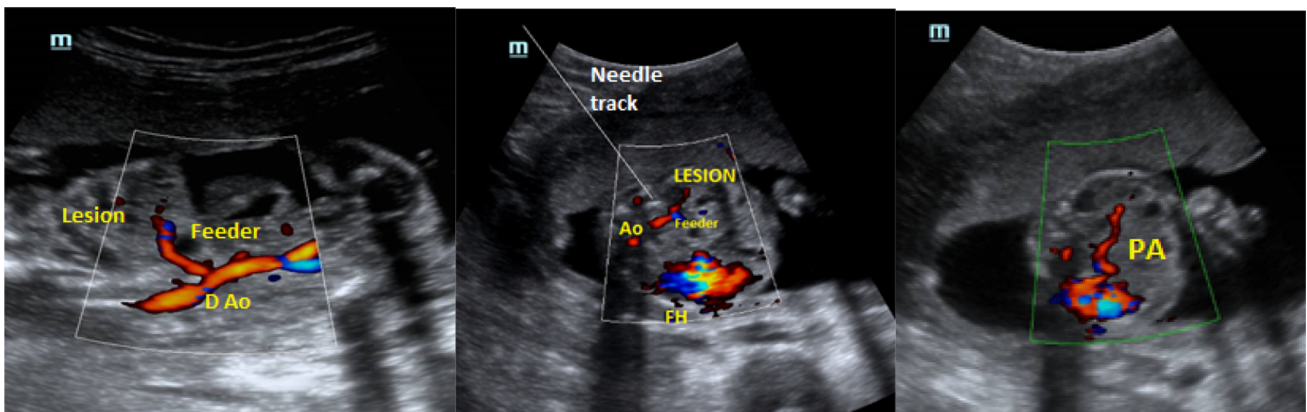
A healthy male baby weighing 3.6 kg was delivered at 39 weeks 4 days of gestation vaginally. APGAR score was 8 at 1 min and 9 at 5 min of birth. The neonate had mild respiratory distress and was admitted to the neonatal intensive care unit for observation. During his stay in the NICU, he had a few episodes of intermittent tachypnea but did not require any kind of oxygen support. A chest X-ray taken on day 7 showed a heterogeneous opacity in the lower zone of the right lung with few cystic lucencies along its inferior margin which were likely to be a residual lesion.



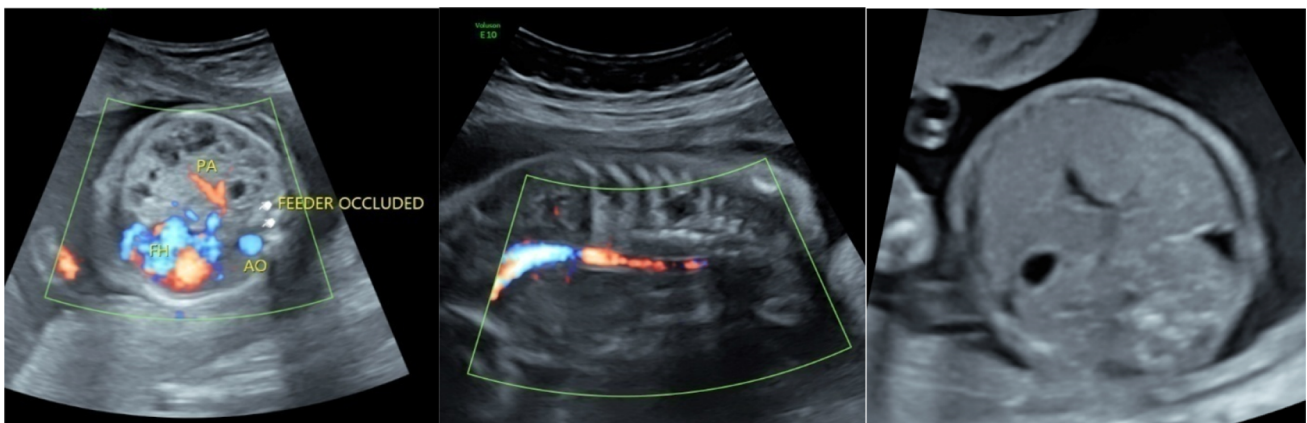
**Fig. 1** Large hyperechoic multicystic mass occupying right hemi-thorax causing mediastinal shift to the left, fetal ascites and pleural effusion, indicating hydrops fetalis



**Fig. 2** Systemic arterial supply to the lesion seen in coronal (a) and axial (b) sections



**Fig. 3** Coronal section of the fetal trunk showing the feeder artery arising from the descending aorta (a). Axial section through the fetal thorax after the first laser burst with needle insitu showing the needle track, partly occluded feeder artery and the displaced fetal heart (b). A more cephalad axial section post procedure showing intact right pulmonary artery



**Fig. 4** No systemic blood flow to the lesion documented in axial or coronal section and resolving fetal hydrops on follow up scan one week post procedure



CT scan of the thorax on day 10 also showed a residual multicystic lesion in right lower lobe with solid soft tissue density measuring 1.7 X 0.9 cm (Fig. 5).

Nevertheless, since the neonate was largely asymptomatic, the pediatric surgery team and the family jointly decided on a conservative approach followed by reassessment at 3 months of age rather than an emergency sequestrectomy. At 3 months, a repeat CT with angiogram was performed and a decision to operate was taken, in view of a persistent residual lesion. Lobectomy was subsequently performed thoracoscopically. The baby was discharged after an uneventful post-op period.

## Discussion

Bronchopulmonary sequestration (BPS) is a rare fetal anomaly, seen in 0.8 to 1.4% of all pulmonary resections. A subset of these has features of CPAM and are termed hybrid lesions. Literature on antenatal management of hybrid lesions per se is scant. A thorough search did not reveal any published literature on the same. Most reports and case series on antenatal management have grouped these lesions to include CPAM, BPS and hybrid lesions. In our review, we look at antenatal interventions in cases of BPS and hybrid lesions only, since the scope of an interstitial laser photocoagulation is non-existent in cases of isolated CPAM where the vascular supply is only from the pulmonary artery.

When present, large lesions causing significant mediastinal shift, a CPAM volume ratio > 1.6 and the presence of hydrops, are some of the poor prognostic indicators. The mediastinal compression that a large lesion may cause and the related impairment of venous return is the primary reason for development of hydrops in BPS [1]. In the absence of severe pleural effusion or hydrops, BPS has a

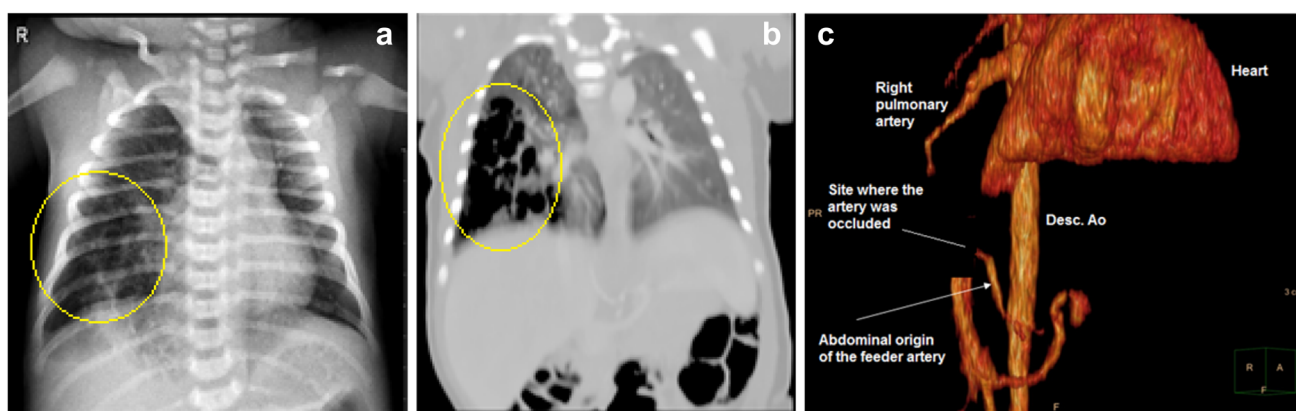favourable prognosis with a high probability of spontaneous regression or excellent surgical outcomes in lesions that persist into postnatal life [7]. Such cases may be managed expectantly during the antenatal period. On the other hand, lesions that result in fetal hydrops are associated with a high incidence of intrauterine demise or neonatal morbidity/mortality and are therefore a definitive indication for fetal therapy [8]. Several fetal therapeutic interventions have been proposed over the years to treat such lesions, some of which have been tabulated below (Table 1) [2, 3, 7–20].

Pleuro (thoraco) amniotic shunts were among the first advocated lines of antenatal treatment. However, this procedure aimed at volume reduction rather than treating the lesion itself. Moreover, shunt displacement was common necessitating re-interventions. The risks of preterm delivery were high. 9/11 (81.8%) cases reported so far needed postnatal sequestrectomy.

Direct alcohol injection leads to sclerosis of the feeder vessel along with resolution of hydrops. However, 2 of the 4 reported cases (50%) required postnatal surgery. Moreover, with only 4 cases reported, the data is too small to draw significant conclusions.

Steroid administration in a case of BPS complicated by hydrops is relatively new. The major advantage with betamethasone treatment is that it is non-invasive. However most fetuses are likely to require post-natal surgery because of a high chance of reappearance of hydrops [16]. Also, there could be long term implications due to multiple dose administration of steroids [21]. Therefore it is not recommended as a first choice of treatment.

Interstitial hyperthermia induced by means of lasers by inserting the light conducting quartz fibre into the tumour was first described in 1983 and is the principle being used currently in the modern day technique of interstitial laser photocoagulation [22]. 33 cases, including ours, and 5



**Fig. 5** Post-natal chest X-ray on Day 7 (a) and contrast CT on Day 10 (b) with multicystic lesions scattered in the right lower lobe, suggesting a residual lesion. Pre-op CT angiogram (c) at 3 months

showing the origin of the feeder artery from the abdominal aorta. The abrupt ending of the feeder at the site of laser occlusion is also marked

**Table 1** Literature review of prenatal interventions for broncho-pulmonary sequestration

Intervention	Authors	Sample size	Pleural effusion/hydrops	GA at procedure	GA at delivery	Outcome	Post natal surgery
Interstitial laser	Ryan et al. [7]	1	Hydrops+	19	39	Live and healthy	Lobectomy
Interstitial laser	Oepkes et al. [2]	1	Hydrops+	23	39	Live and healthy	Declined
Interstitial laser	Mallman [12]	5	Hydrops +	30 + 4	39 + 1	Live and healthy	1/5 needed lobectomy
Interstitial laser	Ruano et al. [8]	1	Pleural effusion+	29	38	Pulmonary HTN	Lobectomy
Interstitial laser	Witlox et al. [9]	1	Hydrops +	23	41	Live and healthy	None
Interstitial laser	Rammos et al. [10]	2	Hydrops+	30–33	Term	Live and healthy	Lobectomy in both
Interstitial laser	Ruano et al. [11]	3	Hydrops+	24–29	30–39	2/3 live and healthy	None
Interstitial laser	Coleman [13]	1	Hydrops +	26	27 + 3 (Abruptio)	Died on PND 23	None
Interstitial laser	Martinez et al. [14]	5	Hydrops/pleural effusion+	25	39 + 6	Live and healthy	2/5 needed lobectomy
HYBRID LESIONS							
Interstitial laser	Gottschalk et al. [15]	12	None	29 + 3	39 + 1	Live and healthy	2/12 needed lobectomy
Interstitial laser	Vidhika et al.	1 (Hybrid lesion)	Hydrops/pleural effusion+	21 + 5	39 + 2	Live and healthy	Lobectomy
Multiple doses of steroids with amnioreduction	Pock et al. [3]	1	Hydrops+	28	30	Pulmonary haemorrhage and pulmonary HTN	None could be offered
Multiple doses of steroids with amnioreduction	Guenot et al. [16]	1	Pleural effusion+	22	35 + 5	Pleural effusion on day 1	Sequestrectomy
Thoracoamniotic shunt	Salomon et al. [17]	1	Hydrops+	34	36	Live and healthy	None
Thoracoamniotic shunt	Hayashi et al. [18]	1	Hydrops +	30	35	Live and healthy	Sequestrectomy
Thoracoamniotic shunt	Hayashi et al. [18]	1	Hydrops+	28	33	Live and Healthy	Sequestrectomy
Thoracoamniotic shunt	Mallman et al. [12]	7	Pleural effusion+	29 + 3	37 + 2	Live and healthy	6/7 segmental resection
Thoracoamniotic shunt	Nicolini et al. [19]	1	Hydrops+	27	40	Live and healthy	None
Sclerotherapy (alcohol injection)	Nicolini et al. [19]	1	Hydrops+	27	40	Live and healthy	None
Sclerotherapy (alcohol injection)	Bermudez et al. [5]	1	Hydrops+	26	38	Live and healthy	Sequestrectomy
Sclerotherapy (alcohol injection)	Bermudez et al. [5]	1	Hydrops–	26	38	Live and healthy	None
Sclerotherapy (alcohol injection)	Bermudez et al. [5]	1	Hydrops+	24	38	Live and healthy	Sequestrectomy

other cases of hybrid lesions have been reported so far of which only 10 (30%) needed postnatal surgery. 30/33 babies (90.9%) had a favourable postnatal outcome. Except

for the one fetus that died at 27 weeks following preterm delivery due to abruptio placenta (Coleman et al.), and one in the series of 3 cases by Ruano et al. that went into

**Table 2** Key elements of various interventions for fetal BPS

Procedure	Attempts	Maternal morbidity	Fetal complications	Expertise	Need for postnatal surgery	Remarks
Interstitial laser	+	+	+	++++	±	Requires high skill, less maternal and fetal complications
Pleuro amniotic shunt	+	+++	++	++	++	Associated with high chances of maternal bleeding, PPRM as compared to laser
Multiple doses of steroid with amnioreduction	++	–	+++	–	+++	Associated with high rates of neonatal complications and requirement of postnatal surgeries
Alcohol injection	–	–	±	+	++	Relatively simple procedure, significant number of neonates required postnatal surgeries

preterm labour at 30 weeks and died subsequently, all the other 31 out of 33 cases (93.9%) had a term delivery.

Out of 5 hybrid cases reported (Martinez et al.), all were prenatally treated with interstitial laser and born alive at term. 2/5 (40%) required postnatal surgery. However, Cass et al. were the first to publish a case series regarding hybrid lesions which included 6 cases of which only one fetus was treated antenatally with fetal thoracotomy at 22 weeks of gestation and a healthy baby was delivered at 35 weeks of gestation. Fetal thoracotomy is not considered an acceptable in utero treatment option due to its associated complications [23], and therefore was not included in our review.

The use of interstitial laser could be associated with complications like injury to adjacent vital structures, experiments on porcine liver showed single ND YAG fibre set on high power (100 W) caused only 2–3 cm damage around the fibre [22]. Such high powers are not being used in current procedures. Moreover, planned entry and precision during the procedure, making sure to maintain a safe radius of 2–3 cms from surrounding structures, will minimise the risk of such complications. Aplasia cutis congenita is another major complication reported with the use of lasers but only few cases have been reported in literature. Also, in a poorly selected case, revascularisation is a possibility, particularly with a large feeder vessel, a multiple branching vessel or an incomplete procedure. Of the 33 cases treated with interstitial laser, 10 required re-interventions, although it was not required in our case.

Therefore, the relatively newer technique of interstitial laser, in comparison to the rest, holds more promise with more curative intent, lesser requirement of postnatal surgery, very low risk of pre-term births and fewer complications thereby making it a more acceptable first choice in expert hands.

The choice of procedure in an individual case would depend on the accessibility and size of lesion and the

expertise of the surgeon [2–5, 9–18]. Few key elements of each have been tabulated below that may help the clinician in decision making (Table 2).

Our case demonstrates the safe use of interstitial laser in a hydropic fetus with Hybrid CPAM and the feasibility of the same in our setting, with this being the first and only reported case in India to the best of our knowledge. The pregnancy could safely be pulled on till term. The neonate was asymptomatic at birth and did not require any immediate postnatal surgery. However, in view of a residual lesion, a lobectomy was later performed at 3 months with excellent post-surgical outcomes.

## Conclusion

We conclude that interstitial laser in a case of hybrid CPAM with fetal hydrops/pleural effusion is a feasible and safe option. When employed in a well selected patient, the procedure is usually not associated with any significant fetal or maternal complication. In cases where thoracic anatomy is suitable, interstitial laser photocoagulation must be considered as the first line antenatal management for hybrid CPAM/bronchopulmonary sequestration.

## References

1. Biyyam DR, Chapman T, Ferguson MR, Deutsch G, Dighe MK. Congenital lung abnormalities: embryologic features, prenatal diagnosis, and postnatal radiologic-pathologic correlation. *Radiographics*. 2010;30(6):1721–38.
2. Oepkes D, Devlieger R, Lopriore E, Klumper FJ. Successful ultrasound-guided laser treatment of fetal hydrops caused by pulmonary sequestration. *Ultrasound Obstet Gynecol*. 2007;29(4):457–9.
3. Pock R, Straňák Z, Vojtěch J, Hašík L, Feyereisl J, Krofta L. Bronchopulmonary Sequestration with Fetal Hydrops in a

- Monochorionic Twin Successfully Treated with Multiple Courses of Betamethasone. *AJP reports*. 2018;8(4):e359.
4. Crombleholme TM, Coleman B, Hedrick H, Liechty K, Howell L, Flake AW, Johnson M, Adzick NS. Cystic adenomatoid malformation volume ratio predicts outcome in prenatally diagnosed cystic adenomatoid malformation of the lung. *J Pediatr Surg*. 2002;37(3):331–8.
  5. Lunger B, Donato L, Riethmuller C, Becmeur F, Dreyfus M, Favre R, Schlaeder G. Spontaneous regression of fetal pulmonary sequestration. *Ultrasound Obstet Gynecol*. 1995;6(1):33–9.
  6. Knox EM, Kilby MD, Martin WL, Khan KS. In-utero pulmonary drainage in the management of primary hydrothorax and congenital cystic lung lesion: a systematic review. *Ultrasound Obstet Gynecol*. 2006;28(5):726–34.
  7. Ryan G, Oepkes D, Langer J, Alkazaleh F, Asch M, Klumper F, Seaward G, Windrim R, Shah P. Ultrasound-guided laser treatment of hydropic fetal lung lesions with a systemic arterial supply. *Am J Obstet Gynecol*. 2003;189(6):S230.
  8. Ruano R, de Pimenta EJA, Da Silva MM, Maksoud JG, Zugaib M. Percutaneous intrauterine laser ablation of the abnormal vessel in pulmonary sequestration with hydrops at 29 weeks' gestation. *J Ultrasound Med*. 2007;26(9):1235–41.
  9. Witlox RS, Lopriore E, Walther FJ, Rijkers-Mutsaerts ER, Klumper FJ, Oepkes D. Single-needle laser treatment with drainage of hydrothorax in fetal bronchopulmonary sequestration with hydrops. *Ultrasound Obstet Gynecol*. 2009;34(3):355–7.
  10. Rammos KS, Foroulis CN, Rammos CK, Andreou A. Prenatal interventional and postnatal surgical therapy of extralobar pulmonary sequestration. *Interact CardioVasc Thorac Surg*. 2010;10(4):634–5.
  11. Ruano R, da Silva MM, Salustiano EM, Kilby MD, Tannuri U, Zugaib M. Percutaneous laser ablation under ultrasound guidance for fetal hyperechogenic microcystic lung lesions with hydrops: a single-center cohort and a literature review. *Prenatal diagnosis*. 2012;32(12):1127–32.
  12. Mallmann MR, Geipel A, Bludau M, Matil K, Gottschalk I, Hoopmann M, Müller A, Bachour H, Heydweiller A, Gembruch U, Berg C. Bronchopulmonary sequestration with massive pleural effusion: pleuroamniotic shunting vs intrafetal vascular laser ablation. *Ultrasound Obstet Gynecol*. 2014;44(4):441–6.
  13. Coleman AM, Merrow AC, Crombleholme TM, Jaekle R, Lim FY. Fetal MRI of torsed bronchopulmonary sequestration with tension hydrothorax and hydrops in a twin gestation. *Fetal Diagn Ther*. 2016;40(2):156–60.
  14. Cruz-Martinez R, Martínez-Rodríguez M, Bermúdez-Rojas M, Magaña-Abarca C, Narvaez-Dominguez V, Rojas-Macedo A, Bautista-García N, Alcocer-Alcocer M. Fetal laser ablation of feeding artery of cystic lung lesions with systemic arterial blood supply. *Ultrasound Obstet Gynecol*. 2017;49(6):744–50.
  15. Gottschalk I, Strizek B, Mallmann MR, Müller A, Geipel A, Gembruch U, Klaritsch P, Csapo B, Berg C. Outcome of bronchopulmonary sequestration with massive pleural effusion after intrafetal vascular laser ablation. *Fetal Diagn Ther*. 2018;44(2):149–55.
  16. Guenot C, Dubrit K, Lepigeon K, Giannoni E, Baud D, Vial Y. Effect of maternal betamethasone on hydrops fetalis caused by extralobar pulmonary sequestration: a case report. *J Obstet Gynaecol*. 2019;39(1):120–2.
  17. Salomon LJ, Audibert F, Dommergues M, Vial M, Frydman R. Fetal thoracoamniotic shunting as the only treatment for pulmonary sequestration with hydrops: favorable long-term outcome without postnatal surgery. *Ultrasound Obstet Gynecol*. 2003;21(3):299–301.
  18. Hayashi S, Sago H, Kitano Y, Kuroda T, Honna T, Nakamura T, Ito Y, Kitagawa M, Natori M. Fetal pleuroamniotic shunting for bronchopulmonary sequestration with hydrops. *Ultrasound Obstet Gynecol*. 2006;28(7):963–7.
  19. Nicolini U, Cerri V, Groli C, Poblete A, Mauro F. A new approach to prenatal treatment of extralobar pulmonary sequestration. *Prenat Diagn*. 2000;20(9):758–60.
  20. Bermudez C, Perez-Wulff J, Bufalino G, Sosa C, Gomez L, Quintero RA. Percutaneous ultrasound-guided sclerotherapy for complicated fetal intralobar bronchopulmonary sequestration. *Ultrasound Obstet Gynecol*. 2007;29(5):586–9.
  21. Carson R, Monaghan-Nichols AP, DeFranco DB, Rudine AC. Effects of antenatal glucocorticoids on the developing brain. *Steroids*. 2016;1(114):25–32.
  22. Steger AC, Shorvon P, Walmsley K, Chisholm R, Bown SG, Lees WR. Ultrasound features of low power interstitial laser hyperthermia. *Clin Radiol*. 1992;46(2):88–93.
  23. Cass DL, Crombleholme TM, Howell LJ, Stafford PW, Ruchelli ED, Adzick NS. Cystic lung lesions with systemic arterial blood supply: a hybrid of congenital cystic adenomatoid malformation and bronchopulmonary sequestration. *Journal of pediatric surgery*. 1997 Jul 1;32(7):986–90.

**Publisher's Note** Springer Nature remains neutral with regard to jurisdictional claims in published maps and institutional affiliations.