



“First Things First”: Images for a Proper Nuchal Translucency in the First Trimester 11–13⁺⁶ Weeks Scan

Chinmayee Ratha · Ashok Khurana

Received: 22 August 2014 / Accepted: 23 September 2014 / Published online: 1 November 2014
 © Society of Fetal Medicine 2014

Abstract This section of articles will concentrate on the technical aspects of imaging in fetal medicine. The “First Things First” series will deal with all aspects of the nuchal translucency (NT) scan, one at a time, in the current and forthcoming issues of the Journal. The present article aims at summarizing the ideal protocol for the measurement of the fetal NT at the 11–13⁺⁶ weeks scan based on the Fetal Medicine Foundation (FMF), UK guidelines and some practical tips for beginners.

Keywords Nuchal translucency scan · First trimester scan · NT scan · NT imaging · Fetal scan

Introduction

The first trimester nuchal translucency (NT) scan is being recognized now as the first important fetal scan in a pregnancy which can establish many facts that help in stratifying risk at various levels regarding both the fetus and mother. This series of articles entitled “First Things First”, will elaborate on each important aspect of the imaging and interpretation of the first trimester, 11–13⁺⁶ weeks scan.

The NT measurement is so important in this scan that this extensive imaging procedure has been allotted the popular nomenclature of an “NT scan”. NT is the sonographic appearance of a collection of fluid under the skin behind the fetal neck in the first-trimester of pregnancy [1].

Protocol for Measuring NT

The protocol for measuring the NT has been given in detail on the Fetal Medicine Foundation website and is accessible for reference to all interested readers. The important points of this protocol are enumerated as follows [2]:

1. The gestational period must be 11–13 weeks and six days.
2. The fetal crown-rump length (CRL) should be between 45 and 84 mm.
3. The magnification of the image should be such that the fetal head and thorax occupy the whole screen.
4. A mid-sagittal view of the face should be obtained. This is defined by the presence of the echogenic tip of the nose and rectangular shape of the palate anteriorly, the translucent diencephalon in the center and the nuchal membrane posteriorly. Minor deviations from the exact midline plane would cause non-visualization of the tip of the nose and visibility of the zygomatic process of the maxilla.
5. The fetus should be in a neutral position, with the head in line with the spine. When the fetal neck is hyperextended the measurement can be falsely increased and when the neck is flexed, the measurement can be falsely decreased.
6. Care must be taken to distinguish between fetal skin and amnion.
7. The widest part of translucency must always be measured.
8. Measurements should be taken with the inner border of the horizontal line of the callipers placed on the line that defines the NT thickness—the crossbar of the calliper should be such that it is hardly visible as it merges with the white line of the border, not in the nuchal fluid (Fig. 1).

C. Ratha (✉)

Department of Fetal Medicine, Rainbow Hospitals, Road No. 10,
 Banjara Hills, Hyderabad 500034, Telangana, India
 e-mail: chinmayee3@gmail.com

A. Khurana

The Ultrasound Lab, New Delhi, India

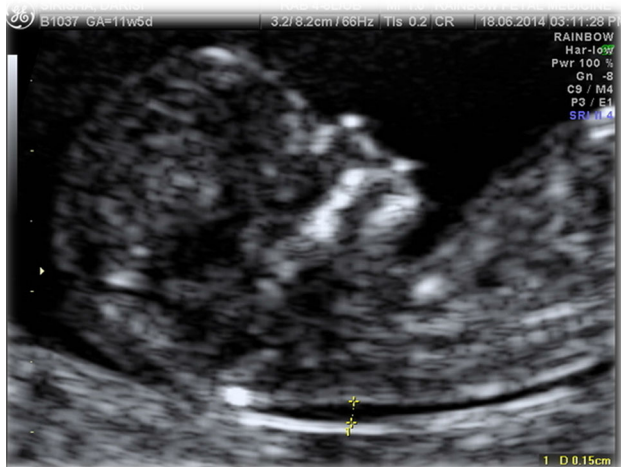


Fig. 1 Nuchal translucency (NT) measurement

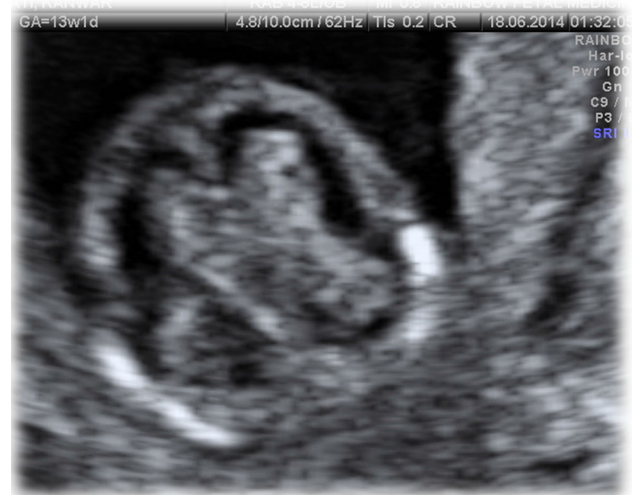

Fig. 3 Axial view of fetal head in first trimester

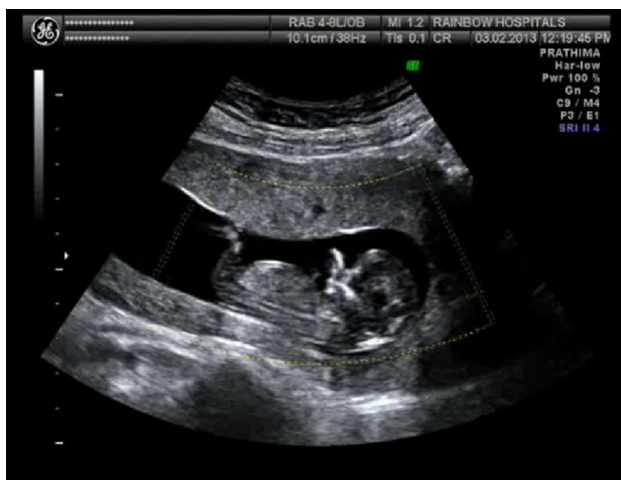

Fig. 2 Use of “box zoom” for optimizing image

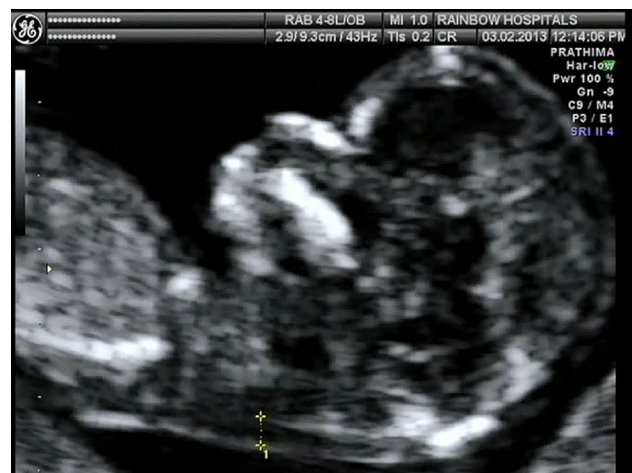

Fig. 4 Standard image for NT measurement

9. In magnifying the image (pre or post freeze zoom) it is important to turn the gain down. This avoids the mistake of placing the calliper on the fuzzy edge of the line which causes an underestimate of the nuchal measurement.
10. During the scan more than one measurement must be taken and the maximum one that meets all the above criteria should be recorded in the database.
11. A new approach for the measurement of NT which improves the accuracy of measurements, is with the use of a semi-automated technique. The operator places a box in the nuchal area and the machine automatically selects the best measurement, which uses an algorithm that draws a line through the center of the nuchal membrane and another line at the edge of the soft tissue overlying the cervical spine. The measurement obtained by this method is similar to

- that obtained manually and it is therefore applicable to the software of the Fetal Medicine Foundation.
12. The umbilical cord may be round the fetal neck in about 5 % of cases and this finding may produce a falsely increased NT. In such cases, the measurements of NT above and below the cord are different and, in the calculation of risk, it is more appropriate to use the average of the two measurements.

Practical Tips for Taking a Good NT Image

The sonographers attempting to take NT measurements at the 11–13⁺⁶ weeks scan should familiarize themselves with the above protocol. The scan can usually be done transabdominally and although a transvaginal approach is becoming increasingly popular to delineate fetal anatomy

better at this gestation, the measurement of NT remains easier transabdominally as the range of probe movement is more. Magnification of the image is of utmost importance and it is useful to use the “box zoom” at the beginning of the scan to get the fetus into the range of the box (Fig. 2). Then the “pan zoom” knob can be used to enhance the area of interest (in this case, fetal head, neck, and upper thorax) so that the final image is satisfactory.

A perfect mid-sagittal section is required and it is rather easy to obtain this if you can obtain an axial view of the head (Fig. 3) such that the midline falxcerebri is perpendicular with the orbits oriented superiorly on the screen.

With the falxcerebri at the center of the probe, if the probe is rotated 90°, a mid-sagittal view of the fetal face can be obtained. Minor adjustments to perfect the image will include reducing the gain to clearly demarcate the

lines in the neck region and eliminate the fuzziness causing confusion about where exactly to place the callipers for measuring the NT (Fig. 4). At this stage, revision of the FMF protocol will help optimize the image to measure a perfect NT.

Conflict of interest None.

References

1. Nicolaides KH, Azar G, Byrne D, et al. Fetal nuchal translucency: ultrasound screening for chromosomal defects in first trimester of pregnancy. *BMJ*. 1992;304(6831):867–9.
2. FMF website <http://fetalmedicine.org/nuchal-translucency-scan>.