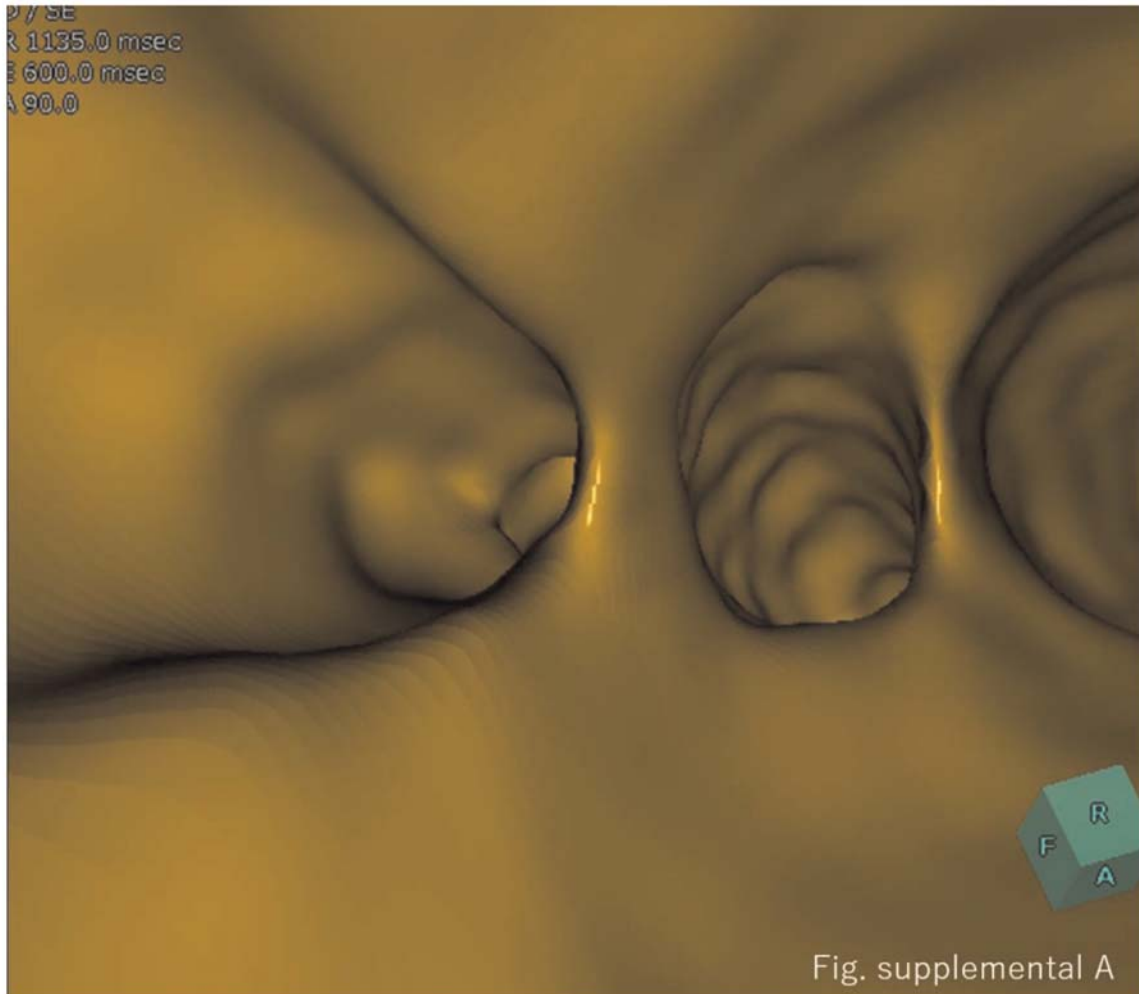


Supplementary material

Supplementary Figure A: MRCS shows a smooth bile duct wall and a sharp corner of the branched bile duct in the hepatic duct (benign).



Supplementary material

Supplementary Figure B: The lumen of the branches of the hepatic bile duct was occluded due to tumor invasion (arrow: malignant).

